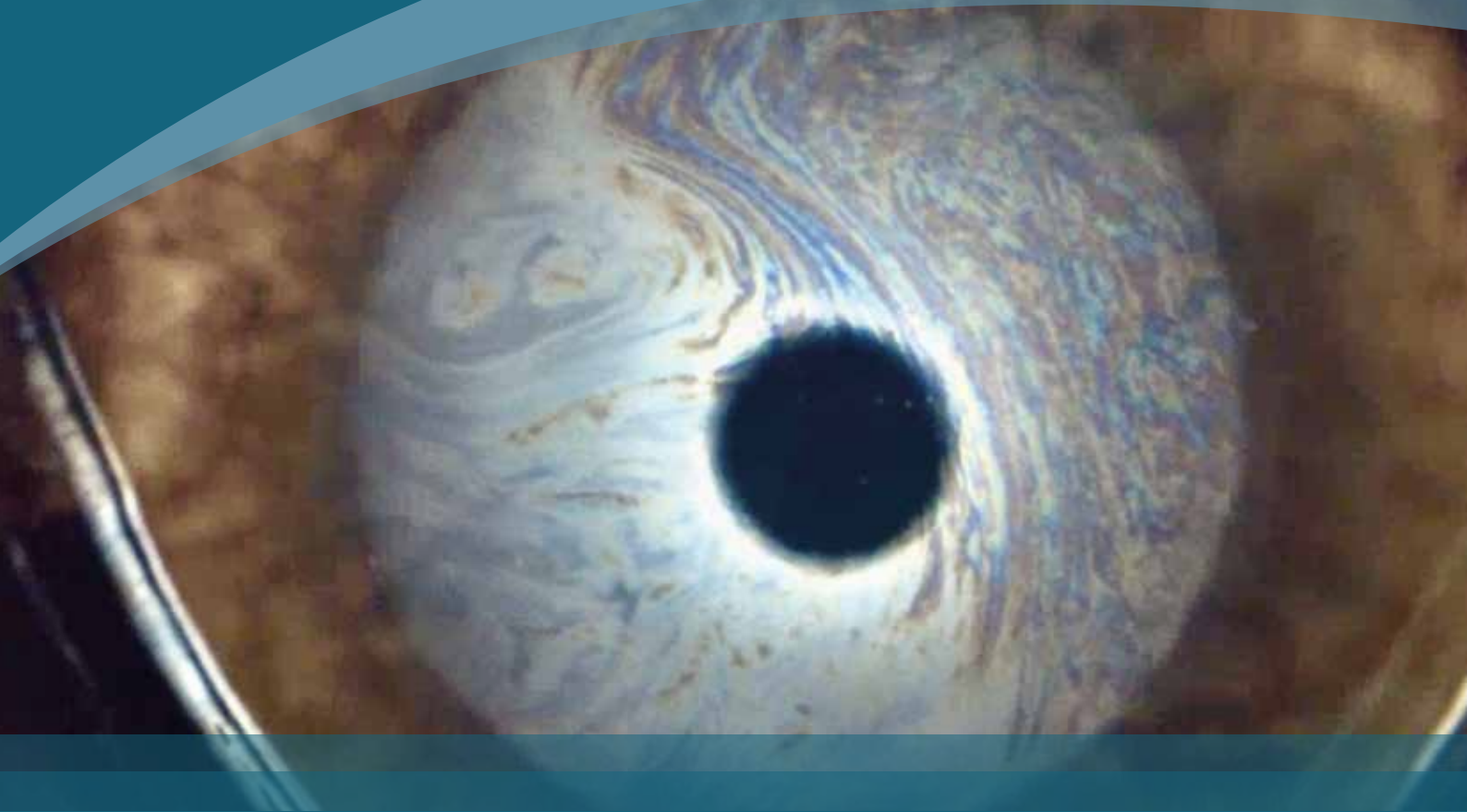


Clinical Atlas

Ocular Surface Analyser, Veterinary Setting,
for the Diagnosis of Dry Eye with O.S.A.-VET



EDITOR

Claudio Peruccio

AUTHORS

AUSTRALIA

Kelly Caruso
Benjamin Reynolds
Jeffrey Smith
Cameron Whittaker

GERMANY

Ingrid Allgoewer

ITALY

Elena Barbasso
Alexia Cattaneo
Francesca Corsi
Nunzio D'Anna
Adolfo Guandalini
Claudio Peruccio
Daniela Terlizzi
Marta Viñas Portillo

JAPAN

Hiroko Iwashita
Akihiko Saito

MEXICO

Gustavo A. García Sánchez
Alina Hernandez

UK

Robert Göllner
Daniele Santillo

USA

Federica Maggio
Stefano Pizzirani

CLINICAL ATLAS

FOREWORD

It is a great pleasure and honor to be asked to write the foreword for this new and innovative Clinical Atlas on the use of the OSA-VET. This Atlas is a noteworthy contribution of Professor Claudio Peruccio to the diagnosis and interpretation of Ocular Surface Disorders (OSDs) in animals of different species.

Several subspecialties have been developing in this last decade and the study of the OSDs has conquered its space between them.

In this Atlas, the Author has done a tremendous job using text and impressive clinical images from many different contributors to provide the practicing Veterinarians with all the tools to study, interpret and diagnose the OSDs. Moreover, the reported clinical cases help the readers to better understand the newest and more scientific approach to the tear film diseases.

In the first part of the Atlas the Tear Film Integrated Functional Unit together with the Meibomian Glands are illustrated from an anatomic and physiologic point of view. Furthermore, the concepts of Dry Eye Disease (DED) and Meibomian Gland Dysfunction (MGD) are described. Then, the numerous types of possible examinations provided from the OSA-VET device are explained in the text: interferometry to examine the Tear Film-Lipid Layer Thickness (LLT) and Dynamics (LLD), evaluation of the Tear Meniscus Height (TMH), interferometry to evaluate the Non Invasive Break Up Time (NIBUT), Placido disc to evaluate the Ocular Surface Topography (OST) and Non-Contact Infrared Meibography (NCIM) to examine the Meibomian Glands.

Afterwards, there is a very stimulant and exhaustive section on the FAQ from OSA-VET users regarding the most common problems encountered during the clinical use of this innovative device.

Finally, there is a unique roundup of 26 highly delineated cases, reported from the clinical history and signs to the final diagnosis in many different species (dogs, cats, horses, rabbits, turtles and a parrot) using the OSA-VET.

In conclusion, I would like to highly suggest to all the Veterinary Ophthalmologists interested in improving their knowledge on the OSDs to use this Atlas as a daily reference during their diagnostic sessions when using the OSA-VET device.

Adolfo Guandalini

DMV, PhD, Diplomate ECVO, DIU Chir. Rétino-Vitréenne

Centro Veterinario Specialistico (CVS), Rome, Italy

PREFACE

When Mr. Michele Barberis, President of SBM Sistemi, asked me to write a book to show the use of interferometry and meibography with the OSA-VET ocular surface analyser, I felt it was time, for the veterinary community, to know more about our experience.

The videos and shots we collected in a four-year period are the best way to prove that these exams may add an important contribution to the diagnosis of ocular surface disorders in animals. Above all this applies to meibomian gland dysfunction, tear film instability, epithelial defects, evaporative and aqueous deficient dry eye.

The COVID-19 pandemic underway is a further incentive to write this book, to react and do all we can to contribute to the progress of Veterinary Ophthalmology.

The first section of the book is an introduction to the ocular surface-tear film integrated functional unit with the most frequent disorders to end-up with the exams available with the use of the OSA-VET analyser. A list of frequently asked questions follows, based on the questions posed by several colleagues and our own experience.

The second section is made of clinical cases involving the dog, the cat, the horse, the rabbit, the turtle and the parrots. Each case includes a few introductory lines of concise presentation followed by some OSA-VET shots to show what can be done with the instrument. The content is intentionally directed to highlight the diagnostic value of meibography and interferometry, purpose of this book. No space is given to treatment and follow-up.

Outstanding colleagues who are using the OSA-VET have been invited to add one case each as a personal contribution. Their interpretation of the diagnostic findings is innovative and noteworthy, and it might open an interesting discussion on a topic frequently approached in a very approximate way.

The ocular surface disorders are as common in humans as in animals. Each clinical case should be examined in a very detailed way, and all tests available should be performed to make an accurate diagnosis. This is the only way to choose the most appropriate treatment.

Claudio Peruccio

Sbm Sistemi Scientific Advisor

EDITOR

Claudio Peruccio, DVM, SCMPA, Dip ECVO, Hon Dip ACVO, MRCVS, EBVS® & RCVS Specialist in Veterinary Ophthalmology, Veterinary Ophthalmology Referrals, Centro Veterinario Torinese (CVT), Torino, Italy

AUTHORS

AUSTRALIA

Kelly Caruso, BSc, VMD, Dip ACVO

Benjamin Reynolds, BVSc, Ophthalmology Resident

Jeffrey Smith, BVSc, FACVSc, Dip ACVO

Cameron Whittaker, BVSc, DVCS, MACVSc, Dip ACVO

Artarmon North Shore Veterinary Specialist Centre, 57-63 Herbert Street, Artarmon NSW 2064

Yagoona, RSPCA Veterinary Hospital, 201 Rookwood Road Yagoona NSW 2199

ITALY

Elena Barbasso, DVM, PhD, Veterinary Ophthalmology Referrals, Centro Veterinario Torinese (CVT), Torino, Italy

Alexia Cattaneo, DVM, Dip CES d'Ophthalmologie Vétérinaire (Toulouse, France), Bergamo, Italy

Francesca Corsi, DMV, ECVO Resident, Dip CES d'Ophthalmologie Vétérinaire, Centro Veterinario Specialistico (CVS), Roma, Italy

Nunzio D'Anna, DVM, PhD, Dip ECVO, Referrals in Veterinary Ophthalmology, Policlinico Veterinario Roma Sud, Roma, Italy

Adolfo Guandalini, DMV, PhD, Dip ECVO, DIU Chir Rétino-Vitréenne, Centro Veterinario Specialistico (CVS), Roma, Italy

Claudio Peruccio, DVM, SCMPA, Dip ECVO, Hon Dip ACVO, MRCVS, EBVS® & RCVS Specialist in Veterinary Ophthalmology, Veterinary Ophthalmology Referrals, Centro Veterinario Torinese (CVT), Torino, Italy

Daniela Terlizzi, DVM, PhD, Veterinary Ophthalmology Referrals, Centro Veterinario Torinese (CVT), Torino, Italy

Marta Viñas Portillo, DVM, Board-eligible resident ECVO, Referrals in Veterinary Ophthalmology, Policlinico Veterinario Roma Sud, Roma, Italy

GERMANY

Ingrid Allgoewer, EBVS® European Specialist in Veterinary Ophthalmology Member of European College of Veterinary Ophthalmologists

JAPAN

Hiroko Iwashita, DVM, Triangle Animal Eye Clinic, Department of Ophthalmology, Toho University Graduate School of Medicine, Tokyo, Japan

Akihiko Saito, BVM, PhD, Dip AiCVO (charter), Dip JCVCO, Triangle Animal Eye Clinic, Tokyo, Japan

MEXICO

Gustavo A. Garcia Sanchez, MVZ, PhD, Dip ACVO, CLOVE, Hospital OFTALVET Avenida Coyoacán 1141, Colonia del Valle Cp. 03100, CDMX, México

Alina Hernandez Valadez, MVZ, EMCPG, Hospital OFTALVET. Avenida Coyoacán 1141, Colonia del Valle Cp. 03100, CDMX, México

UK

Robert Göllner, DVM, PG, CertSAOphthal, MRCVS, Eye Vet Referrals, Cheshire, UK

Daniele Santillo, DVM, CertVOphthal, MRCVS, RCVS Advanced Practitioner in Veterinary Ophthalmology, Eye Vet Referrals, Cheshire, UK

USA

Federica Maggio, DVM, Dip ACVO, Tufts Veterinary Emergency Treatment and Specialties in Walpole Massachusetts, USA

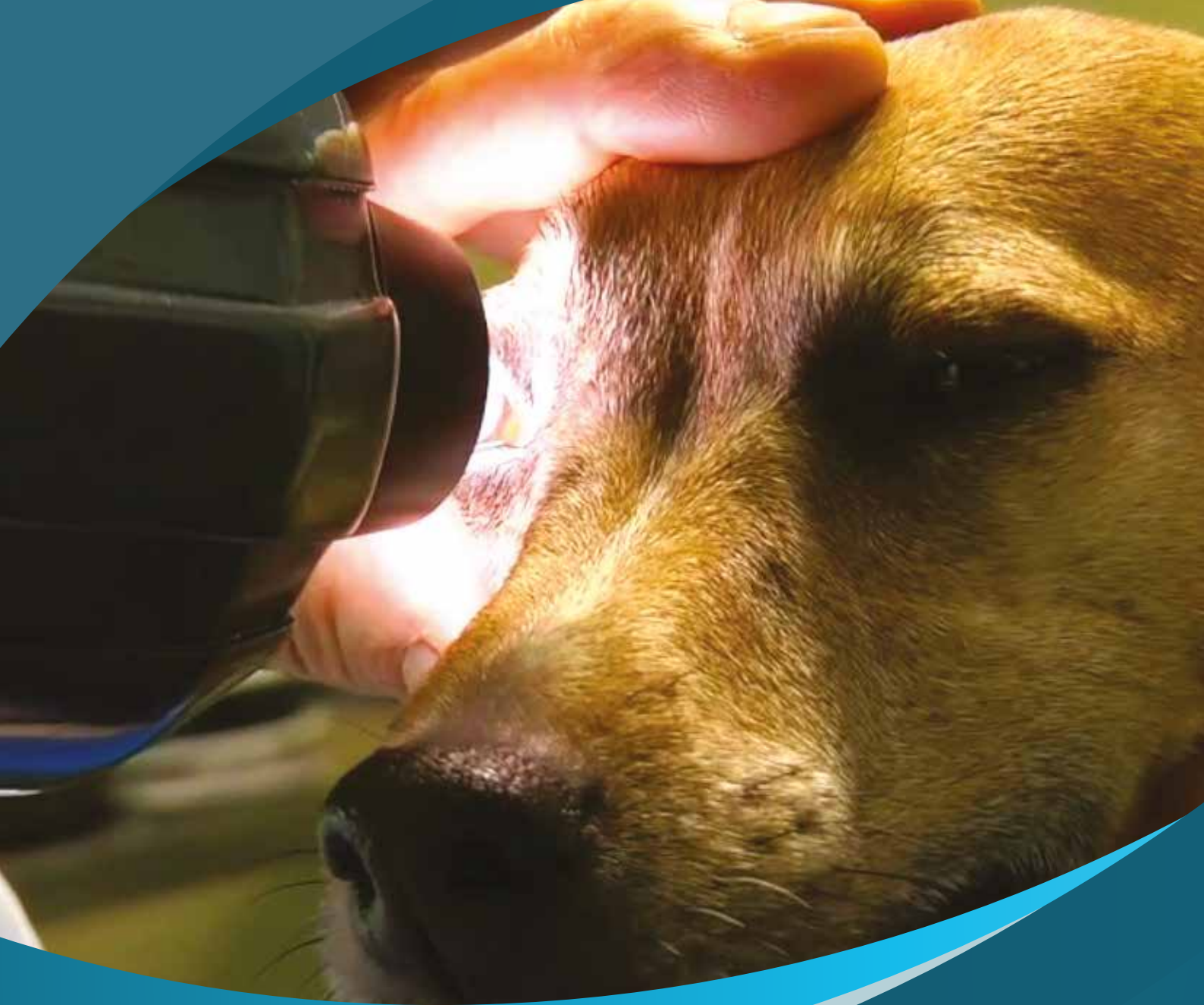Stefano Pizzirani, DVM, Dip ECVS, Dip ACVO, Tufts Cummings School of Veterinary Medicine, North Grafton, Massachusetts, USA

This book is dedicated to all veterinarians with specific interest in Ocular Surface Disorders.

Index

INTRODUCTION	pag. 1
MEIBOGRAPHY AND INTERFEROMETRY IN A VETERINARY CLINICAL SETTING	2
STANDARD PROCEDURE	3
THE OCULAR SURFACE - TEAR FILM INTEGRATED FUNCTIONAL UNIT	4
MEIBOMIAN GLANDS	5
DRY EYE DISEASE	6
MEIBOMIAN GLAND DYSFUNCTION	6
OSA-VET EXAMINATION	7
TEAR MENISCUS HEIGHT	8
OCULAR SURFACE TOPOGRAPHY	8
NON-INVASIVE BREAK-UP TIME	9
NON-CONTACT INFRARED MEIBOGRAPHY	10
TEAR FILM EVAPORATION	11
FREQUENTLY ASKED QUESTIONS FROM OSA-VET USERS (FAQ)	12
ABBREVIATIONS	15
CLINICAL CASES	17
CASE 1 RED, WET EYES (DOG)	18
CASE 2 WET EYES WITH REDNESS AND OPACIFICATION (DOG)	20
CASE 3 OPAQUE RIGHT EYE WITH OU MUCO-PURULENT DISCHARGE (DOG)	24
CASE 4 DRY EYES WITH REDNESS AND OPACIFICATION (DOG)	28
CASE 5 WET EYES WITH SOME CORNEAL OPACIFICATION AND CONTINUOUS BLINKING (DOG)	30
CASE 6 CLOUDY EYES WITH INTERSTITIAL KERATITIS (DOG)	34
CASE 7 MEIBOMIAN GLAND DYSFUNCTION (MGD) (DOG)	36
CASE 8 EVAPORATIVE DRY EYE (DOG)	40
CASE 9 BOTH EYES UNDERWENT CORNEAL AUTOLOGOUS TRANSPLANTATION AND MODIFIED MEDIAL CANTHOPLASTY (DOG)	44
CASE 10 SEVERE EPIPHORA (DOG)	46
CASE 11 MILD CORNEAL HAZINESS AND OCCASIONAL SQUINTING OU (DOG)	50
CASE 12 CHRONIC MUCOUS DISCHARGE (DOG)	54

CASE 13	WET LEFT EYE WITH CLINICAL SIGNS OF DISCOMFORT (CAT)	58
CASE 14	RIGHT EYE WITH CLINICAL SIGNS OF DISCOMFORT (CAT)	62
CASE 15	NORMAL EYES (HORSE)	64
CASE 16	RIGHT EYE WITH FUNGAL KERATITIS / BLEPHAROSPASM AND EPIPHORA (HORSE)	66
CASE 17	RIGHT EYE WITH FUNGAL KERATITIS / BLEPHAROSPASM AND EPIPHORA (HORSE)	68
CASE 18	RIGHT EYE WITH PUNCTATE KERATITIS / BLEPHAROSPASM AND EPIPHORA, SWOLLEN EYELIDS (HORSE)	70
CASE 19	LEFT EYE WITH BULLOUS KERATOPATHY / CLOUDY EYE AND EPIPHORA (HORSE)	72
CASE 20	LEFT EYE WITH SUPERFICIAL IMMK / SLIGHT BLEPHAROSPASM AND EPIPHORA (HORSE)	74
CASE 21	SUPERFICIAL IMMK / BLEPHAROSPASM AND EPIPHORA OU (HORSE)	76
CASE 22	WET EYES, BLEPHARITIS (RABBIT)	78
CASE 23	WET EYES, LOSS OF MEIBOMIAN GLANDS (RABBIT)	82
CASE 24	CONGENITAL ANOMALIES OF THE MEIBOMIAN GLANDS (RABBIT)	86
CASE 25	TF EXAMINATION IN AN EXOTIC SPECIES (TURTLE)	90
CASE 26	CORNEAL DEGENERATION SECONDARY TO PRESUMED CHOLESTEROL DEPOSITS (TURTLE)	92
CASE 27	TF EVALUATION IN A PARROT (PARROT)	94
	OSA-VET MACRO-PHOTOGRAPHY	96
	MGS DUCTAL OPENINGS AND LIPID SECRETION ON THE EYELID MARGIN	96
	LIPIDS ON THE EYELID MARGIN	99
	ECTOPIC CILIA AND MGS CYSTS WITH MULTIPLE HAIRS	100
	DISTICHIASIS	102
	CONJUNCTIVAL/EPISCLERAL VESSELS	103



OSA-VET
Ocular Surface Analyser
for veterinary use
Sbm Sistemi, Torino, Italy

www.sbmsistemi.com

INTRODUCTION

Meibography and interferometry are important exams for a correct diagnosis in all cases of ocular surface disorders (OSDs), they are mandatory for a complete differential diagnosis including evaporative dry eye. Practitioners with specific interest in veterinary ophthalmology and specialists should have access to these exams for their daily clinical work.

In a conventional veterinary ophthalmic clinical setting, all instruments are readily usable. To decrease waste of time also the meibograph-interferometer should always be available connected to the computer, ready to perform examinations.

Meibography and interferometry are also used in research projects, most of all in clinical research to evaluate the effects of OS medical or surgical treatments.

Whenever there is a new instrument, a new exam, the arising problem is: does it add something to my understanding of the clinical case and is it useful in order to choose the best treatment? How will it interfere with the already crowded list of what I have to do in the short time available to perform a complete eye examination?

These are crucial questions and practical problems to be considered first. In our caseload the prevalence of OSDs, secondary to diseases of the lacrimal functional unit (LFU), is increasing day by day. Nowadays OSDs are a common cause of eye examination in companion animals and there is the need for a careful approach to the differential diagnosis. A good reason to dedicate time, study and resources to this topic, to increase the quality of our diagnostic approach and be able to select the best treatment available.

The LFU consists of the ocular surface (cornea and conjunctiva) with sensory nerve endings, the interconnecting afferent innervation to the pons, where also emotional stimuli may have an effect, the efferent innervation to stimulate the lacrimal glands, the meibomian glands (MGs) and the conjunctival goblet cells. All these components must be examined to make a diagnosis!!

At the end of a conventional ophthalmic examination we usually have an idea about tear secretion (Schirmer tear test or phenol red thread test), we have evaluated blinking rate and quality and examined eyelids, cornea and conjunctiva with appropriate instruments and stains as necessary.

With the slit lamp we had the chance to observe some details of the MGs and of the quality of meibum after MGs expression. Hopefully we have also tested the OS sensibility.

But we need to know more about MGs by noncontact infrared meibography, about tear-film lipid-layer thickness and dynamics, tear film distribution and ocular surface wettability by interferometry.

These exams are mandatory to make a correct diagnosis in case of OSDs.

For diagnostic purposes both exams may be done within a few minutes in a cooperative animal. At the end the examiner will be able to diagnose MG dysfunction (MGD) and evaluate lipid layer thickness and dynamics, tear film stability, ocular surface wettability and topography.

For medical records registration all data may be elaborated by the examiner but also by an assistant without further loss of time.

For research or didactic purposes videos and images may be elaborated later on.

Claudio Peruccio

MEIBOGRAPHY AND INTERFEROMETRY IN A VETERINARY CLINICAL SETTING

Ocular Surface Disorders (OSDs) are a common cause of eye examination in companion animals.

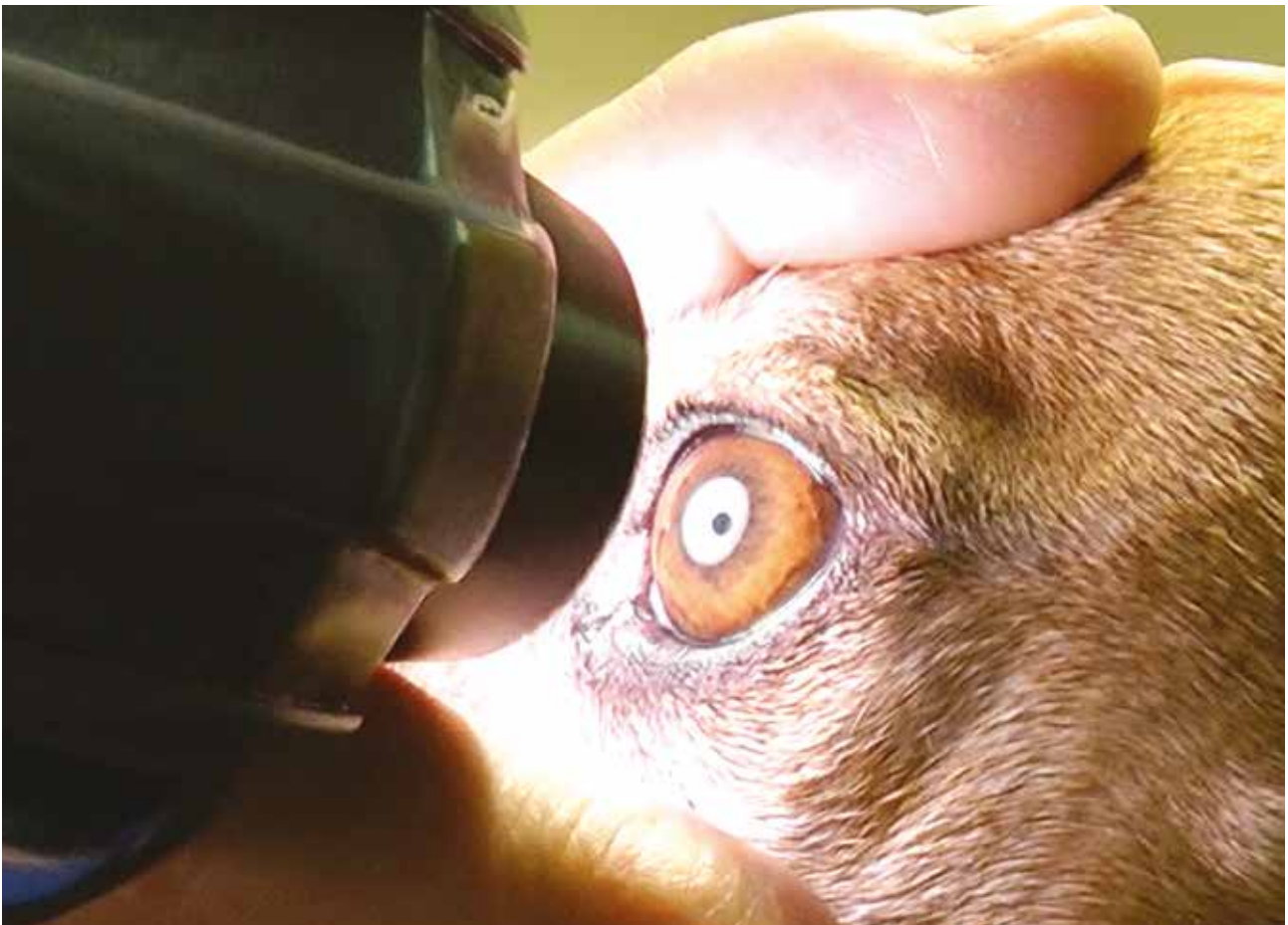In a clinical setting at the cutting-edge, veterinary ophthalmologists have the technical support of advanced instruments to examine, in detail, the Tear Film (TF), the Ocular Surface (OS) microenvironment and the ocular adnexa.

To help performing an accurate OS examination to diagnose OSDs, SBM-Sistemi developed handy instruments for veterinary use.

The OSA-VET is an integrated system for animals' OS and Meibomian Glands (MGs) analysis. It is cable connected to a computer where videos and shots may be stored.

Extensive documentation has been collected on dogs, cats, rabbits and horses but any cooperative animal may be examined.

A dedicated web connected platform (Integrated Clinical Platform – ICP) allows to process all collected data, generate graphics and release documents to be added to the animal's clinical folder. The software is continuously improved to match the users' needs.



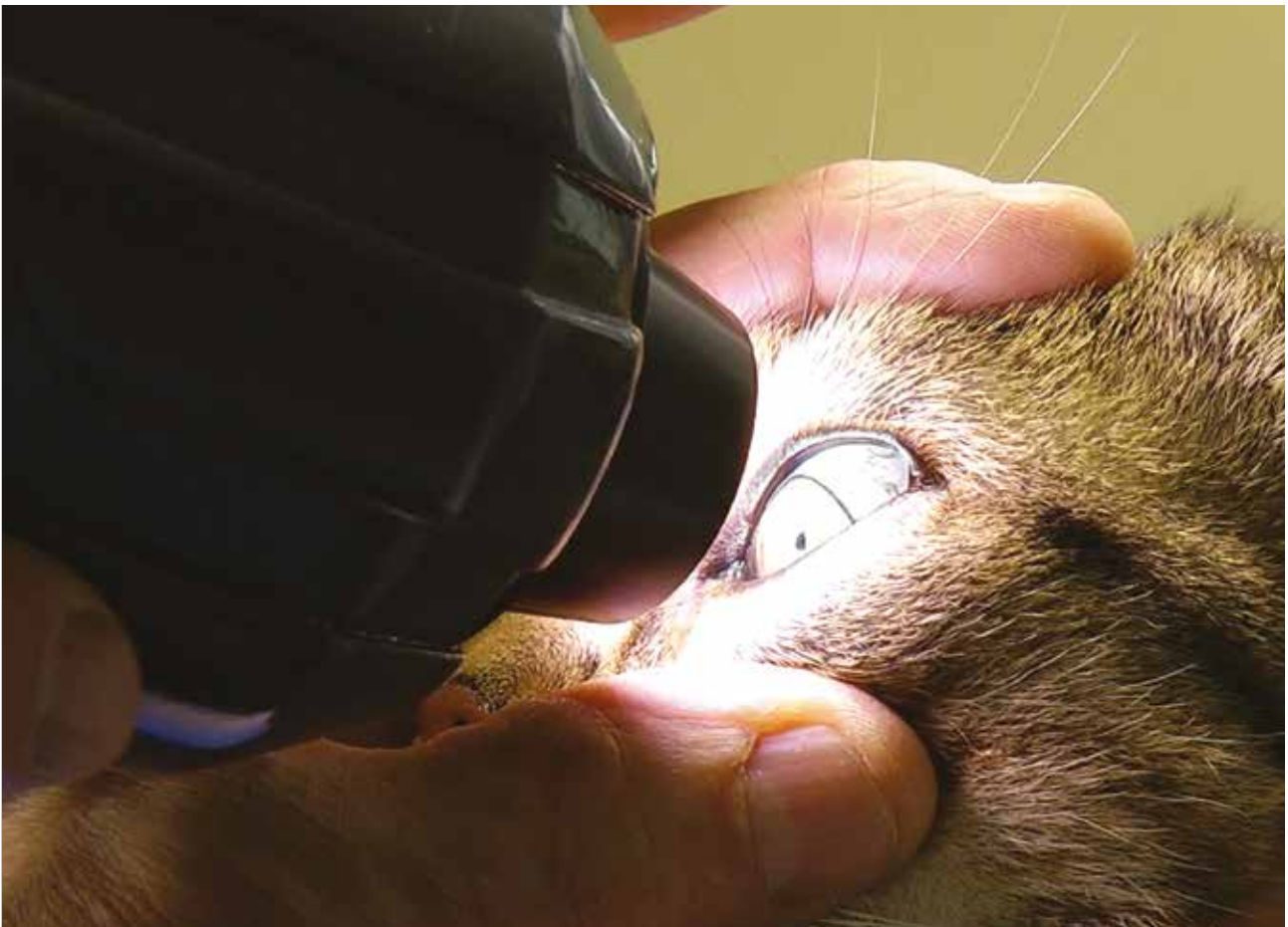STANDARD PROCEDURE

In OSDs, after a complete eye examination, the ocular surface may be further examined with the OSA-VET to check for MGs, TF Lipid Layer (LL), Non-Invasive TF Break-Up Time (NIBUT) and OS topography.

The standard OSA-VET examination may be adapted case by case. The usual procedure is:

1. Video-interferometry to examine the TF-LL Thickness (LLT) and Dynamics (LLD)
2. Video or shots focused on tear meniscus to evaluate Tear Meniscus Height (TMH)
3. Video-interferometry to evaluate NIBUT (a NIBUT grid is added to the OSA-VET)
4. Video or shots to evaluate OS topography (a Placido disc is added to the OSA-VET)
5. Video or shots to examine MGs by Non-Contact Infrared Meibography (NCIM)

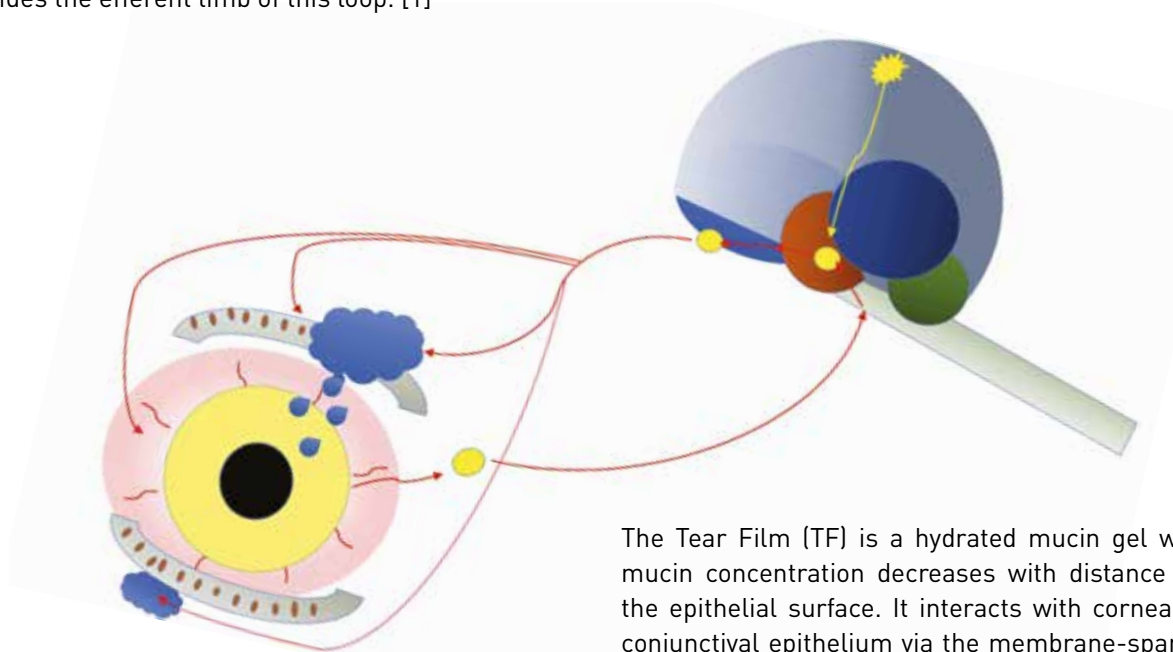
No eyedrops or stains must be used before this procedure.



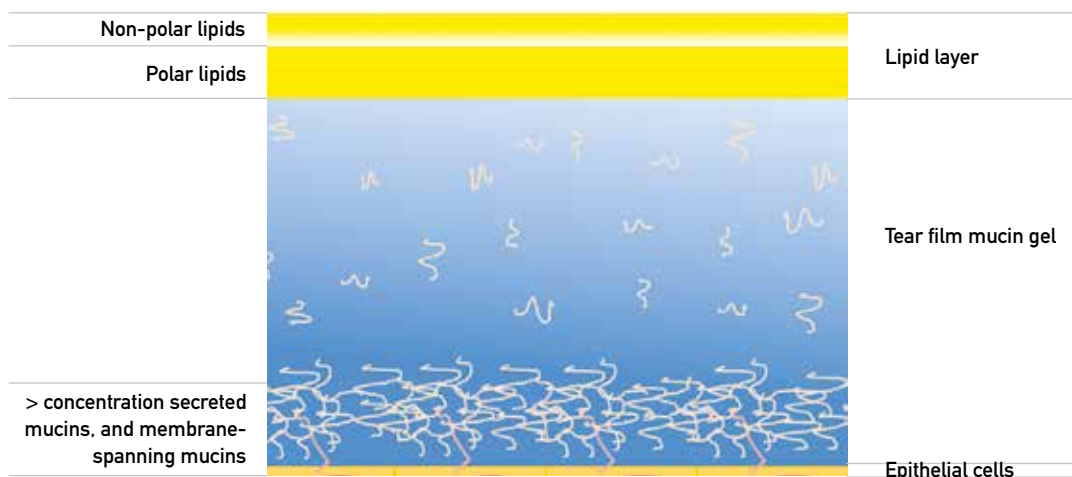
THE OCULAR SURFACE - TEAR FILM INTEGRATED FUNCTIONAL UNIT

Tear homeostasis is achieved reflexly by the lacrimal functional unit (LFU), which consists of the ocular surface, its secretory appendages and the connecting innervation. The trigeminal innervation of the ocular surface epithelia provides the afferent limb of the feedback loop.

The parasympathetic secretomotor innervation of the lacrimal glands, MGs and conjunctival goblet cells provides the efferent limb of this loop. [1]



The Tear Film (TF) is a hydrated mucin gel whose mucin concentration decreases with distance from the epithelial surface. It interacts with corneal and conjunctival epithelium via the membrane-spanning mucins. [2]



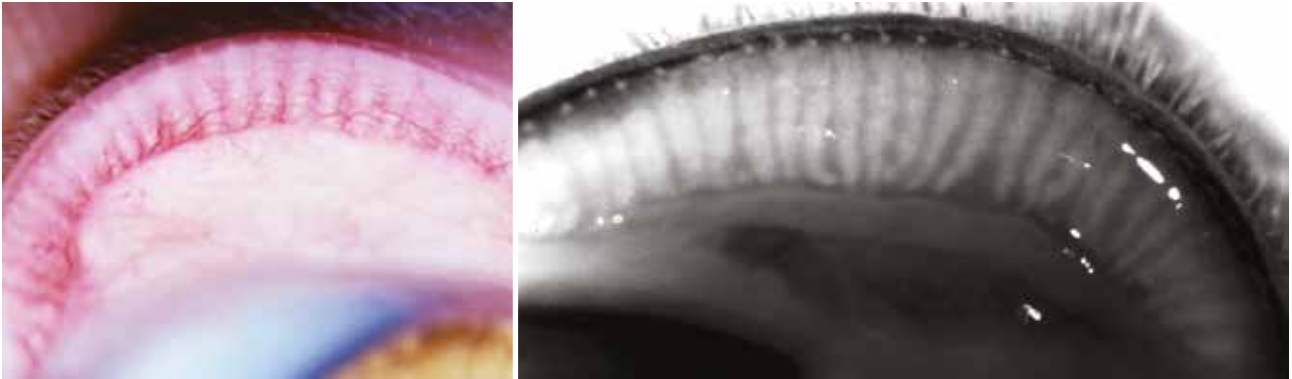Mucins are secreted by the conjunctival goblet cells under autonomous nervous system control. Inflammatory mediators may stimulate mucin secretion and interfere with TF stability.

In most animals the lacrimal glands lie over the superior-temporal part of the globe and within the stroma of the third eyelid. Their secretion of water, electrolytes, proteins and mucins form the aqueous component of the TF.

A superficial lipid layer, composed of polar and non-polar lipids produced by the MGs, limits evaporation of the aqueous component of the TF.

MEIBOMIAN GLANDS

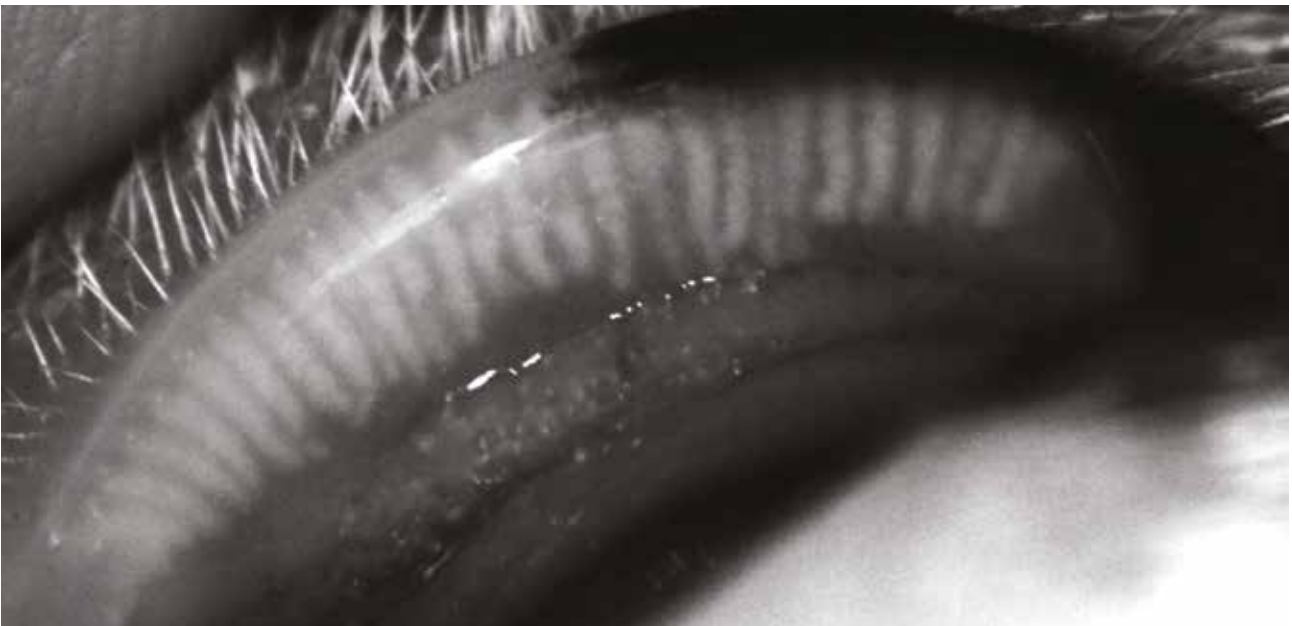MGs are large sebaceous glands located in the eyelids in a regular pattern, with a sequence of 30-40 glands parallel to each other. Their terminal ducts end in orifices along the internal part of the eyelid margin, at the muco-cutaneous junction. The glands are under neural and hormonal control and produce an oily substance that is released in the eyelid margins and spread on the tear film thanks to blinking.



Lipids produced by the MGs are the main component of the superficial lipid layer of the TF. The LL acts as a barrier to decrease the evaporation of the aqueous phase and is also believed to stabilize the TF by lowering surface tension. Hence, meibomian lipids are essential for the maintenance of ocular surface health and integrity. [3]

Changes to the composition of mucins produced by the goblet cells and/or of lipids secreted by the MGs alter the TF stability and increase TF evaporation, a frequent finding in animals' OSDs.

For the differential diagnosis of OSDs it's mandatory to assess the MGs anatomical and functional characteristics and the TF stability and regularity. Hence, an accurate diagnostic protocol should include meibography and tearscope examination.



1. Stern ME et al. The role of the lacrimal functional unit in the pathophysiology of dry eye. *Exp Eye Res*, 78, 409-416, 2004
2. Pflugfelder SC et al. Management and therapy of dry eye disease: Report of the Management and Therapy Subcommittee of the International Dry Eye WorkShop. *Ocular Surface*, 5 (2):163-178, 2007
3. Knop E et al. The International workshop of Meibomian gland dysfunction: Report of the Subcommittee on Anatomy, Physiology and Pathophysiology of the Meibomian Gland. *IOVS* 52, 4, 1938-1978, 2011

DRY EYE DISEASE

Dry eye disease (DED) is the direct consequence of any loss of OS-LFU homeostasis and is a very common problem in animals characterized by a wide scale of more or less pathognomonic clinical signs. However, a large number of cases go undiagnosed, most of all when the quality of the TF (Qualitative Dry Eye) more than the quantity (Quantitative Dry Eye) is affected. An altered composition of the TF increases its evaporation giving rise to the so called evaporative dry eye (EDE). In many cases tear production is maintained or even increased for a compensatory mechanism, the eye appears moist or even wet, but several dry areas are present on the OS.

In such cases the use of tests like the Schirmer Tear Test, commonly used to assess tear production, is misleading if no other exams are performed.

A more accurate TF examination requires the use of interferometry and meibography to evaluate the TF stability on the light of several parameters:

- The LL patterns to assess the LLT and the LLD
- The TF break-up time without the use of fluorescein stain (NIBUT)
- The OS and TF topography (OST) using a Placido disc
- Tear Meniscus Height (TMH)
- MGs number, shape and disposition using the NCIM

TF osmolarity is another important advisable test to be performed whenever possible, although limits to its repeatability and reproducibility have been reported.

MEIBOMIAN GLAND DYSFUNCTION

MGD is a chronic alteration of the meibomian glands, commonly characterized by terminal duct obstruction and/or qualitative/quantitative changes in the glandular secretion.

MGD alters the lipid component of the tear film and is a frequent cause of qualitative dry eye with EDE and the typical signs of eye irritation, clinically apparent inflammation and OSDs. In severe cases, MGD can cause blepharitis. Viceversa, in dogs and cats blepharitis is a frequent cause of MGD.

Functional disorders of the MGs alter the TF-LL, decrease TF stability and increase aqueous phase evaporation from the ocular surface, which, eventually, results in a rise of tear osmolarity.

Aging anatomical changes occur in all studied species with ductal opening hyperkeratinization, obstruction and consequent atrophy with end stage glandular dropout. Several factors contribute to the MGD pathogenesis, like increased meibum viscosity, inflammatory mediators, bacterial lipid-degrading enzymes, hormonal changes and topical or systemic medications. [1, 2]

Qualitative lipid changes may increase viscosity of meibum, raise its melting point and alter the polar and neutral lipid profiles. Polar lipids maintain the lipid layer over the aqueous surface. Without a surfactant, the lipids form lenses on the surface. [3]

Obstruction of the MG orifices decreases delivery of meibum onto the lid margin and TF, causing increased evaporation and dry eye. Stasis of meibum increases its viscosity and internal glandular pressure with ductal dilatation, atrophy of secretory acini and end stage gland dropout. [4]

MGD was present in 70 % of the 150 eyes of dogs affected by OSD examined with the OSA-VET [5, 6]. Cases of MGD have been diagnosed with NCIM also in cats, horses and rabbits. A more detailed diagnostic approach allows to better understand pathogenesis of OS diseases and choose the best treatment available.

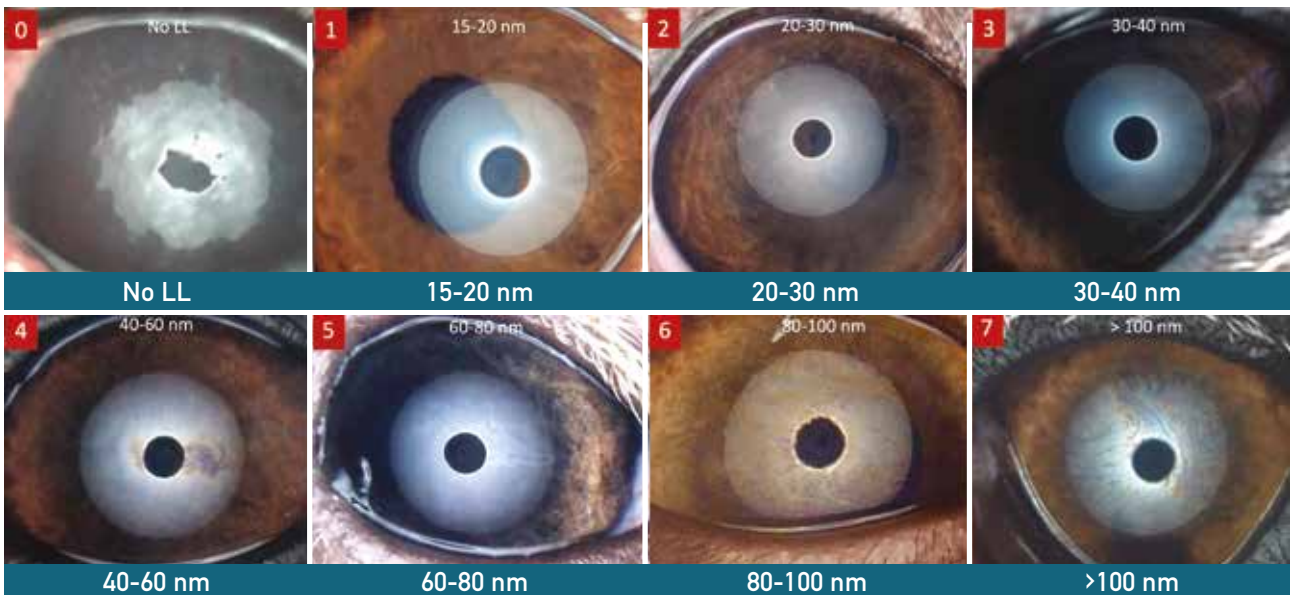
1. McCulley JP, Shine WE. The lipid layer of tears: dependent on meibomian gland function. *Exp Eye Res.* 78:361–365. 408, 2004
2. McCulley JP, Shine WE. Meibomian gland function and the tear lipid layer. *Ocular Surface* 1:97–106, 2003
3. Holly FJ. Formation and rupture of the tear film. *Exp Eye Res.* 15:515–525, 1973
4. Geerling G et al. The International workshop on Meibomian gland dysfunction: report of the subcommittee on management and treatment of MGD. *Investigative Ophthalmology & Visual Science*, 52, 2050-2064, 2011
5. Viñas M, Maggio F, D'Anna N, Rabozzi R, Peruccio C. Meibomian gland dysfunction (MGD), as diagnosed by non-contact infrared Meibography, in dogs with ocular surface disorders (OSD): a retrospective study. *BMC Vet Res* 15, 443, 2019
6. Sartori R, Peruccio C. A case of sebaceous adenitis and concurrent meibomian gland dysfunction in a dog. *Vet SCI*, 7, 37, 2020; doi:10.3390/vetsci7020037

OSA-VET EXAMINATION

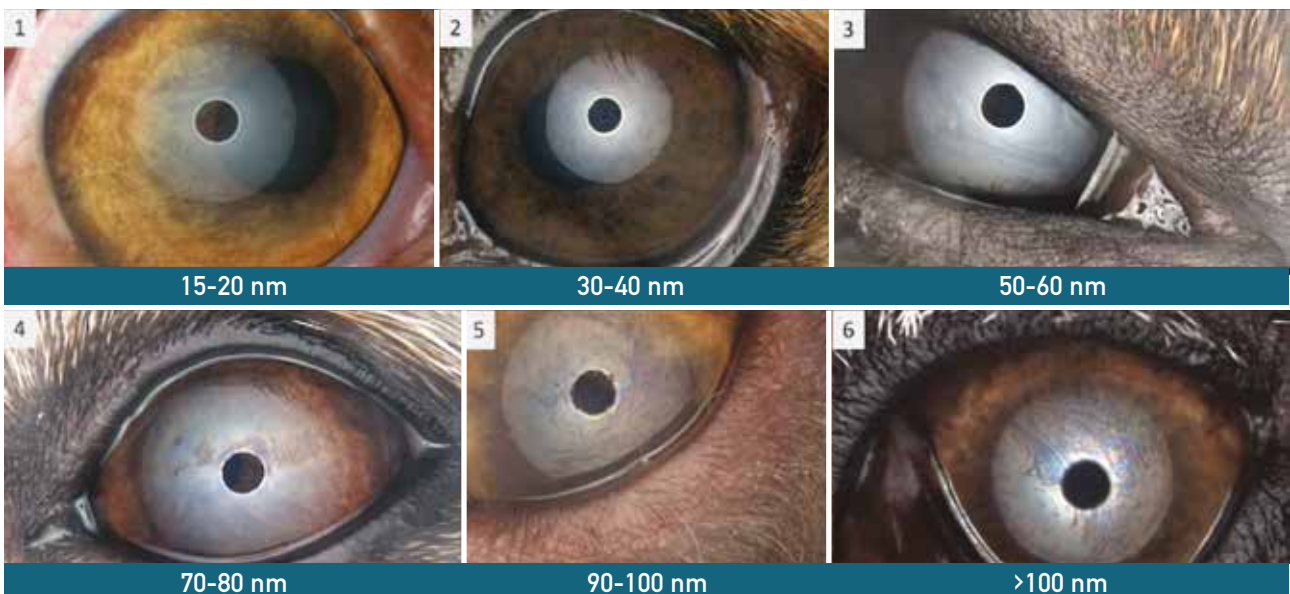
Standard procedure

1. Video-interferometry to examine the TF-LL thickness and dynamics
2. Video or shots focused on the tear meniscus to evaluate TMH
3. Video-interferometry to evaluate NIBUT
4. Video or shots with a Placido disc to evaluate OST
5. Video or shots to examine MGs by NCIM
6. Evaluation of the exams with the integrated clinical platform (ICP)

Grading scales to evaluate the Lipid Layer Thickness and Dynamics



7 grades LL Frame Grading Scale (FGS) adopted to evaluate LLT.



6 grades LL Video Grading Scale (VGS) adopted to evaluate LLT and LLD.

TEAR MENISCUS HEIGHT

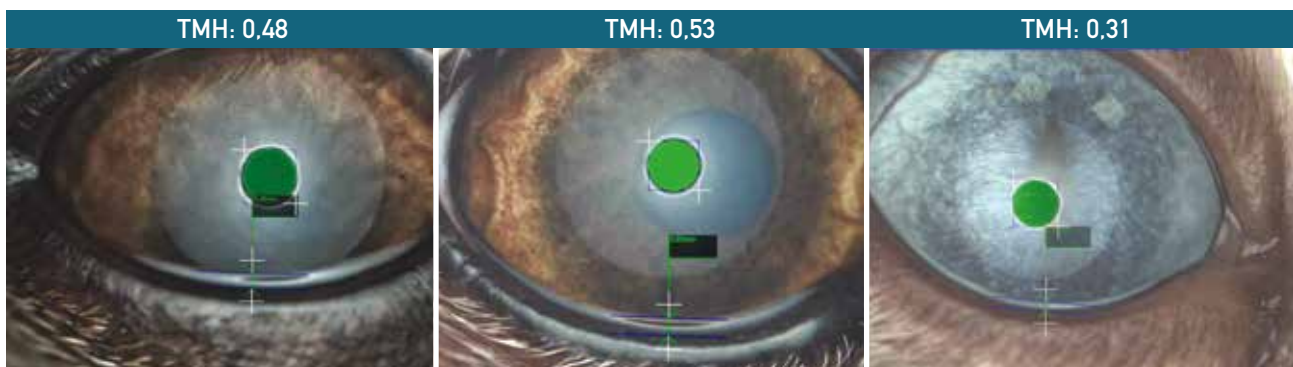
The tear meniscus is a reservoir of tear fluid that, in humans, contains 75% to 90% of the total tear volume. [1] The TMH must be examined after a blink to avoid interferences of tear evaporation or exit from lower eyelid anomalies and trichiasis, most common in dogs and cats with medial canthal defects.

The TMH estimates tear volume. In humans the average values may vary between 0.2 and 0.7 mm [2] but values less than 0.25 mm are suggestive of dry eye for some authors. [3]

TMH evaluation with the OSA-VET is based on the interferometric reflection pattern in the space between the lower eyelid and the cornea.

In animals with normal STT, eyelid conformation and tear drainage system we rated the dog's TMH at 0.53 ± 0.11 mm, the cat's TMH at 0.31 ± 0.09 mm.

1. Holly FJ. Physical chemistry of the normal and disordered tear film. Trans Ophthalmol Soc U K. 104, (pt4), 374-380, 1985
2. Doughty MJ et al. The tear (lacrima) meniscus height in human eyes: a useful clinical measure or an unusable variable sign? Cont Lens Anterior Eye. 25 (2):57-65, June 2002
3. Bustos DE et al. Dry Eye Syndrome. AAO, EyeWiki, Dec. 2019



OCULAR SURFACE TOPOGRAPHY

After a blink the TF becomes gradually unstable to break-up after a period of time which varies according to its composition and dynamics. By adding a Placido disc to the OSA-VET the instrument projects a series of concentric circles over the TF interferometric image. If the OS is normal and the TF is stable, the circles have a regular continuous disposition.

If the TF is unstable, after the blink, the circles become progressively misshaped, sometimes interrupted by agglomerates of aggregated mucins, dry spots or heterogeneous material. If the surface of the cornea is irregular, the circles over the TF show the same altered disposition, closely approximating the corneal surface defects.



NON-INVASIVE BREAK-UP TIME

NIBUT is the time elapsed between a blink and the appearance of a real discontinuity in the TF.

NIBUT is usually longer than the invasive test performed with fluorescein (BUT).

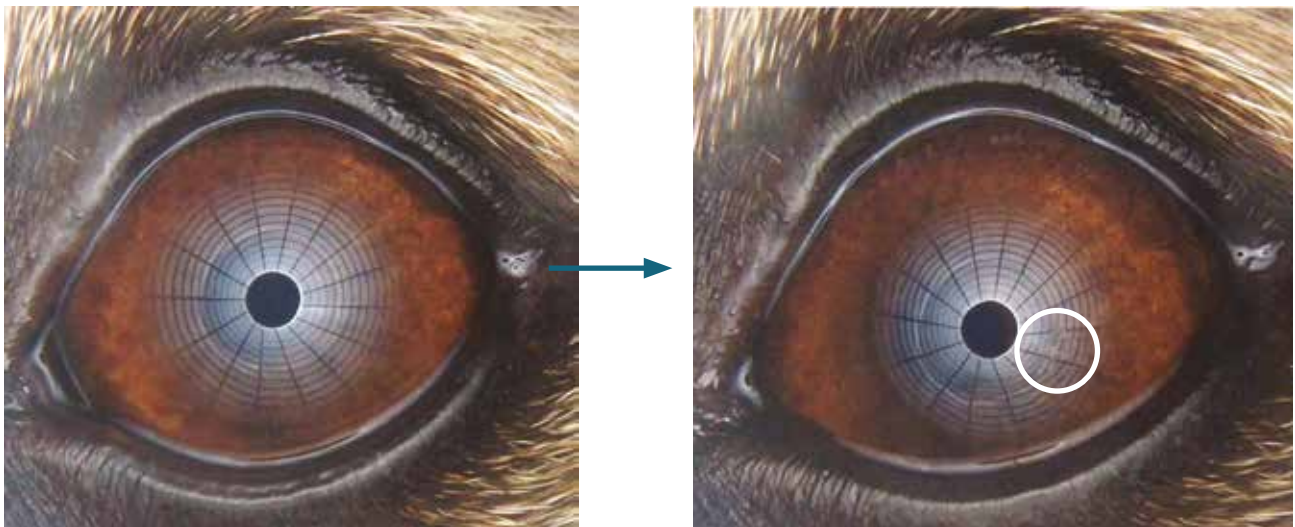
A pre-rupture phase, known as the tear thinning time (TTT), can also be evaluated by observing the distortion of a keratometer mire, the reflected grid image of changing interference patterns. [1]

In humans NIBUT is often greater than 30 seconds and abnormal values are those of less than 15 seconds. These values correspond to the NIBUT tests done on normal dogs and cats, but in most cases continuous eye and third eyelid movements prevent NIBUT evaluation. A more accurate protocol to stimulate spontaneous complete blinking to start the test is under evaluation.

In animals NIBUT should be the ideal exam to test TF stability without adding one drop from a moistened fluorescein strip that delivers an unpredictable amount of fluid to the eye, even when the strips are shaken to remove excess fluid. [2]

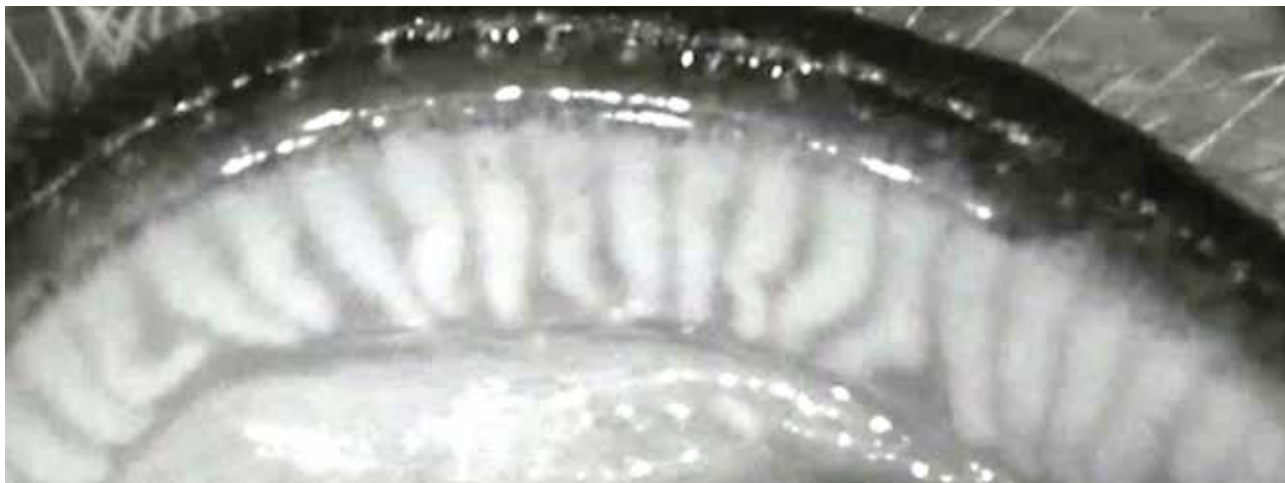In the human eye one drop of fluid from the fluorescein strip is about 17 μL , more than the total TF volume. [3]

1. Veys J et al. Assessment of the tear film. Essential Contact Lens practice, JnJvisioncare Institute, 2016, 1-12
2. Johnson ME, Murphy PJ. The effect of instilled fluorescein solution volume on the values and repeatability of TBUT measurements. Cornea. 2005a; 24:811-17
3. Snyder C, Paugh JR. Rose bengal dye concentration and volume delivered via dye-impregnated paper strips. Optom Vis Sci. 1998;75:339-41

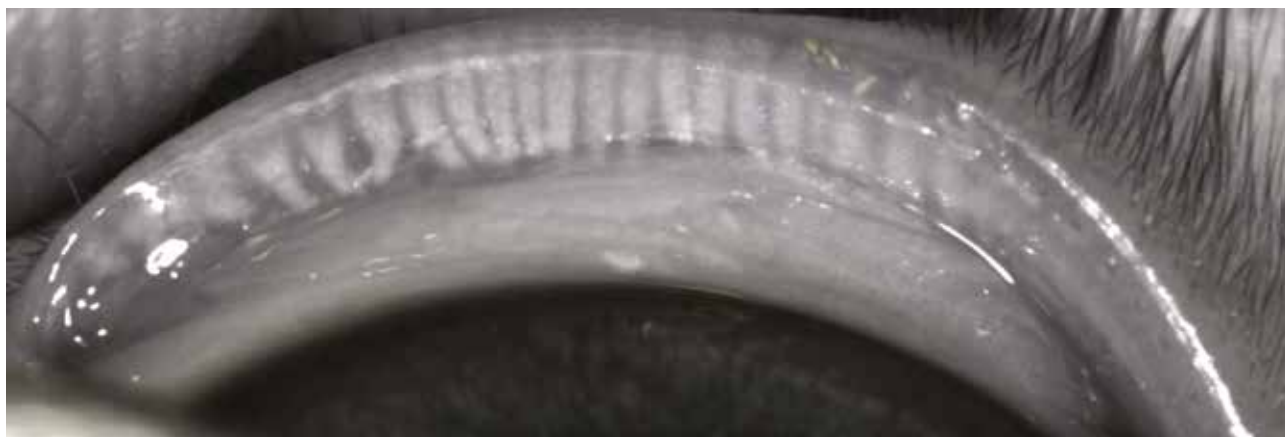

NON-CONTACT INFRARED MEIBOGRAPHY

Dog



Cat



Meibography is an in vivo technique to visualize the morphology of the MGs including their ducts and acini.

By using OSA-VET it is possible to adjust the brightness and contrast of images to allow the best evaluation. By selecting the lid area to be examined, it's possible to define the percentage of tissue without MGs due to glandular shortening and drop-out and to grade the result on a meibography score (meibo-score), focused on clinical interpretation, follow-up and prognosis.

The morphologic changes are classified in 4 degrees with a coloured scale:

- Loss between 0 and 25% (green)
- Loss between 25 and 50% (yellow)
- Loss between 50 and 75% (orange)
- Loss between 75 and 100% (red)

In several cases there is variability of the disease along the lid length and between the upper and lower eyelids. In dogs and cats it is easier to examine the upper eyelid, while in humans the lower eyelid is usually examined.

The animal's cooperative temper and the owner's compliance are essential requirements.

Dogs and cats are examined without specific restraint with the owner or an assistant holding the head.

Horses may be sedated with detomidine (10 micrograms/Kg) and butorphanol (10 micrograms/Kg) and an auricolopalpebral nerve block may be carried out. The animal's head may be placed on a support, specifically made for this purpose. Several images are usually recorded, only the best shots are selected, improved as needed and then processed for grading analysis.

TEAR FILM EVAPORATION

The LL limits TF evaporation, this is the main reason why LLT is considered an important factor to control TF stability.

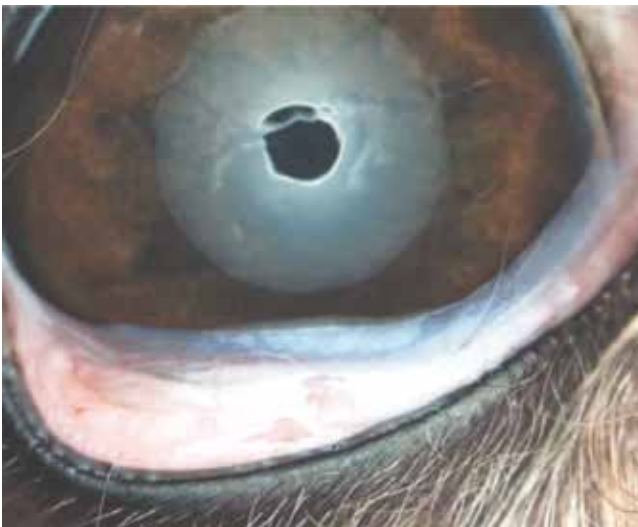
TF evaporation does not necessarily correlate with LLT that is just a parameter to be considered. LL composition also plays an important role. Bacterial lipases may break down esters into component acids and alcohols, causing a defective TF-LL structure with increased evaporation. [1]

Contaminants and clumping of lipid-mucins increase LL evaporation and decrease NIBUT.

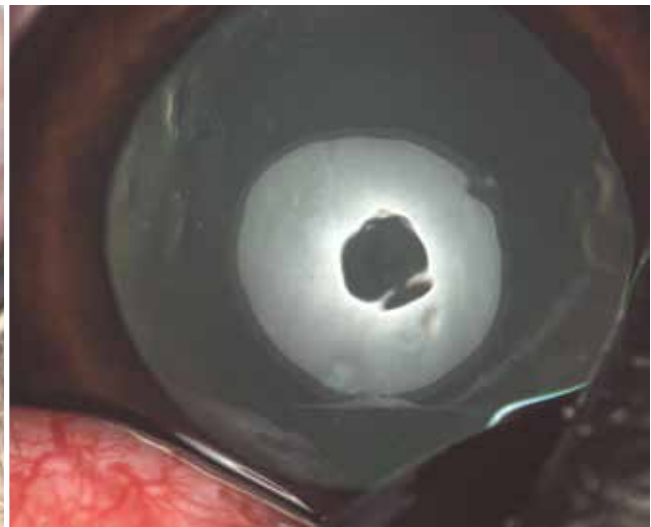
Blinking is another important conditioning factor to be considered, since the insufficient distribution of the TF over the OS increases TF evaporation.

1. King-Smith PE et al. Tear Film Breakup and Structure Studied by Simultaneous Video Recording of Fluorescence and Tear Film Lipid Layer Images. IOVS, July 2013, Vol. 54, No. 7, 4901

THE TF EVAPORATION AT THE START OF ANESTHESIA IN TWO DOGS WITH A THINNER AND A THICKER LL



*LLT Grade 1 VGS (20 nm)
After 20" mucins start to aggregate.*



*LLT Grade 3 VGS (50 nm)
TF distortion is evident only after 40".*

FREQUENTLY ASKED QUESTIONS FROM OSA-VET USERS (FAQ)

1

Question

- Can I save the images or videos I took and put them in a folder on my personal computer or on a USB key? How can I do that? Can I save more than one image or video at the same time?

Answer

- The procedure to save the images or videos in a folder is as follows:
 1. Select the images/videos and click on "Export"
 2. Choose the folder or the computer space where you want to save them
 3. Click on "Save"
 4. For saving more than one image at a time, it is enough to select all the images and proceed as at point 1

2

Question

- Is there a recommended distance between the device and the cornea or the eyelid? Why should I change the FOCUS while performing a meibography or interferometry exam? What would change?

Answer

- You must see the image in focus, the distance depends upon the focus settings.
Change of FOCUS settings by clicking + or – on "Focus"
 1. By clicking on + (more than 50%) you increase the distance from the eye in order to focus on the lipid layer and decrease the size of the interferometric image
 2. A middle size image is observed when the focus is at 50%
 3. By clicking on – (less than 50%) you decrease the distance from the eye in order to focus on the lipid layer and increase the size of the interferometric image

3

Question

- Why should I change the EXPOSITION while performing a meibography or interferometry exam? What would change? Does the animal see the difference?

Answer

- Change of EXPOSITION settings by clicking + or – on "Expos."
 1. By clicking on + (more than 50%) you lighten-up the image you observe
 2. By setting the exposition at 50% the image should have a standard lightening
 3. By clicking on – (less than 50%) you darken-up the image you observe but the light emitted by the instrument is always the same
- When you change the exposition the light emitted by the instrument is always the same and the animal doesn't perceive any difference

4

Question

- Can I insert the same animal twice if I am performing an exam in two different days? Why should I only insert one animal once?

Answer

- Yes, I can insert the same animal twice, but it will not be possible for the system to compare different exams of the same animal. The system will consider the two exams as two different animals. It is always better to insert one animal once

5

Question

- Is blinking recommended before interferometry? If so how many times?

Answer

- In the average interferometric sequences spontaneous blinking is a frequent finding. The video recorded with interferometry should be compared to a video grading scale to evaluate the thickness of the lipid layer including the changes sometimes present in a dynamic sequence after a blink

Spontaneous blinking should be stimulated to evaluate NIBUT, a blue light emitted on the contralateral eye by an assistant may be used to get the dazzle reflex

A sequence of 3 blinks is considered ideal to perform this exam in humans. In dogs we consider one blink acceptable. In any case it's important to avoid forced blinking with compression to the eyelids

6

Question

- How about the lighting in the exam room? Bright light, dim light or dark room?

Answer

- It is important to perform interferometry and meibography in a room with a low intensity diffused light. Direct light from a lamp or a window may be reflected on the ocular surface, decreases the quality of images and increases image blooms caused by reflected light

7

Question

- If the patient is using eyedrops or ointments, do I need a wash out time before the exam?

Answer

- Conventionally we suggest to stop the administration of eyedrops and ointments at least 24 hours before performing interferometry. Ointments should be stopped also for meibography

8

Question

- Can I compare the results of two or more different exams of the same animal? How?

Answer

- Yes, by selecting the exams and clicking on "Compare". The system opens a page with all the exams so that the clinician can see the difference between different periods, or judge the efficacy of a treatment

9

Question

- Could the ICP software undergo some changes when I update my Windows operating system on my personal computer? How can I go back to the original settings?

Answer

- Yes, it often happens that the system undergoes some changes when the operating system is updated. To go back to the original settings it is necessary to choose the voice "Settings" and then the button "Reset" at the "Video settings" voice

10

Question

- How can I change the settings of the meibography exam in order to obtain an image or a video when using the foot pedal or keypad?

Answer

- It is necessary to choose the voice "Settings", then "General", and "Select the foot pedal action" ("video" or "photo")

11

Question

- While performing meibography is there a self-timer function?

Answer

- Yes, it is possible to use the timer function while taking pictures. It is possible to customize the timer settings by clicking on "Settings", then "Instruments", and then changing the values of "Autoshot Timer", "Autoshot repeat", "Autoshot interval"

12

Question

- If I made a mistake and I inserted the right eye as the left one or viceversa, can I change that?

Answer

- Yes, by selecting the video / image, clicking on it with the right button of the mouse, and changing the eye, the exam, or the lid in case of meibography. It is also possible to cut or delete the exam

13

Question

- Why should I wear gloves while performing meibography?

Answer

- Because the reflection from my skin can compromise the quality of the images or videos I will be working on

14

Question

- Can I change the language of the system?

Answer

- Yes, by selecting the language once you have gone into "Settings"

15

Question

- Can I insert my logo on the reports?

Answer

- Yes, by selecting "Settings", then "Company", then "Use custom logo". I can then choose the logo I want to use from a selected path

16

Question

- Can a change in my antivirus software interfere with the ICP software?

Answer

- Yes. If this happens, it is necessary to change the settings in the antivirus software, by removing the ICP software from the antivirus workout, so that the antivirus does not detect the ICP software as harmful for the computer

ABBREVIATIONS

ADDE	Aqueous Deficient Dry Eye
BUT	Break-Up Time
DED	Dry Eye Disease
EDE	Evaporative Dry Eye
FGS	Frame Grading Scale
KCS	Kerato Conjunctivitis Sicca
ICP	Integrated Clinical Platform
LFU	Lacrimal Functional Unit
LL	Lipid Layer
LLD	Lipid Layer Dynamics
LLT	Lipid Layer Thickness
LOSW	Loss of Ocular Surface Wettability
MGs	Meibomian Glands
MGD	Meibomian Gland Dysfunction
NCIM	Non-Contact Infrared Meibography
NIBUT	Non-Invasive Break-Up Time
OS	Ocular Surface
OSDs	Ocular Surface Disorders
OST	Ocular Surface Topography (Placido disc)
OU	Oculus Uterque, both eyes
PRTT	Phenol Red Thread Test
QLDE	Qualitative Dry Eye
QNDE	Quantitative Dry Eye
STT	Schirmer Tear Test
SM	Strip Meniscometry
TF	Tear Film
TMH	Tear Meniscus Height
TTT	Tear Thinning Time
VGS	Video Grading Scale



**The only complete tool
for assessing the ocular surface**

CLINICAL CASES

Authors: Claudio Peruccio, Elena Barbasso, Daniela Terlizzi



Case 1 – Red, wet eyes

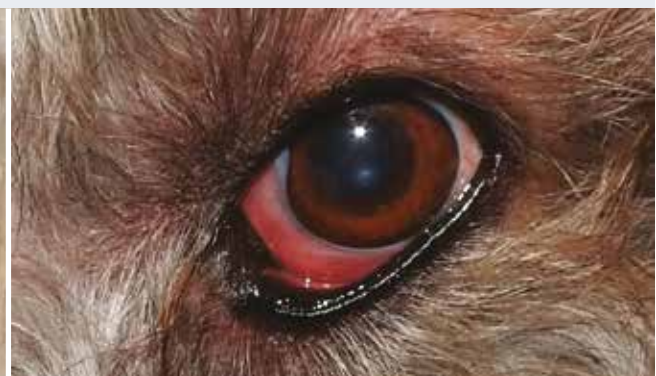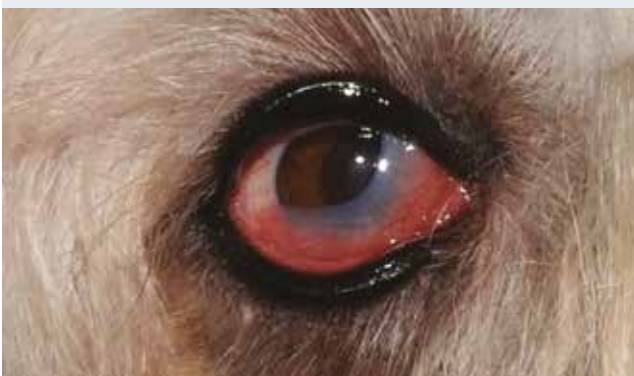Dog: Old English Sheepdog, female, 8 years old

Clinical history

Long lasting history of blepharo-conjunctivitis and wet, red eyes. The owner reports the dog often scratches his face.

Clinical signs at presentation

The hairs cover the eyes, the eyelids are wet, the third eyelids have a non-pigmented margin and are red.



Key data after a complete ophthalmic examination

Blinking: 9 incomplete blinks/min.

Conjunctivitis involving both palpebral and bulbar conjunctiva OU.

Extensive involvement of OU MGs with multiple chalazia.

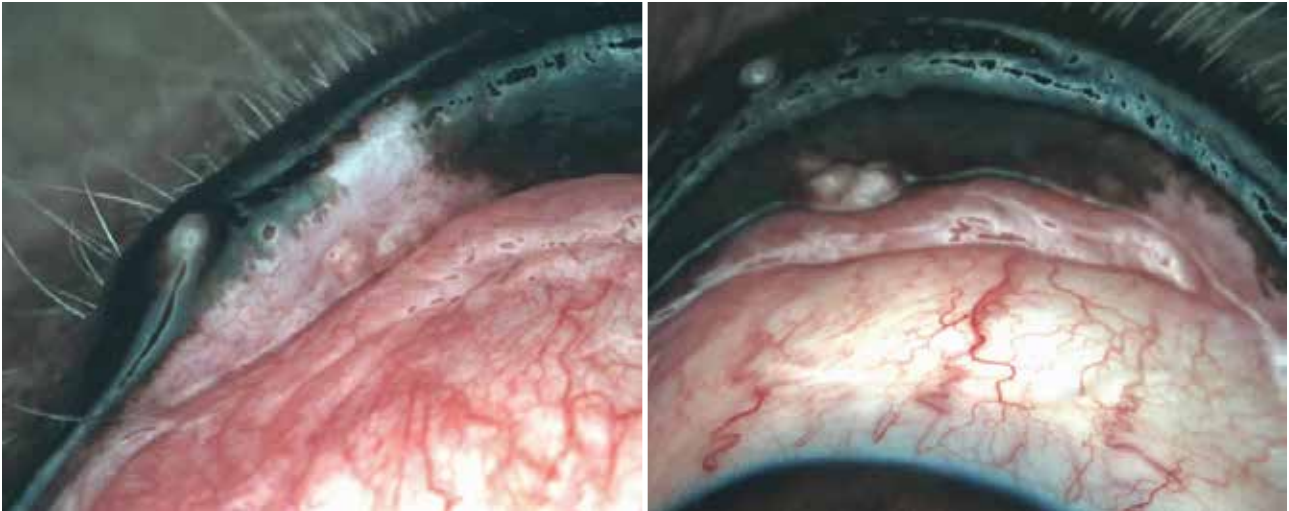
STT

- Right eye 19 mm/min
- Left eye 29 mm/min

Fluorescein and Rose Bengal positive with punctate staining.

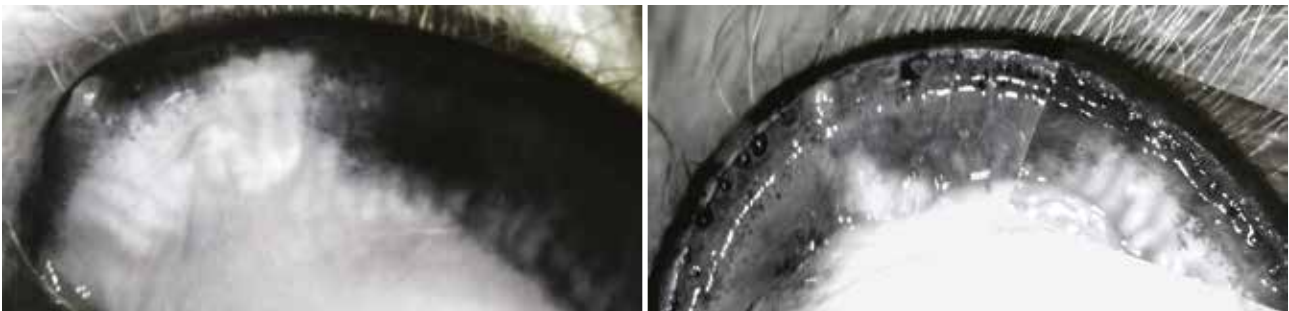Osmolarity (i.Pen®Vet)

- Right eye 353 mOsm/L
- Left eye 354 mOsm/L



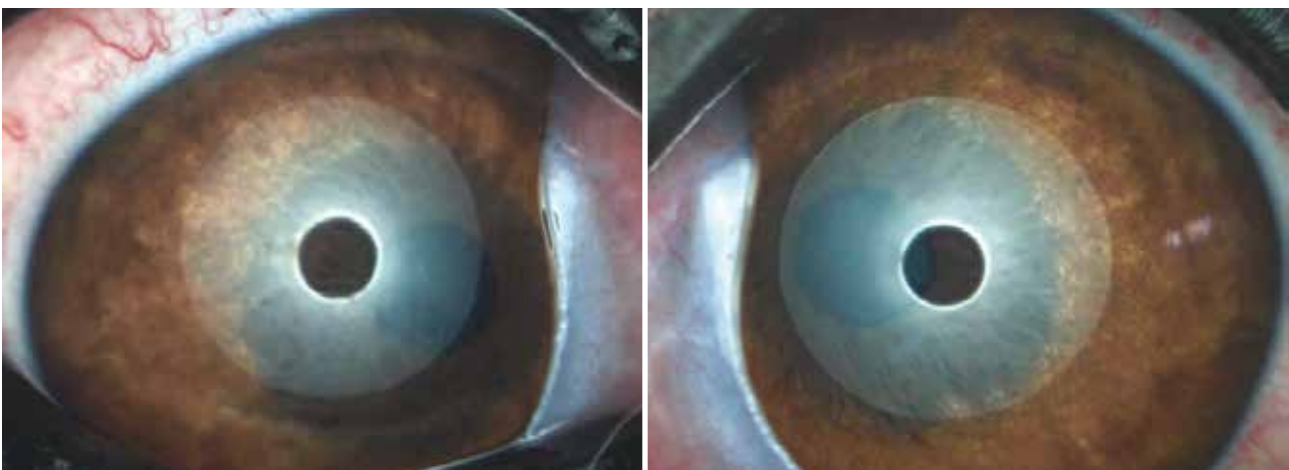
OSA-VET – Shots with interferometric setting.

Meibography



MGD with multiple chalazia, obstruction of MGs orifices along most of the eyelid margins, ductal dilatation with accumulation of dense meibum, areas of MGs atrophy and dropout.

Interferometry



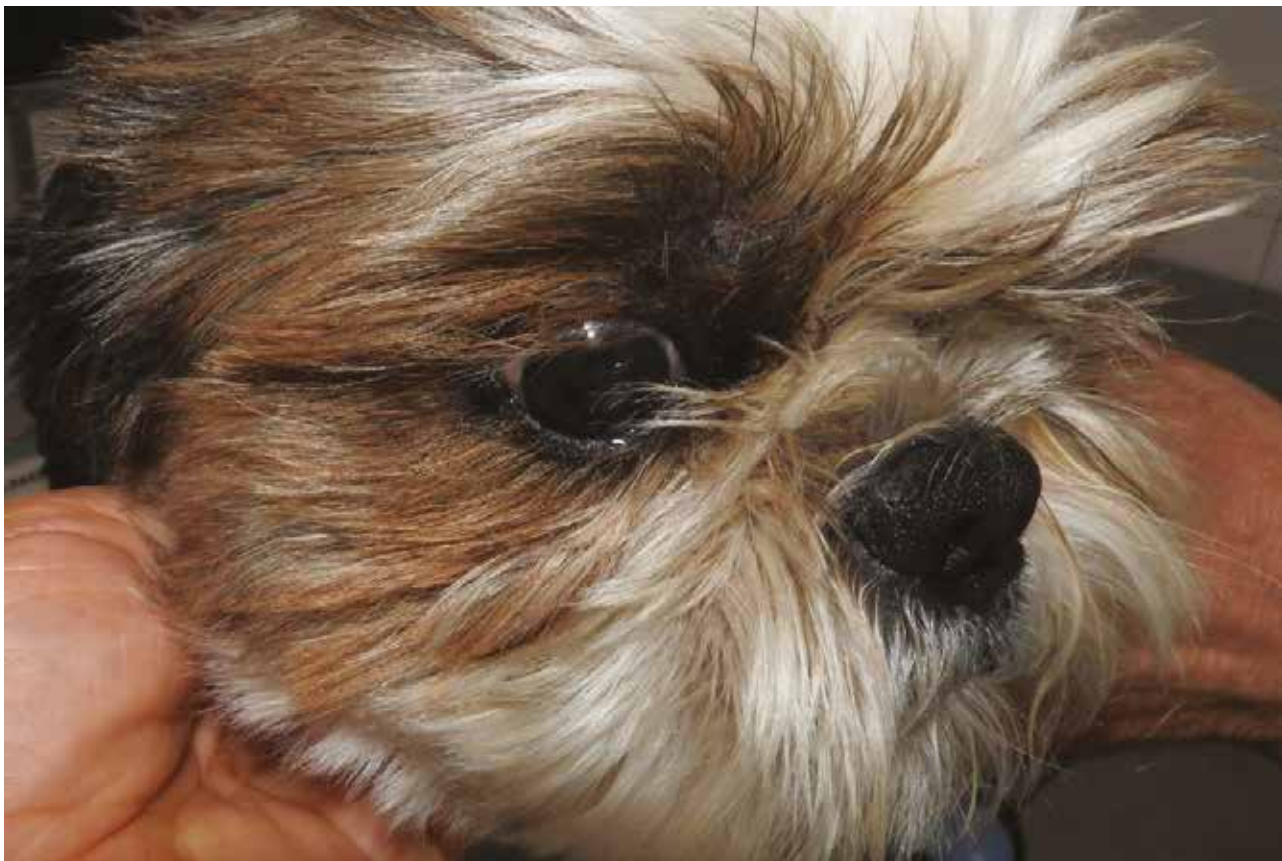Thin but regular LLT of about 15-20 nm with no visible waves.

Diagnosis

MGD with TF instability, qualitative dry eye and EDE. Failure of the eyelid margin lipidic barrier to control tear leakage with consequent loss of TF and wet eyes.

In short: MGD, QLDE, EDE.

Authors: Claudio Peruccio, Elena Barbasso, Daniela Terlizzi



Case 2 – Wet eyes with redness and opacification

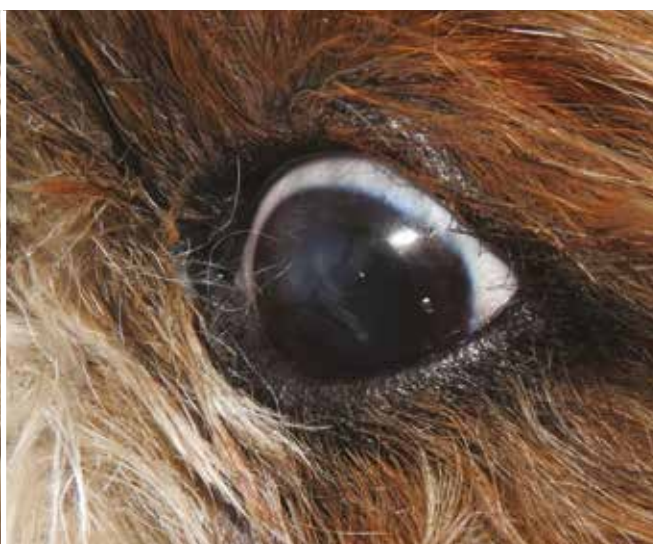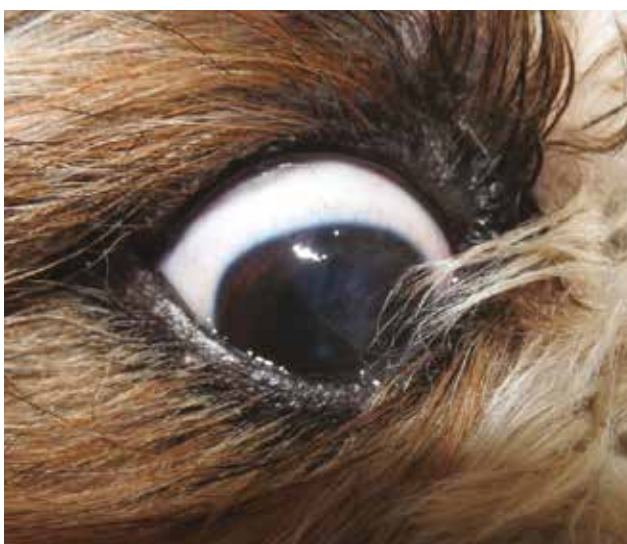Dog: Shih Tzu, male, 5 years old

Clinical history

The owners report the dog has opaque eyes and the eyelids are always wet.

Clinical signs at presentation

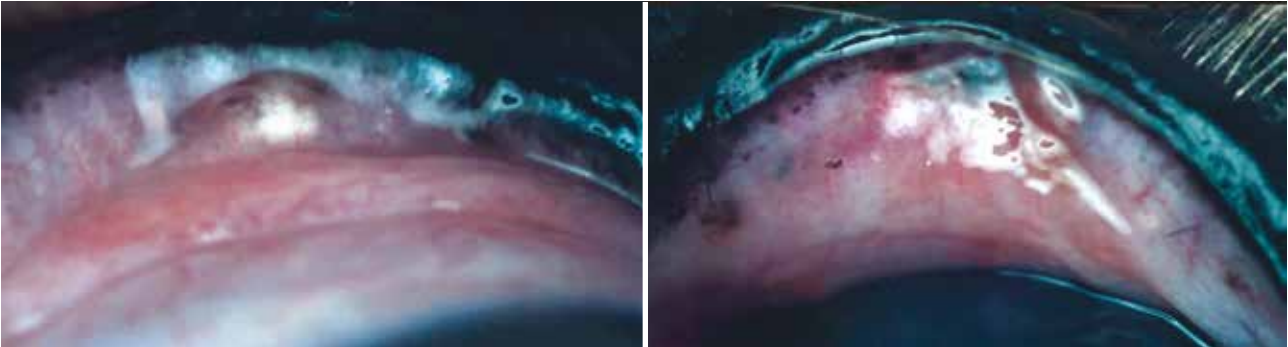
At the medial canthus the hairs are in contact with the eye and are wet, the cornea is opaque.



Key data after a complete ophthalmic examination

Blinking: 1 complete / 7 incomplete blinks/min.

Conjunctivitis involving the palpebral conjunctiva.



OSA-VET – Shots with interferometric setting.

STT

- Right and left eye: 19mm/min

SM

- Right eye 9 mm
- Left eye 8 mm

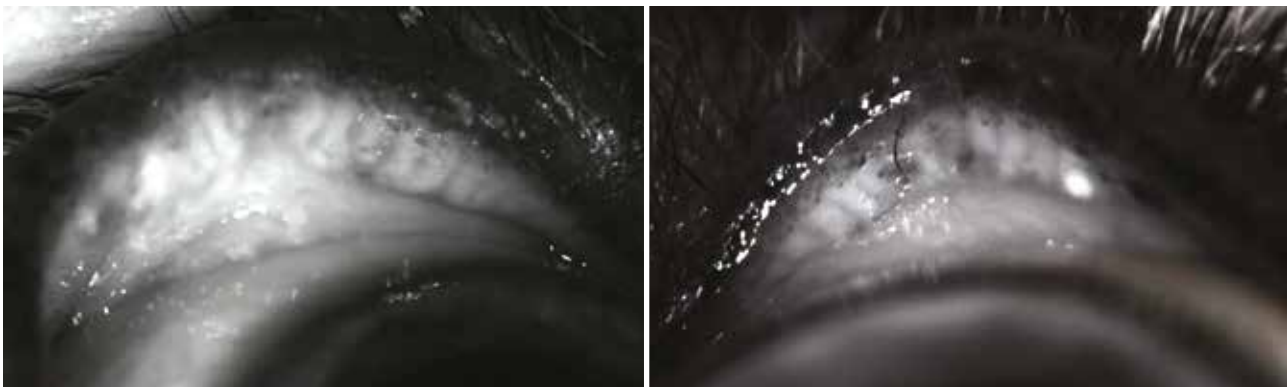
Osmolarity (i.Pen®Vet)

- Right eye 282 mOsm/L
- Left eye 306 mOsm/L

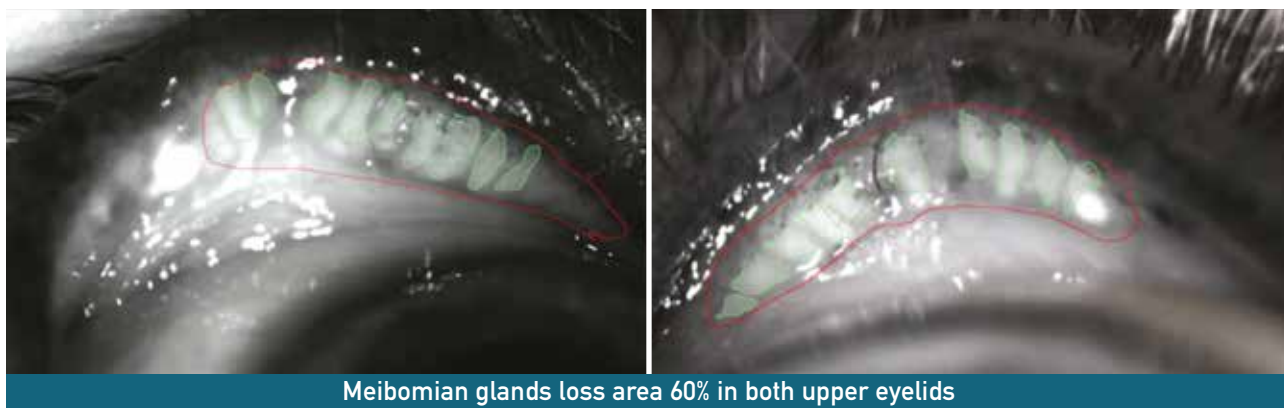
Fluorescein: right eye negative;
left eye faint positivity in the dorso-medial quadrant

Rose Bengal: right eye positive in the centro-medial quadrant;
left eye positive in the dorso-medial quadrant

Meibography

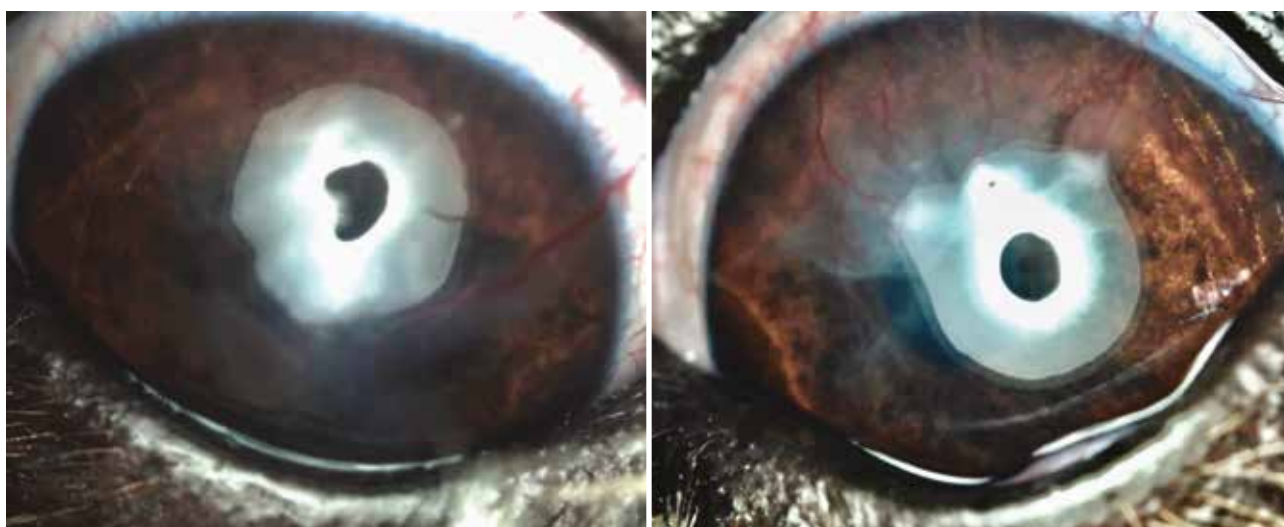


The four eyelids are affected by MGD, in the upper lids multiple chalazia and ectopic cilia are clearly visible with NCIM.

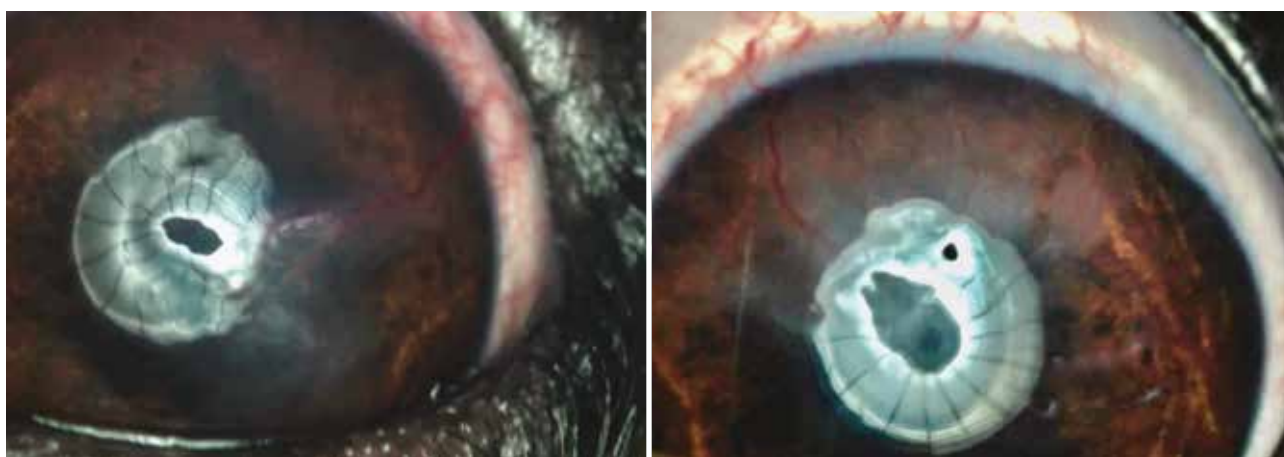


The MGs loss area in both eyelids with manual examination is 60%.

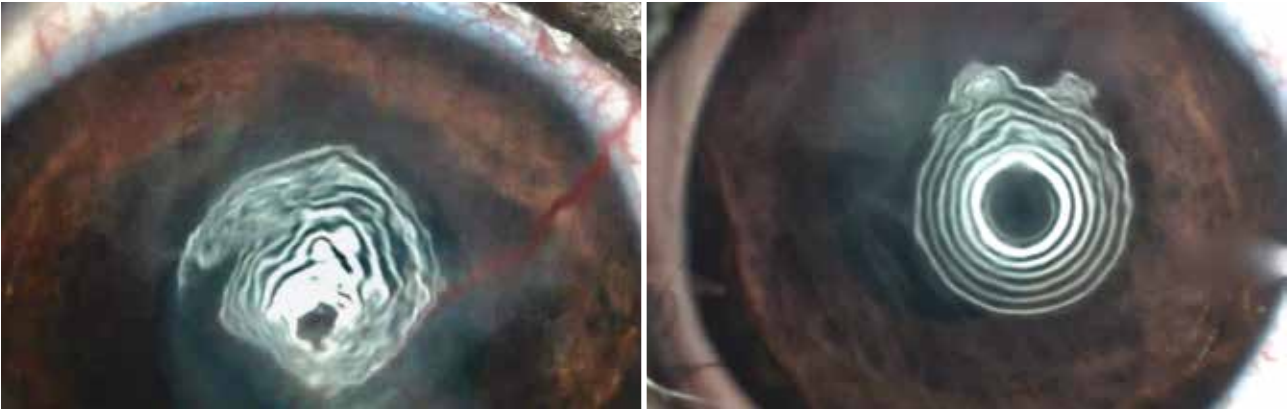Interferometry



NIBUT



Placido disc topography



OST: right eye irregular in the centro and dorso-medial quadrant; left eye more irregular in the dorso-medial quadrant.

Diagnosis

MGD with TF instability, QLDE and EDE. Trichiasis and ectopic cilia causing tears moistening, OS defects with keratitis and corneal scarring.

In short: MGD, QLDE, EDE.

Focus on hair growth from the meibomian glands

The central meibomian duct may be compared to the hair follicles of the eyelashes in embryology and, although MGs are not associated with hairs, their embryologic ectodermal development shows considerable similarities in structure and epithelial differentiation to that of the hair follicle. [1]

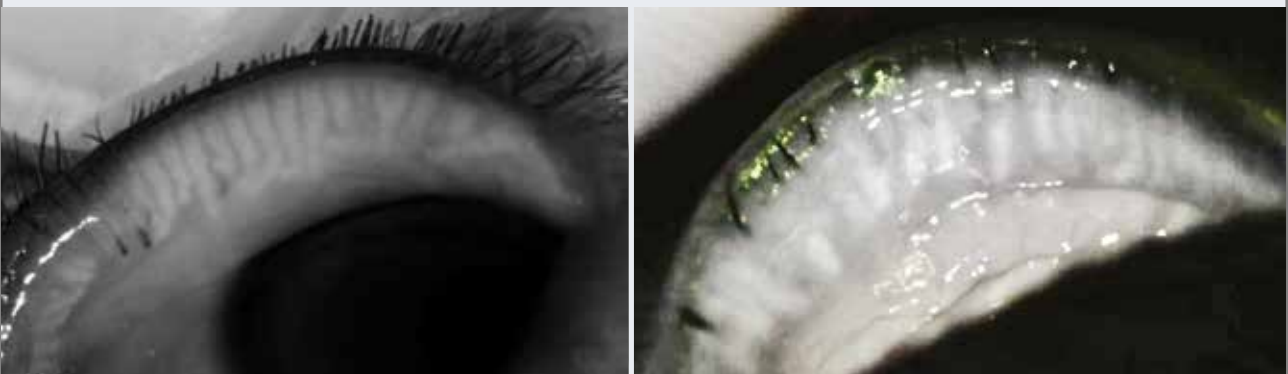If germ cells fail to differentiate completely to MGs, they become pilosebaceous units instead and hairs may grow giving rise to distichiae or ectopic cilia.

The MGs can develop a hair also in a disease state, such as chronic blepharitis and MGD. [1,2]

- Distichiae develop from undifferentiated gland tissue and arise from the MGs ductal openings
- Ectopic cilia have the same origin as distichiae but emerge through the palpebral conjunctiva
- MGs cysts with multiple hairs may be present in some dogs. Based on our experience it's important to pay specific attention to breeds like Shih Tzus, Toy Poodles and Yorkshires.

Non-contact infrared meibography is useful to evaluate the number of MGs involved, the presence of hairs under the palpebral conjunctiva and make a better diagnosis.

1. Knop E, Knop N, Millar, et al. The international workshop on meibomian gland dysfunction: report of the subcommittee on anatomy, physiology, and pathophysiology of the meibomian gland. *Invest Ophthalmol & Vis Science* 2011, 52, 1938-1978
2. Vinas M, Maggio F, D'Anna N, et al. Meibomian gland dysfunction (MGD), as diagnosed by non-contact infrared Meibography, in dogs with ocular surface disorders (OSD): a retrospective study. *BMC Vet Res* 2019, 15, 443-450



Distichiasis.

Authors: Claudio Peruccio, Elena Barbasso, Daniela Terlizzi



Case 3 – Opaque right eye with OU muco-purulent discharge

Dog: Shih Tzu, female, 7 years old

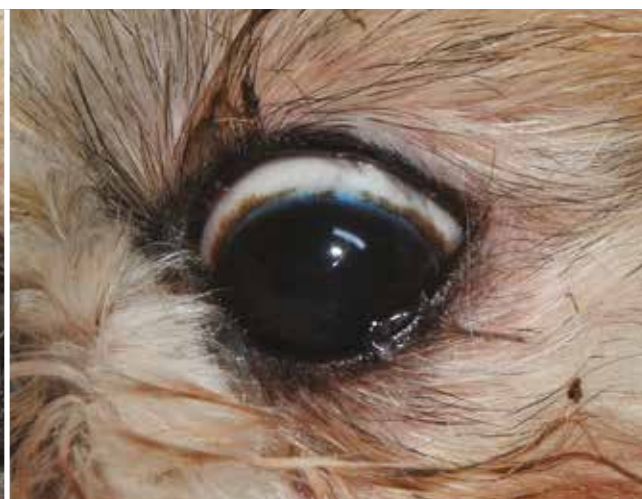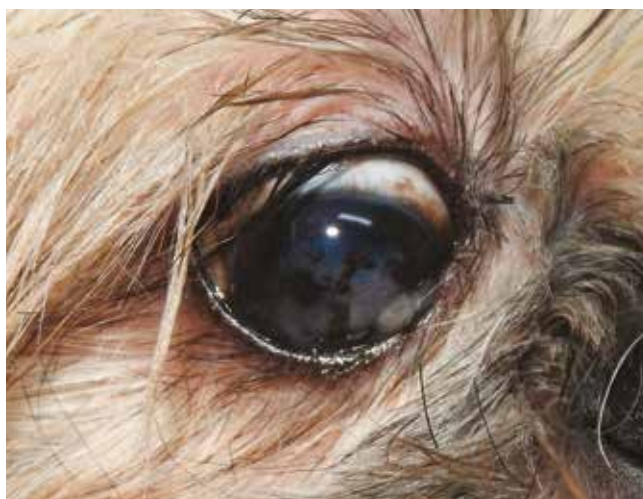Clinical history

Long lasting history of corneal ulcers in the right eye, treated with conventional medical therapy and conjunctival flap surgery.

Clinical signs at presentation

Right eye: muco-purulent discharge, eyelid crusting, dense central corneal opacity.

Left eye: eyelid crusting.



Key data after a complete ophthalmic examination

STT

- Right eye 22 mm/min
- Left eye 25 mm/min

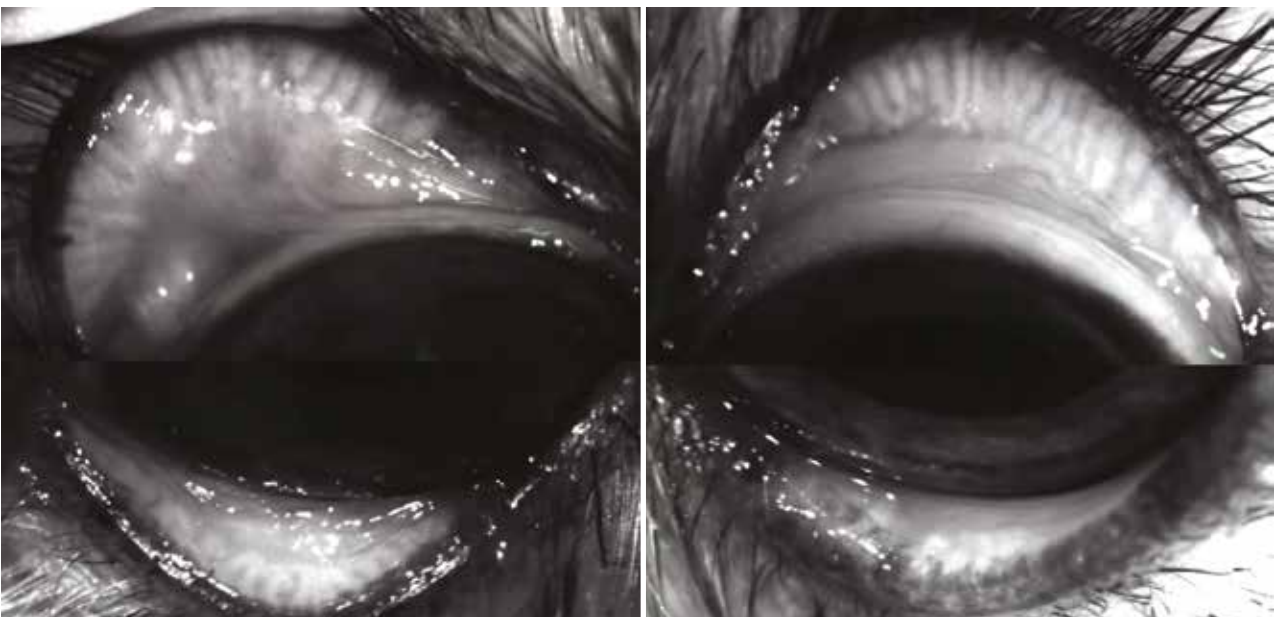Osmolarity (i.Pen@Vet)

- Right eye 299 mOsm/L
- Left eye 297 mOsm/L

Multiple areas of ectopic cilia under the right upper eyelid, some under the lower right and both left eyelids. Large central vascularized corneal leukoma on the right eye.

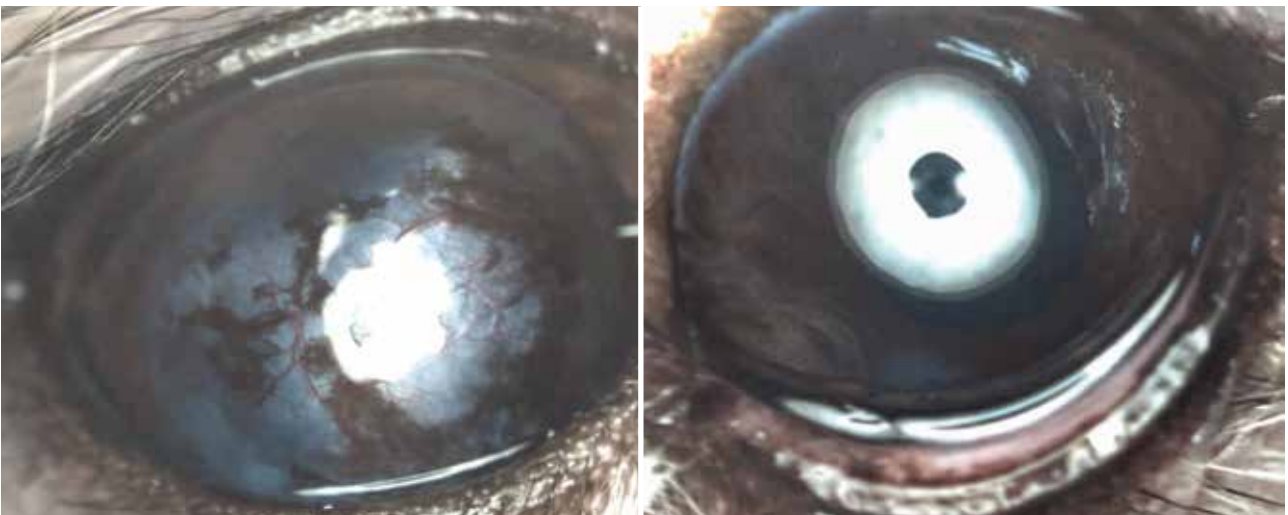Medial canthus trichiasis OU with mild keratitis in the left eye.

Meibography



Small chalazia, areas of MGD and ectopic cilia are present in the four eyelids.

Interferometry

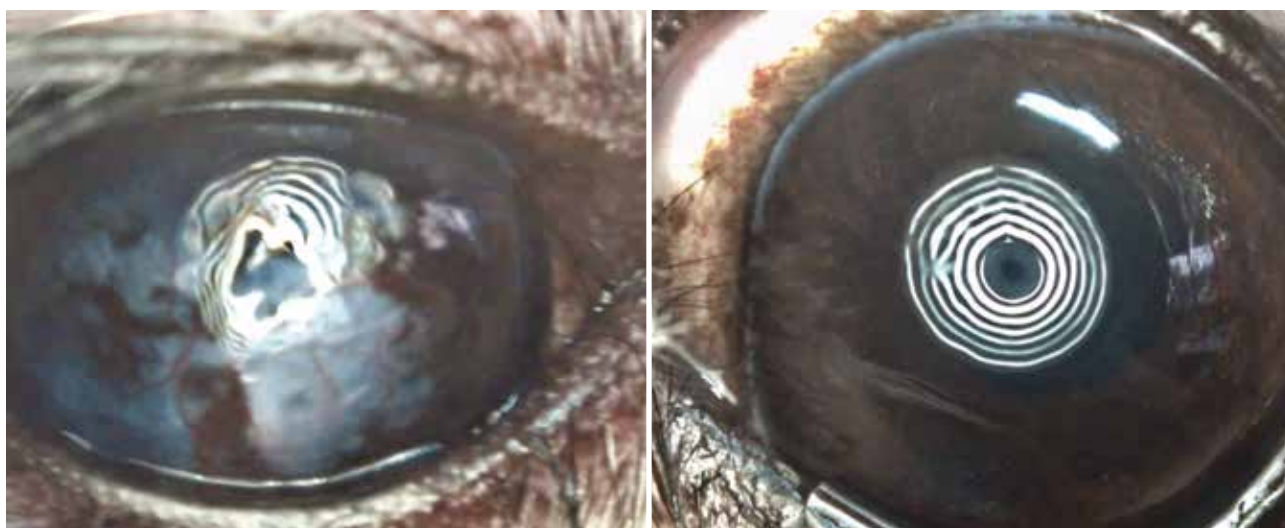


TF LL: right eye untestable (grade 0 FGS); left eye 30-40 nm (grade 3 FGS).



NIBUT: right eye untestable due to corneal leukoma; left eye untestable due to continuous contact of hairs of the medial canthus with the OS.

Placido disc topography


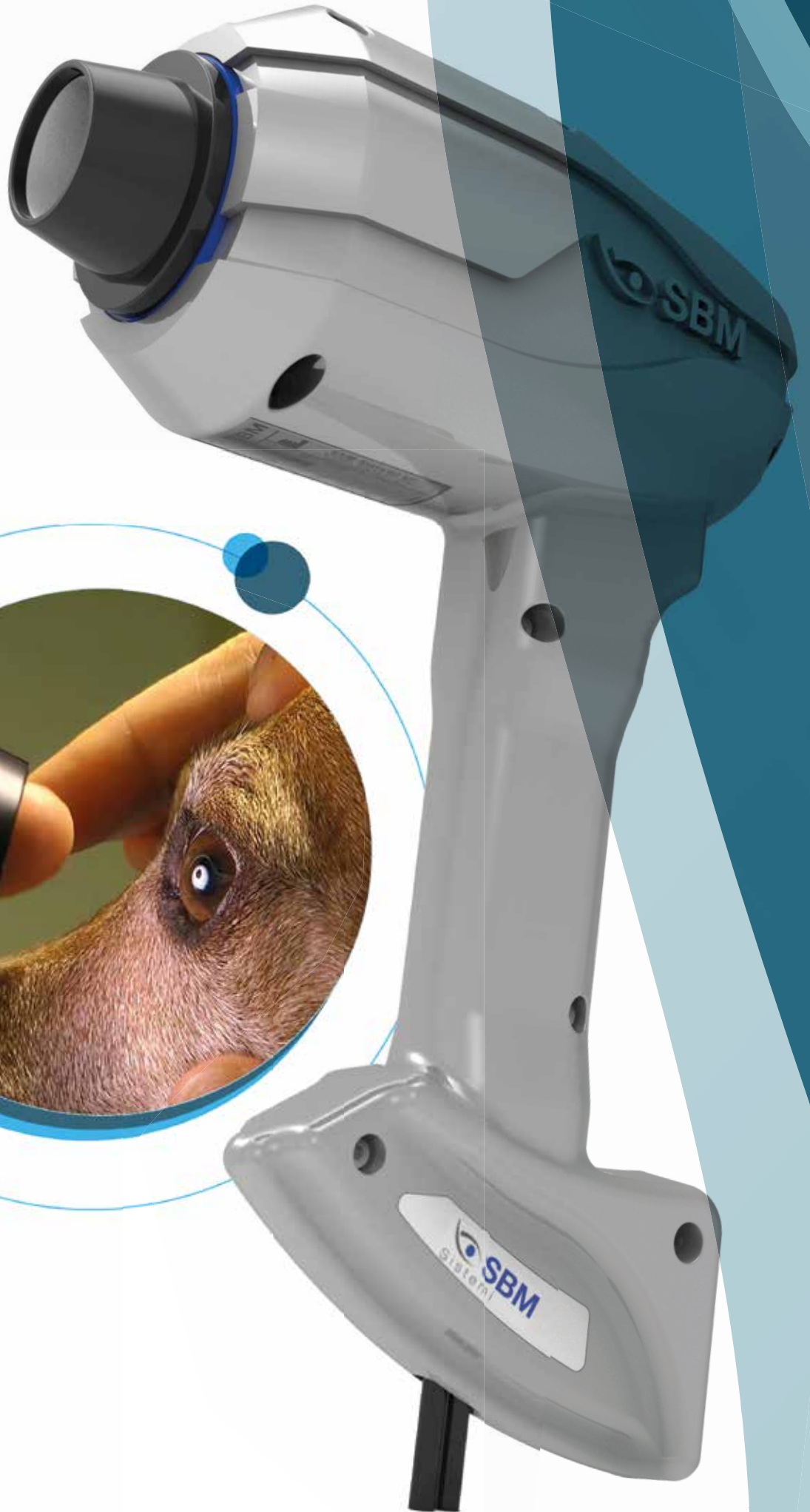


OST: right eye irregular in all quadrants; left eye irregular in the medial quadrant.

Diagnosis

Trichiasis, cilia ectopica, MGD, OS defects with corneal scarring and keratitis. TF instability, QLDE and EDE.

In short: MGD, QLDE, EDE.



Sistemi
SBM

Authors: Claudio Peruccio, Elena Barbasso, Daniela Terlizzi



Case 4 – Dry eyes with redness and opacification

Dog: Cavalier King Charles Spaniel, male, 6 years old

Clinical history

History of chronic mucous discharge and red eyes treated with tobramicin/dexamethasone or NSAIDs.

Referred because of redness and opacification OU.

Clinical signs at presentation

Red eyes with crusty eyelids, mucous and hairs at the fornix and on the ocular surface.

Corneal opacity with areas of pigmentation and keratitis, more intense in the right eye.

Key data after a complete ophthalmic examination

STT

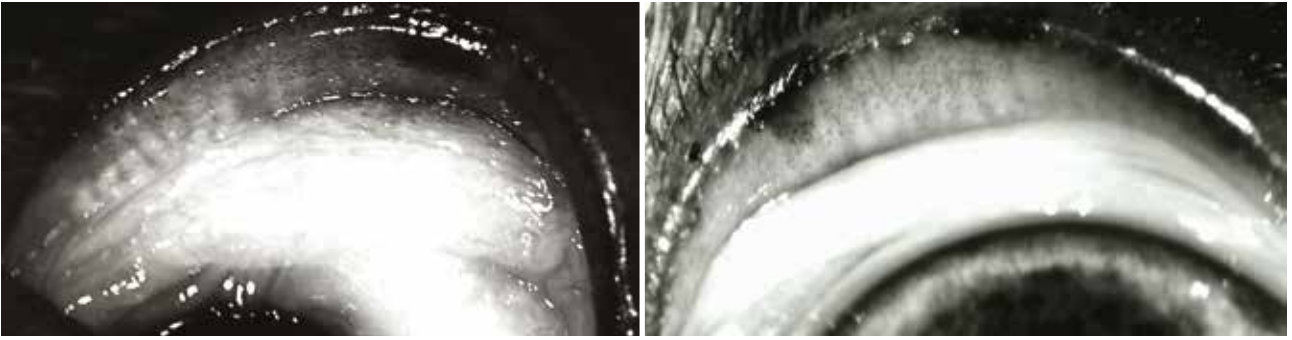
- Right eye 4 mm/min
- Left eye 3 mm/min

Osmolarity (i.Pen@Vet)

- Right eye 346 mOsm/L
- Left eye 328 mOsm/L

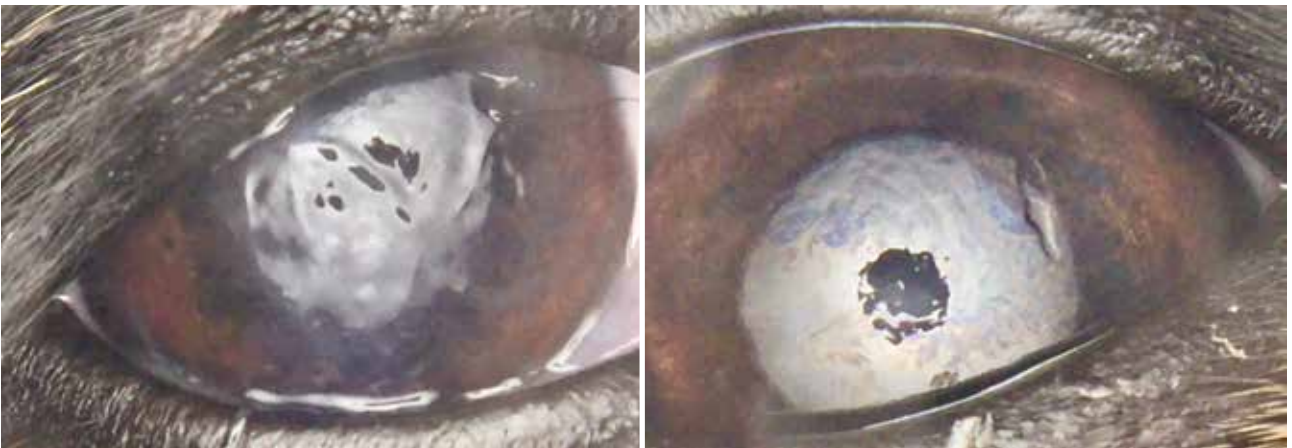Mild fluorescein and Rose Bengal staining on the dorsal quadrant in both eyes.

Meibography



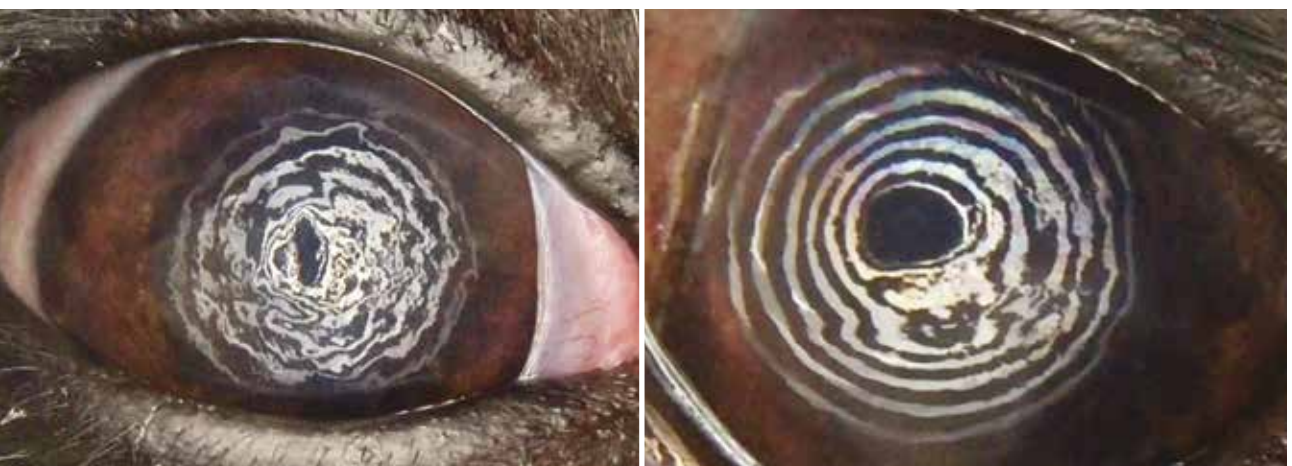The MGs appeared normal for size, number and distribution in both eyes.

Interferometry



TF LL: right eye grade 0 (VGS), left eye grade 4 (VGS).

Placido disc topography



OST: right eye irregular in all quadrants, left eye more irregular in central cornea.

Diagnosis

Quantitative dry eye (tear deficient dry eye) with clinical signs of kerato-conjunctivitis sicca. Incomplete blinks increase TF evaporation. The OS is involved in the inflammatory vicious circle causing epithelial defects with corneal vascularization, pigmentation, loss of wettability and, again, increased evaporation.

In short: QNDE, KCS, EDE.

Authors: Claudio Peruccio, Elena Barbasso, Daniela Terlizzi



Case 5 – Wet eyes with some corneal opacification and continuous blinking

Dog: Chihuahua, female, 11 years old

Clinical history

The owners complain that the eyes are always wet and the dog scratches her face.

Clinical signs at presentation

The skin of the 4 eyelids is wet and their margin is extensively altered. Loss of pigment along the lower eyelids.

The MGs and their ductal openings are widely altered. A whitish leucoma is present in the ventral quadrant of the right cornea.

The dorsal quadrant of the left cornea is mildly opaque with some pigment. Few blood vessels are visible OU.

Key data after a complete ophthalmic examination

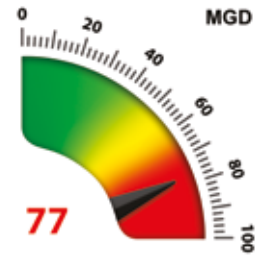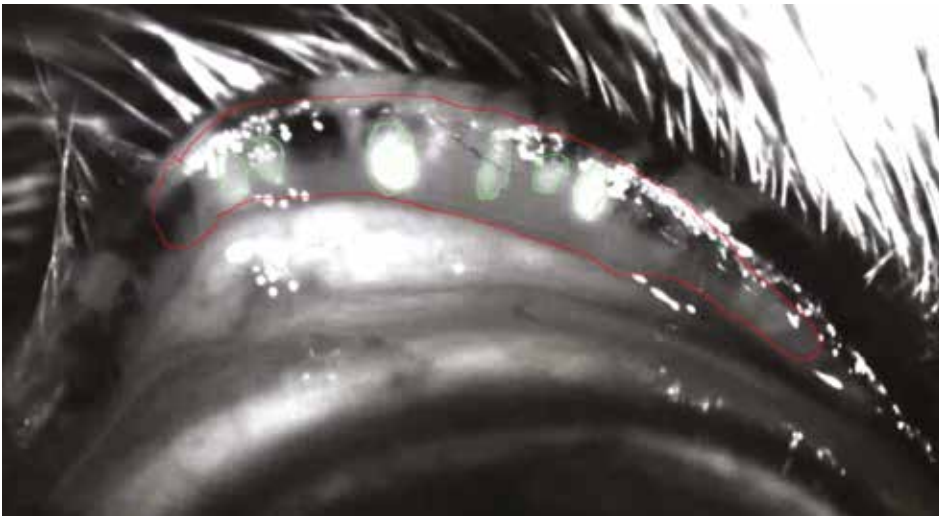
- Wet eyes
- Continuous blinking. 8 complete and 26 incomplete blinks in 60 seconds
- STT: 30 mm/min OU
- MGD in the 4 eyelids
- Outcome of keratitis OU

Meibography

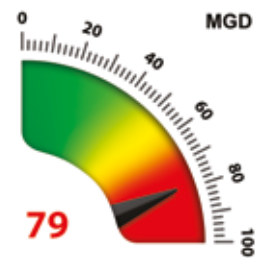
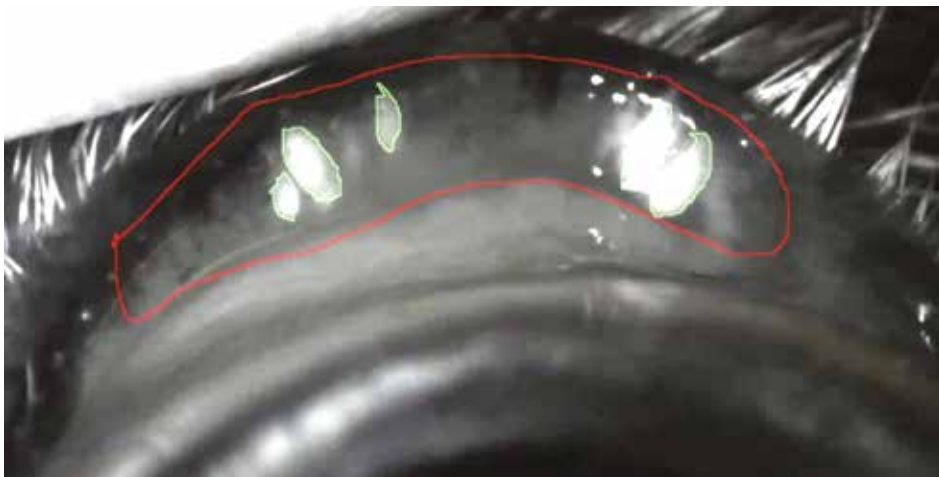
MGD with occlusion of the ductal openings and diffused glandular dropout.

MGs scoring system: meibo-score

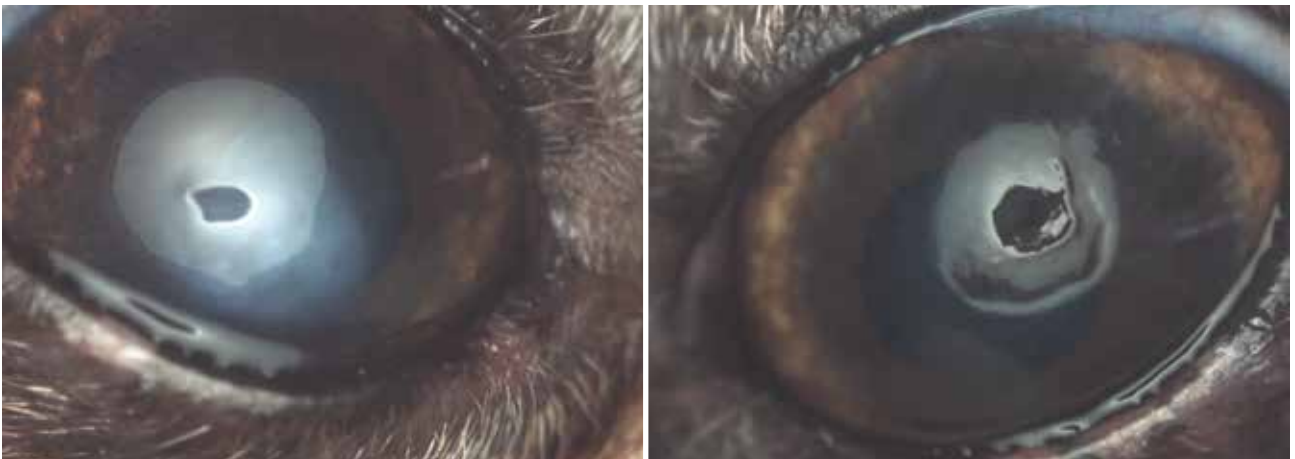

Right eye. Loss area (%): 77.



Left eye. Loss area (%): 79.

Interferometry



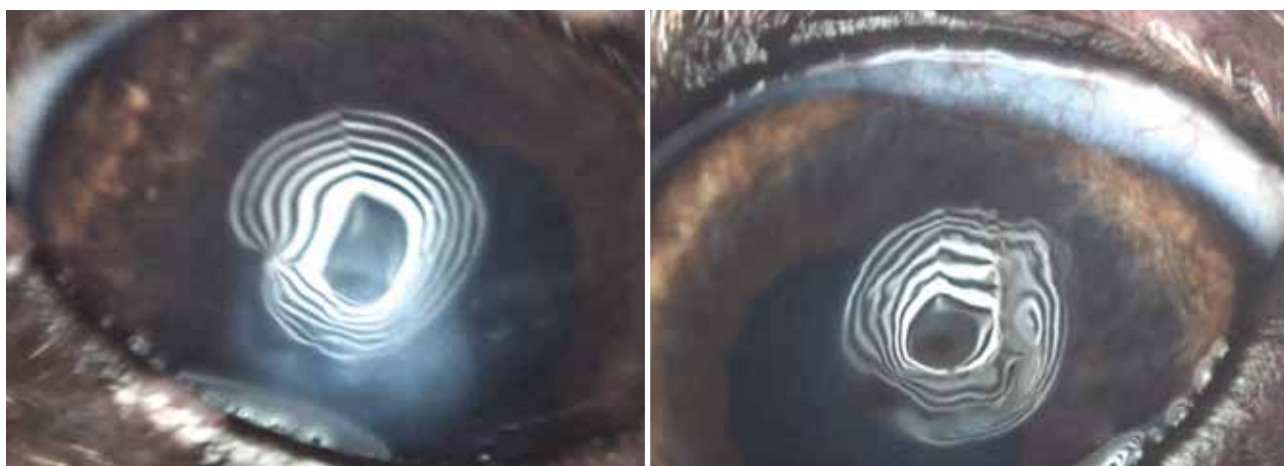
TF LL: grade 1 OU (VGS) with irregular shapes in the altered corneal quadrants.

NIBUT



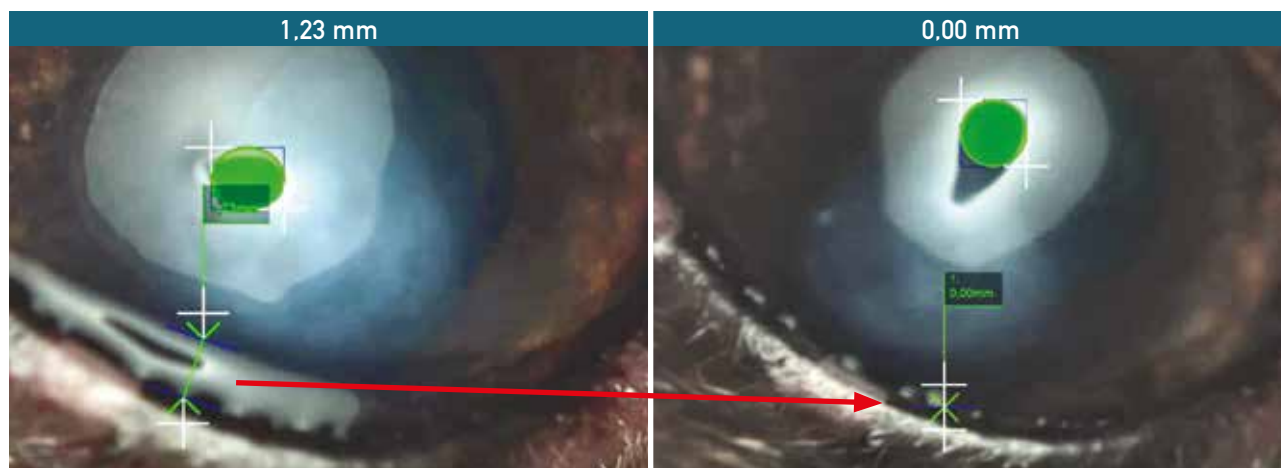
NIBUT: untestable OU = 0. TF LL always broken in the altered corneal quadrants.

Placido disc topography

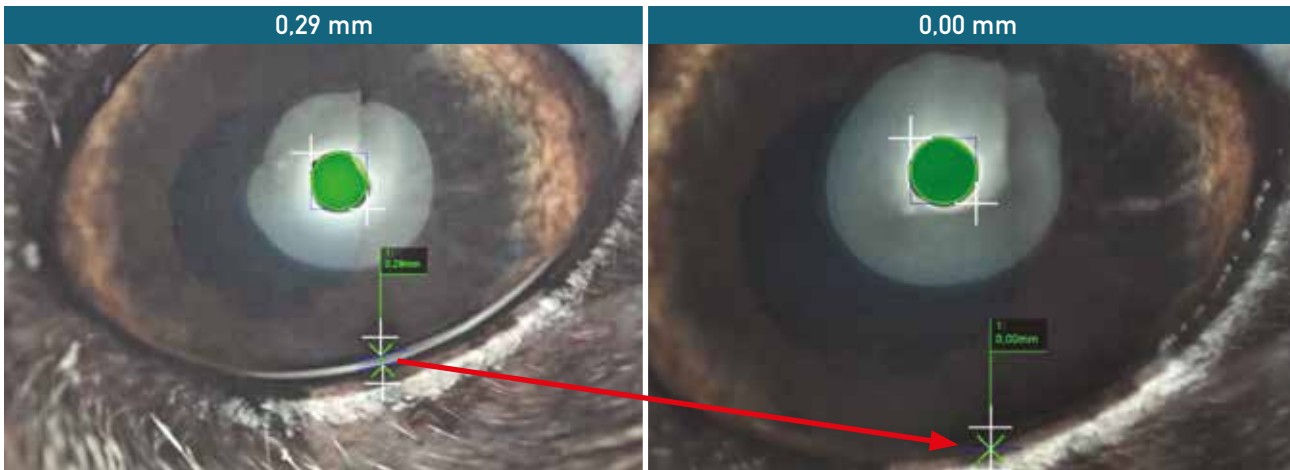


OST: irregular in the ventral quadrant (right eye) and in the dorsal quadrant (left eye).

TMH



Right eye. From 1.23 mm to 0,00 mm.



Left eye. From 0,29 mm to 0,00 mm.

The TMH changes continuously. At each complete blink tears are flushed outside the meniscus to immediately accumulate while a sequence of several incomplete blinks takes place.

Diagnosis

Corneal defects and loss of wettability, MGD with qualitative dry eye, increased TF evaporation and compensatory increased lacrimation.

In short: MGD, QDE, corneal defects, EDE.

Authors: Benjamin Reynolds, Cameron Whittaker, Kelly Caruso & Jeffrey Smith



Case 6 – Cloudy eyes with interstitial keratitis

Dog: Dachsund X, male neutered, 14 years old

Patient on initial presentation, note after fluorescein staining and prednefrin forte ophthalmic drop instillation.

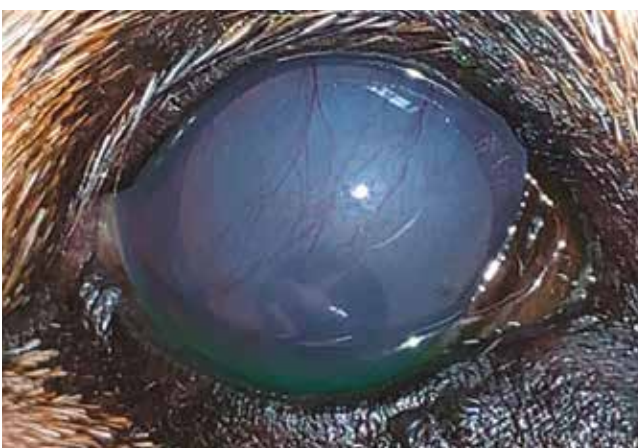Clinical history

The owner reported that for the past 4 months both eyes have appeared sore, with the dog squinting both eyes and having a red conjunctiva. Throughout this time, both eyes have appeared cloudy, moreso in the right eye than the left. No treatment was offered by other veterinary surgeons and was referred for assessment.

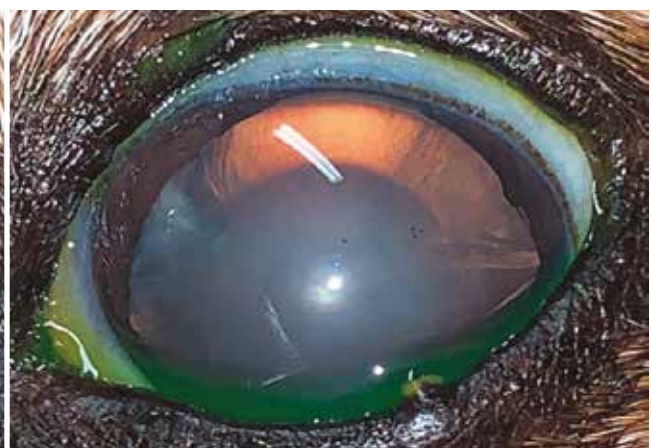Clinical signs at presentation

Interstitial keratitis was diagnosed with no known origin, with a stromal vascular infiltrate with diffuse mild corneal edema, with the right eye worse affected than the left.

As no cause for the keratitis was identified, topical ophthalmic steroids were trialed in both eyes twice daily. The degree of keratitis was unimproved over the next month.



Right eye on presentation, with moderate diffuse corneal edema and non-ulcerative keratitis.



Left eye on presentation, with mild diffuse corneal edema and non-ulcerative keratitis.

Key data after a complete ophthalmic examination

STT

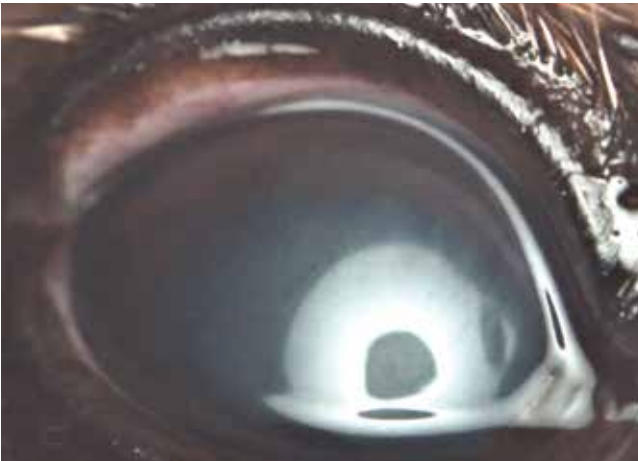- Left eye > 15 mm/minute
- Right eye > 15 mm/minute

Fluorescein Breakup time

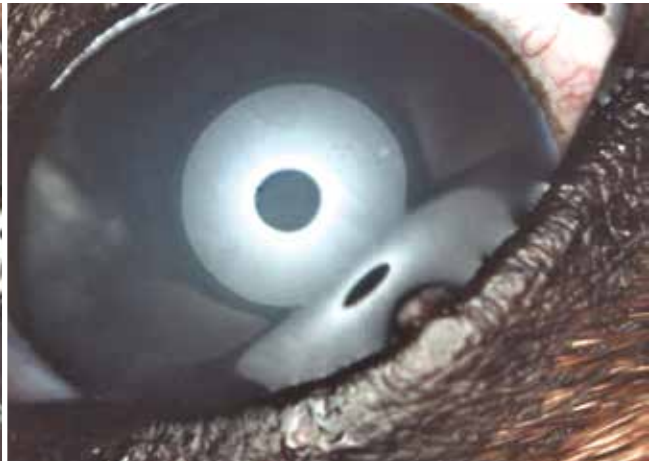
- < 1 second OU

Mild fluorescein stippling diffusely over the entire corneal surface

Interferometry

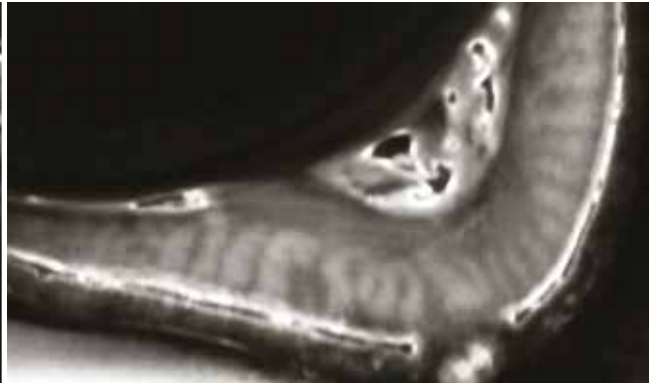
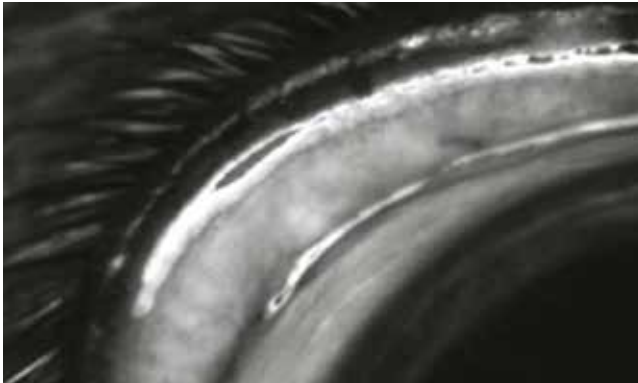

Right eye: < 15 nm lipid layer thickness.

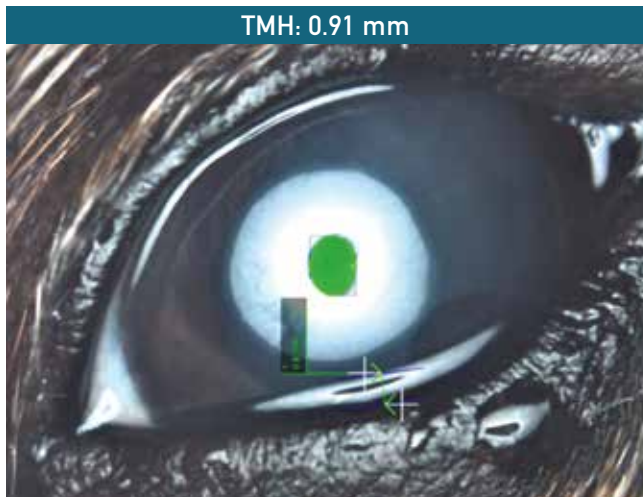


Left eye: < 15 nm lipid layer thickness.

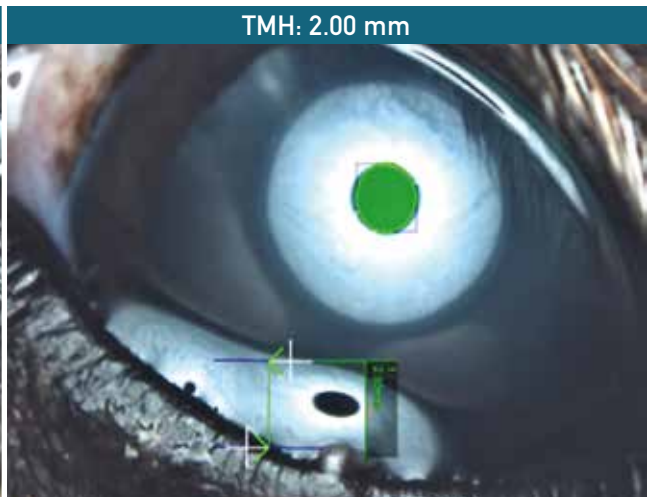
Meibography



Areas of chalazia and MGD present on all eyelids.



TMH: 0.91 mm



TMH: 2.00 mm

Both eyes displayed copious aqueous tear production.

Diagnosis

Qualitative lipid-deficient dry eye due to meibomian gland dysfunction with associated stromal keratitis. The deficiency of lipid in the tear film increases tear evaporation and causes diffuse epithelial damage. The diffuse mild corneal edema occurs from poor epithelial barrier function and the neovascularization occurs due to the poor tear quality unable to offer the corneal epithelium adequate nutrients.

Authors: Gustavo A. García, Alina Hernández



Case 7 – Meibomian gland dysfunction (MGD)

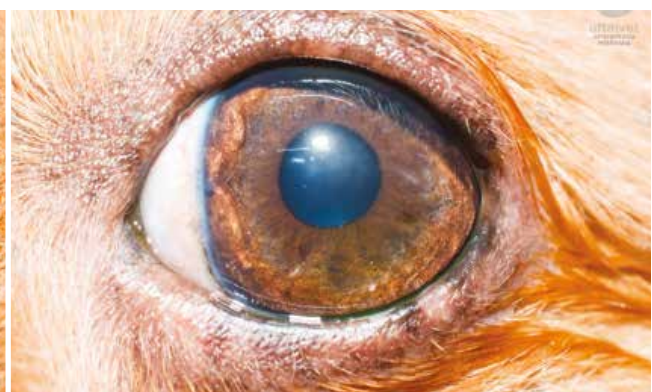
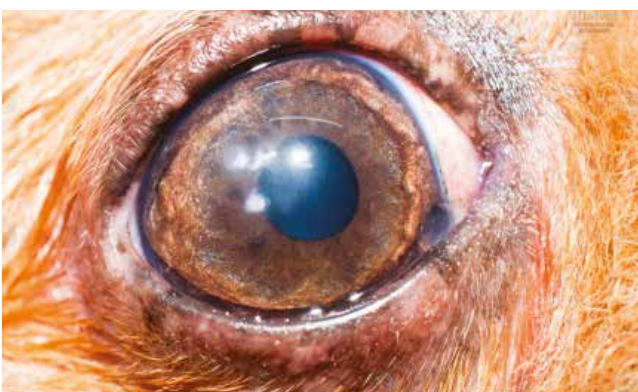Dog: Pomeranian, female, 6 years old

Clinical history

The owners report that since 5 months the dog has constant ocular tearing in both eyes, and she does not scratch the eyes.

Clinical signs at presentation

Both eyes are constantly wet. White spots on both eyes.



Key data after a complete ophthalmic examination

Values:

STT

- Right Eye: 27 mm/min
- Left Eye: 25 mm/min

Fluorescein and Jones Test: negative OU.

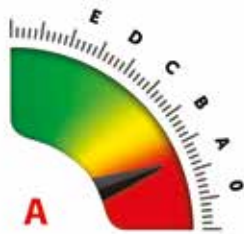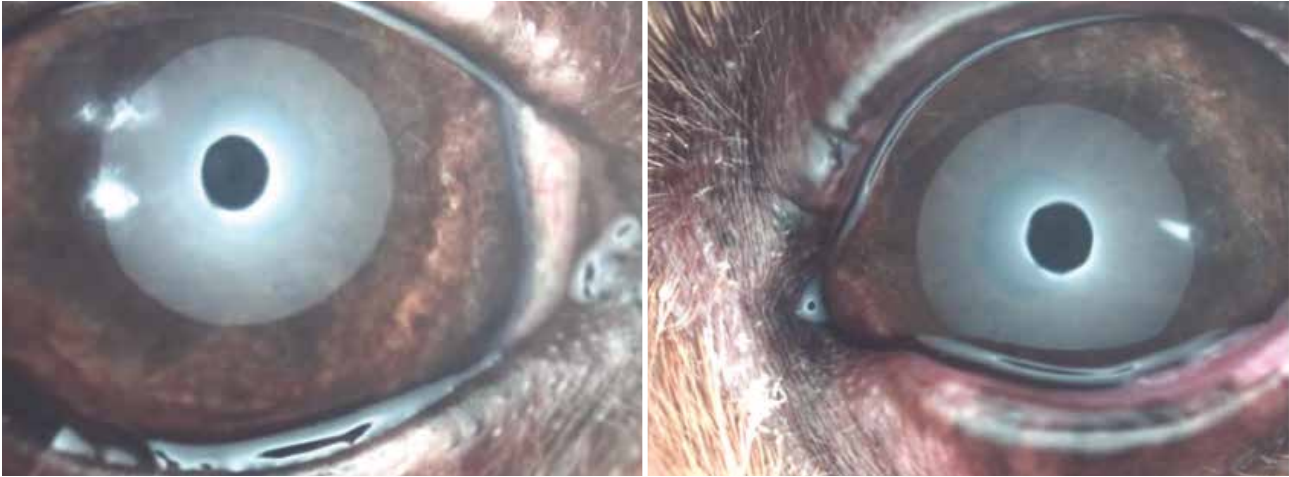
Intraocular pressure:

- Right Eye: 13 mmHg
- Left Eye: 15 mmHg

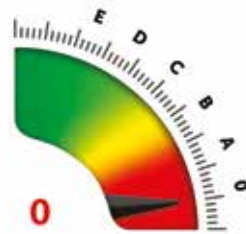Interferometry

Estimated lipid layer thickness

- Right eye: 30 nm
- Left eye: 30 nm



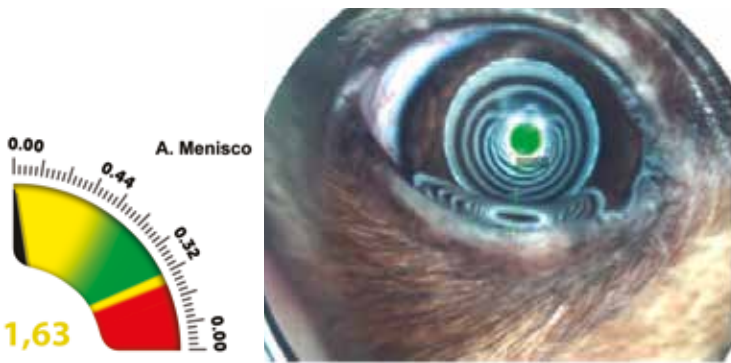
Tipo de capa lipidica



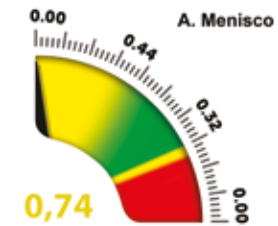
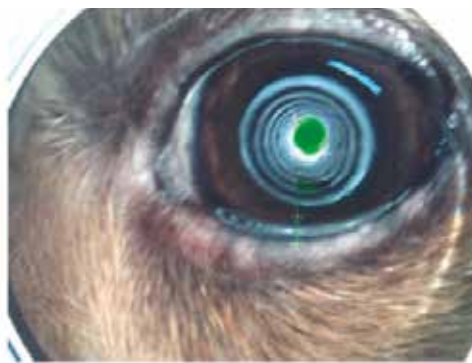
Tipo de capa lipidica

OS topography and TMH

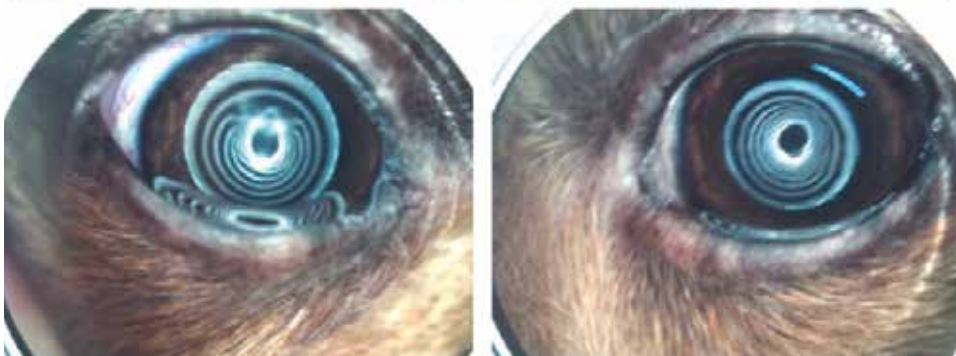
Irregular topography in the areas with white spots OU.



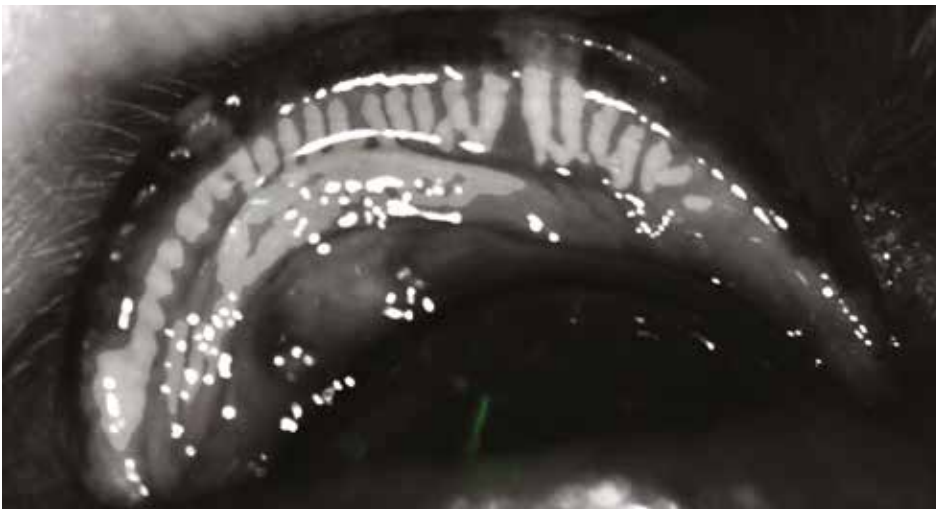Altura de Menisco lagrimal (mm): 1,63 mm



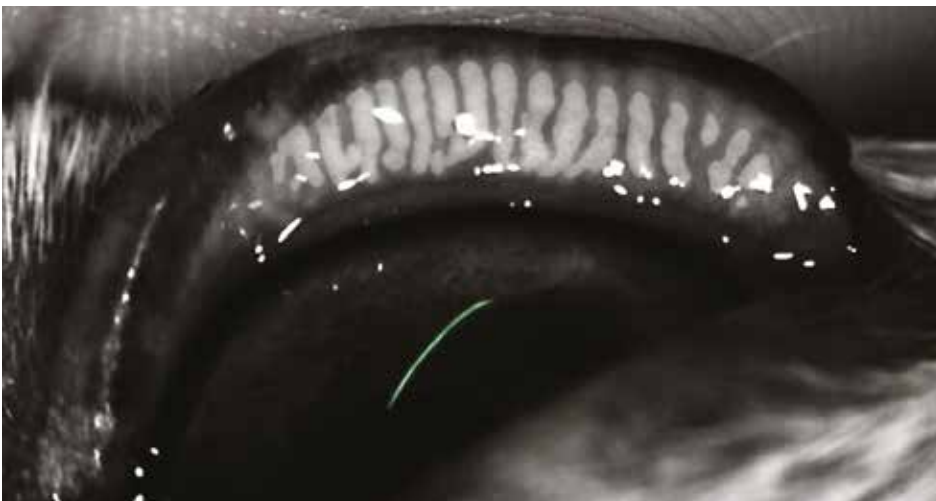
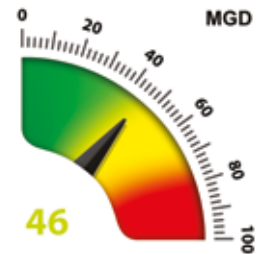Altura de Menisco lagrimal (mm): 1,63 mm



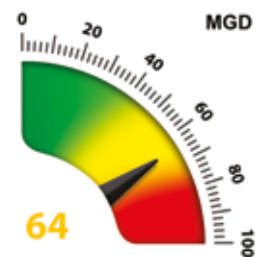Meibography and meiboscore



Right Eye: 46% loss



Left Eye: 64% loss



Tear meniscus height

- Right Eye: 1,63 mm
- Left Eye: 0.74 mm

NIBUT

- Right Eye: 10 sec
- Left Eye: 9.2 sec

Diagnosis

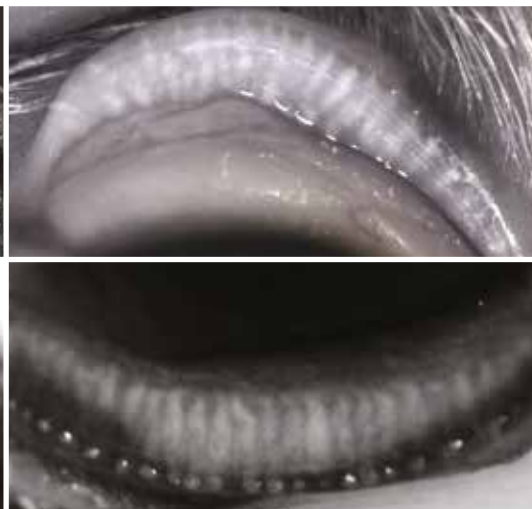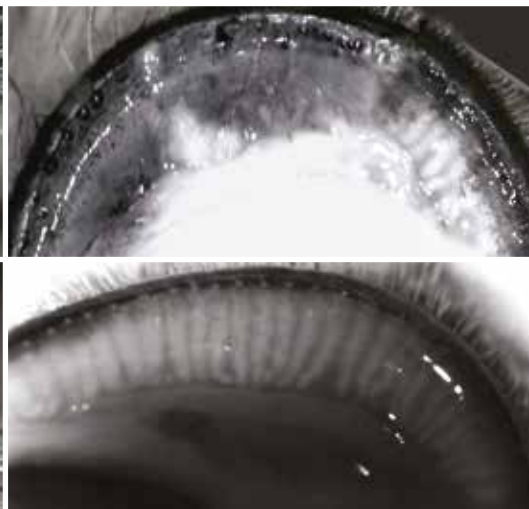
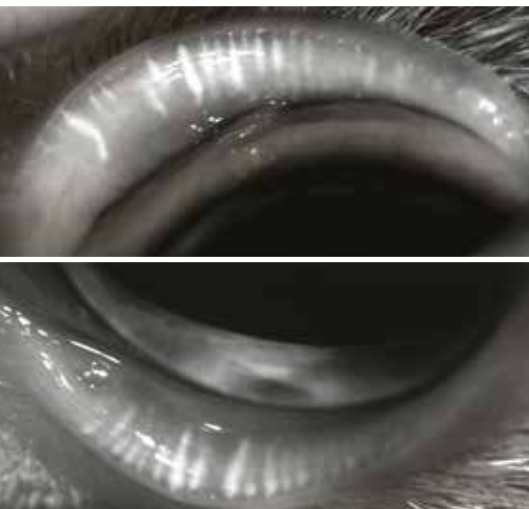Increased tear film evaporation due to loss of wettability in areas of corneal fibrosis.
 Consistent loss of meibomian glands and thin lipid layer.
 Compensatory increase of tear production and wet eyes.

In short: LOSW, EDE.

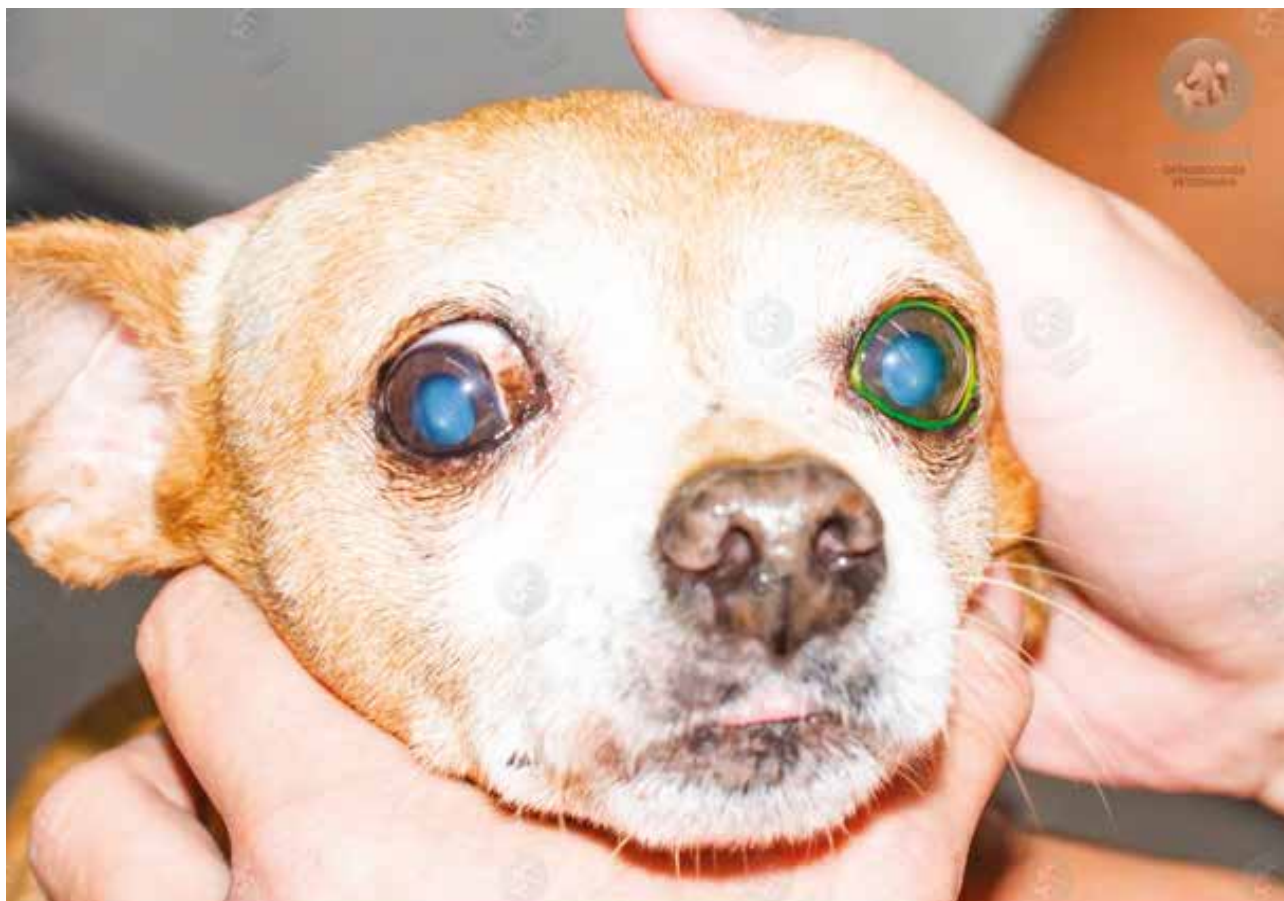

 **o.s.a. vet**

**Noncontact Infrared
Meibography to examine
meibomian glands.**



Authors: Gustavo A. García, Alina Hernández



Case 8 – Evaporative Dry Eye

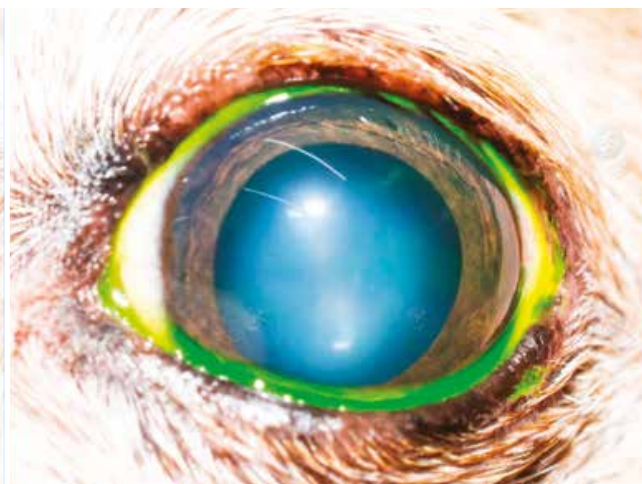
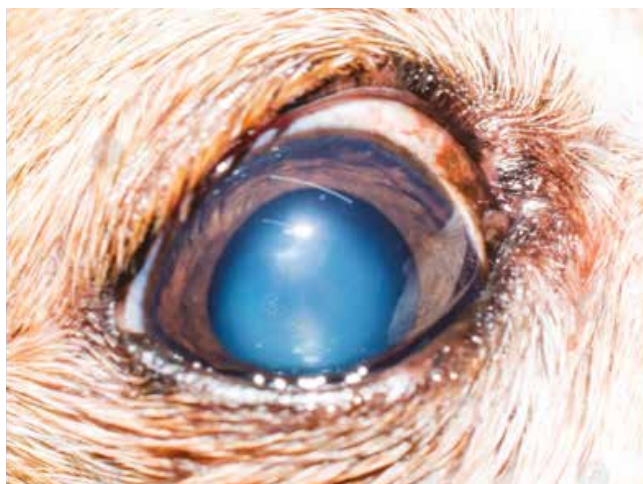
Dog: Chihuahua, female, 4 years old

Clinical history

Since six or seven months, the owners have noticed that both eyes show intense tearing, sometimes the eyes are red and the eyelids are inflamed.

Clinical signs at presentation

Excessive tearing.
She constantly scratches both eyes.



Key data after a complete ophthalmic examination

Values:

STT

- Right Eye: 29 mm/min
- Left Eye: 24 mm/min

Fluorescein and Jones Test: negative in both eyes.

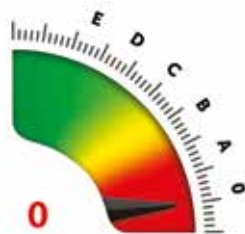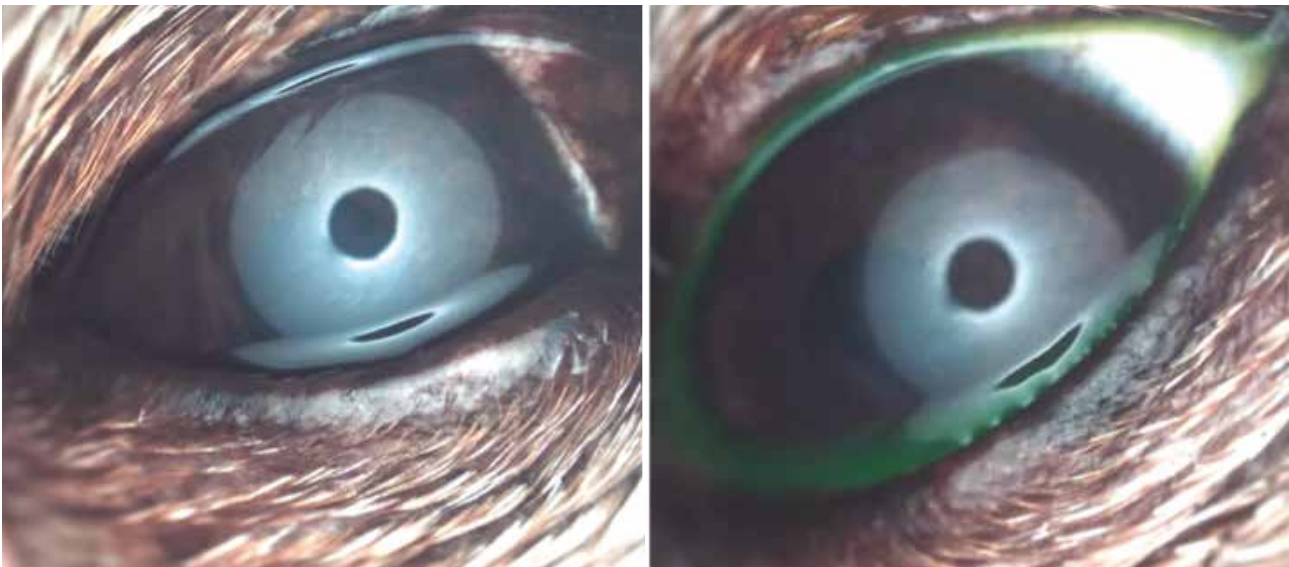
Intraocular pressure:

- Right Eye: 16 mmHg
- Left Eye: 13 mmHg

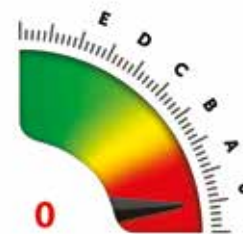Interferometry

Estimated lipid layer thickness

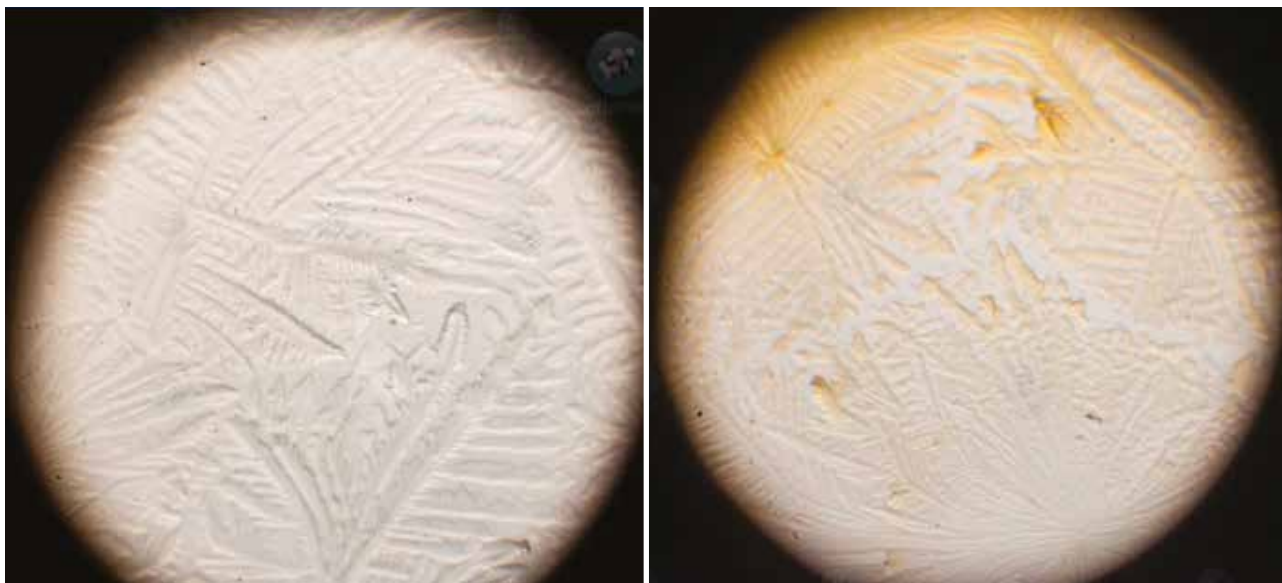- Right eye: 30 nm
- Left eye: 30 nm



Tipo de capa lipidica

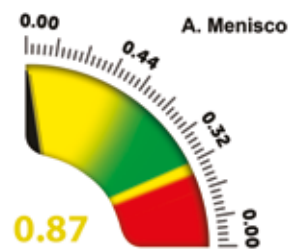
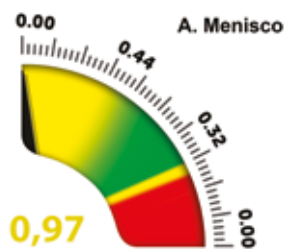
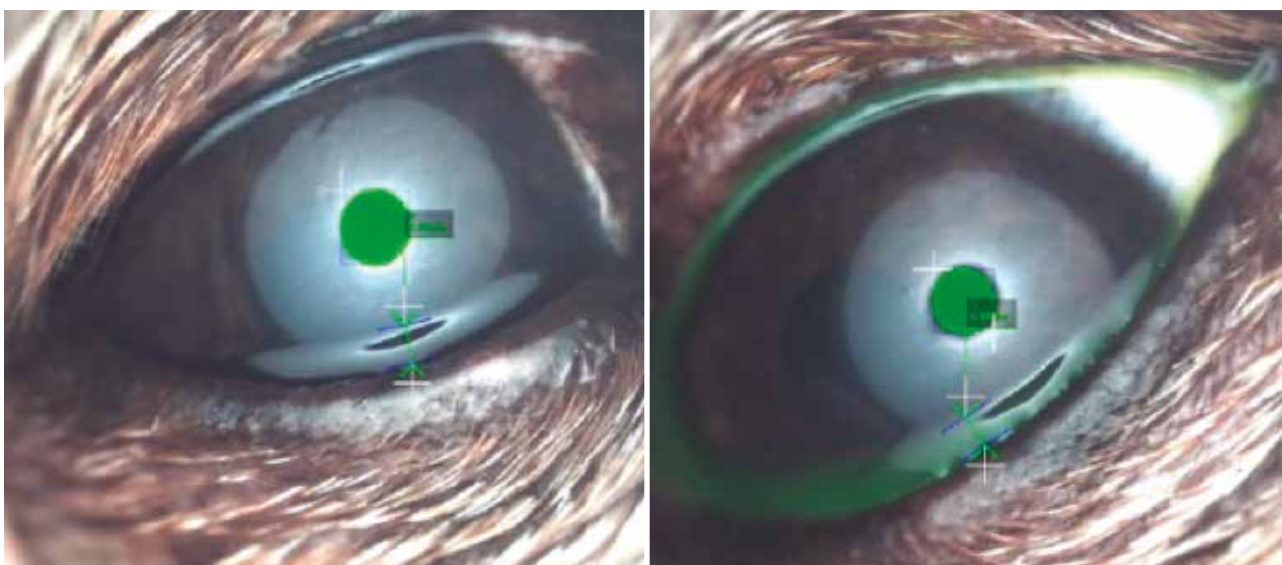


Tipo de capa lipidica

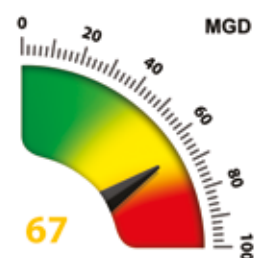
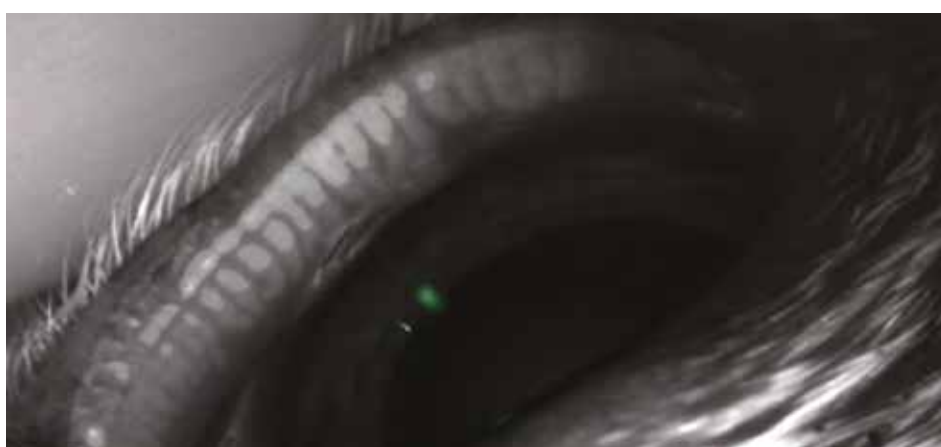
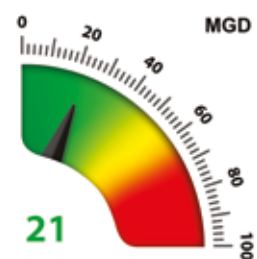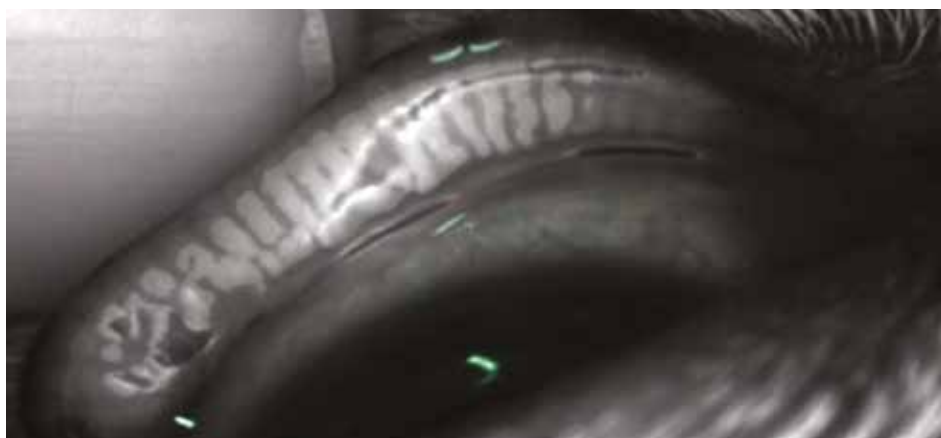Ferning Test: Grade II (Williams D. and Hewitt H. 2017).

TMH



Meibography and meiboscore



Tear meniscus height

- Right Eye: 0,97 mm
- Left Eye: 0,87 mm

Meiboscore

- Right Eye: 21% loss
- Left Eye: 67% loss

Diagnosis

Increased tear film evaporation, consistent loss of meibomian glands and thin lipid layer. Compensatory increase of tear production and wet eyes.

In short: LOSW, EDE.

Author: Akihiko Saito



Case 9 – Both eyes underwent corneal autologous transplantation and modified medial canthoplasty

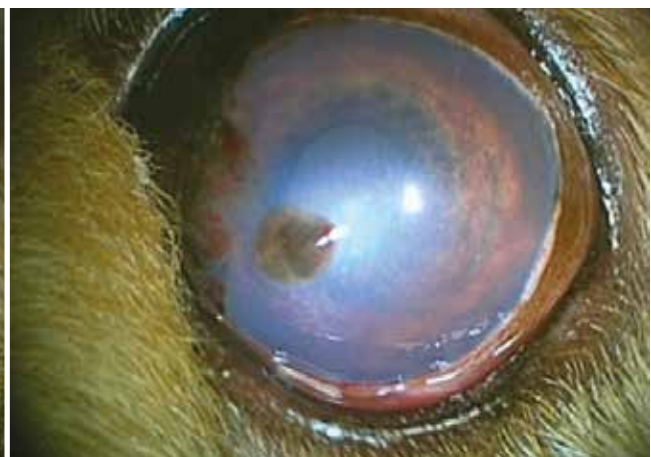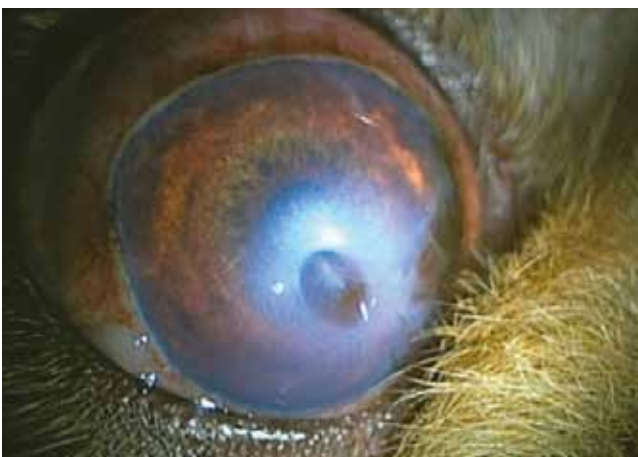Dog: Pekingese, male, 6 years old

Clinical history

The ocular surface examination is carried out two years and 9 months after a corneal autologous transplantation for the treatment of a corneal ulcer.

Clinical signs at presentation

Corneal transparency had improved.



Key data at first presentation

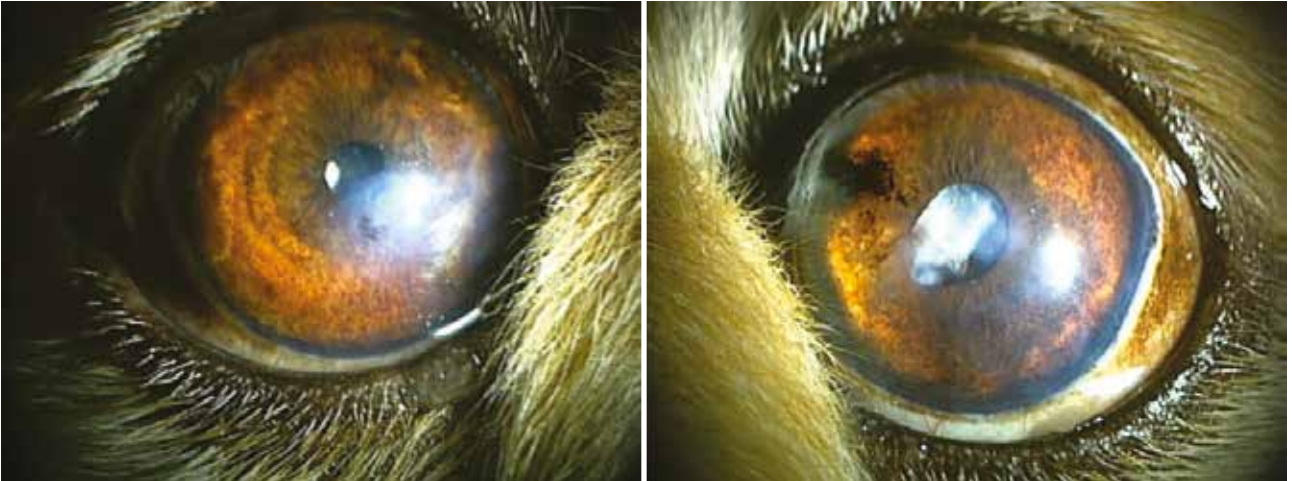PRTT

- OD: 30 mm/15 sec
- OS: 43 mm/15 sec

STT

- OD: 21 mm/min
- OS: 16 mm/min

2 years after surgery

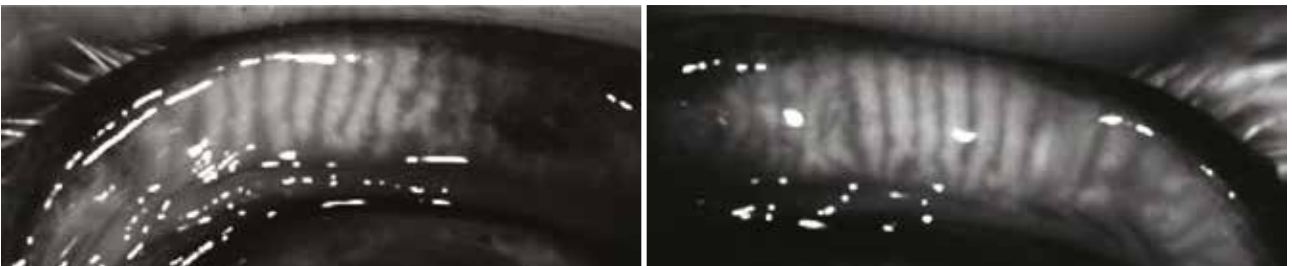

Topography



Topography of the transplanted area was almost normal in the right eye and nearly circle shaped in the left eye.

Meibography



Pigment can be seen on the medial sides of both eyelids as well as some meibomian gland dropout.

Author: Hiroko Iwashita



Case 10 – Severe epiphora

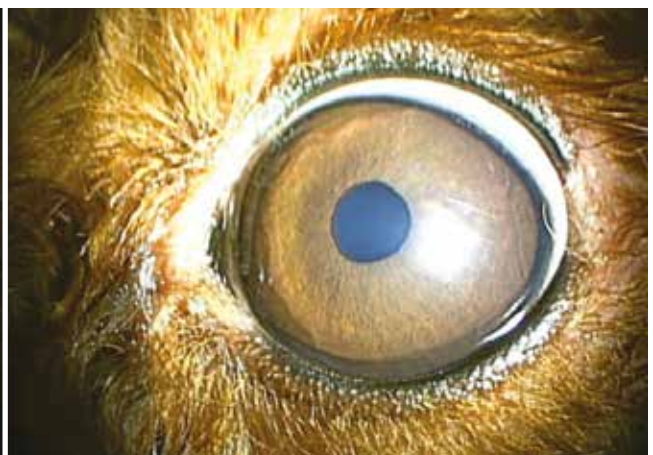
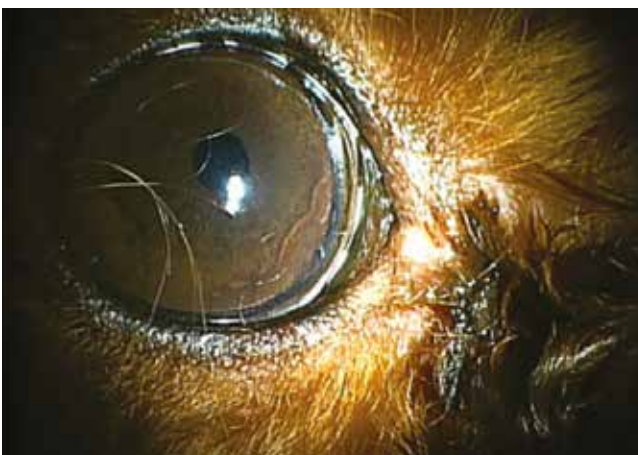Dog: Toy poodle, female, spayed, 1 year old

Clinical history

The dog was presented to the animal eye clinic for constant severe epiphora in both eyes.

Clinical signs at presentation

There was a loss of hair around the lids and the area was very wet especially at the medial canthus.



Key data at first presentation

PRTT

- Right: 33 mm/15 sec
- Left: 36 mm/15 sec

SM

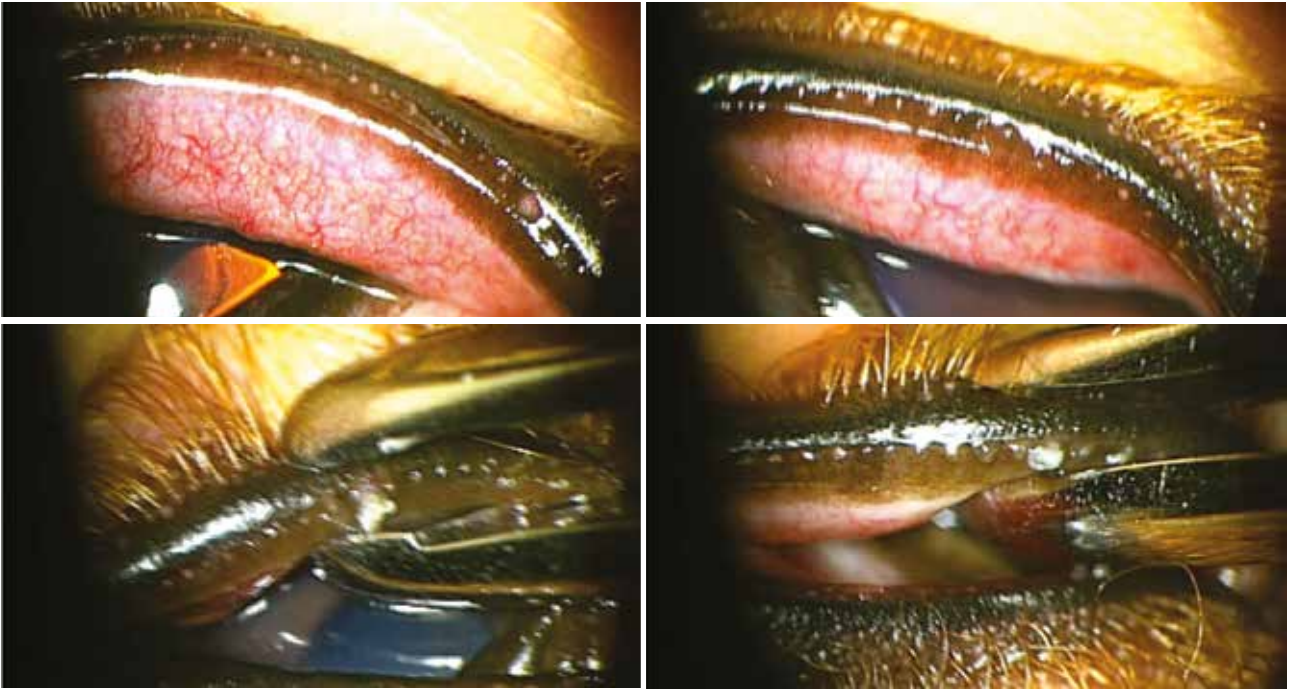- Right: 8 mm/5 sec
- Left: 8 mm/5 sec

STT

- Right: 17 mm/min
- Left: 8 mm/min

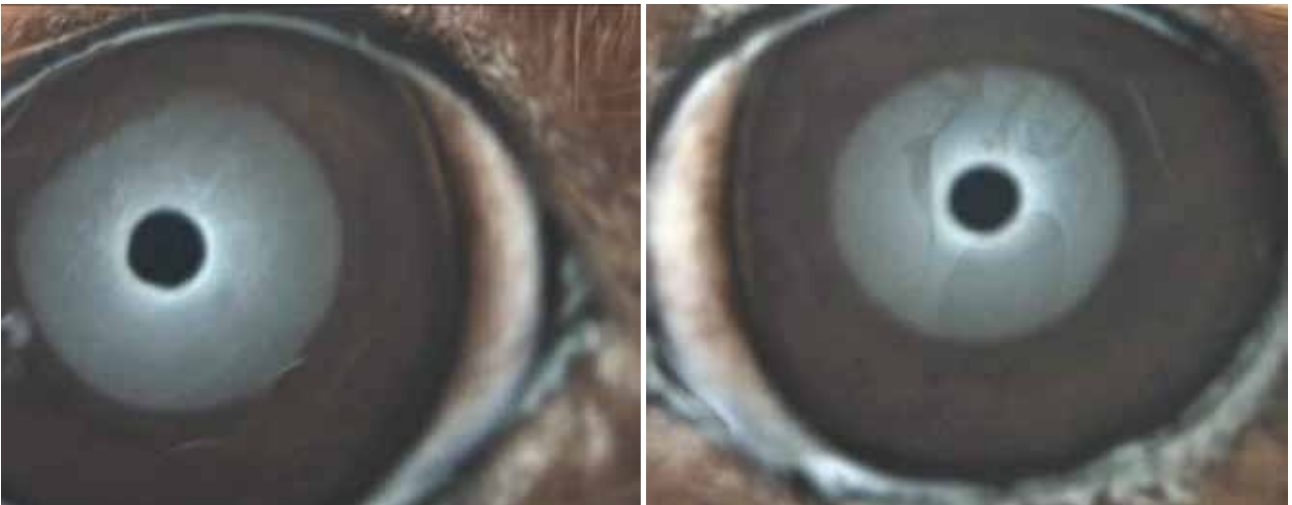Osmolarity (i.Pen@Vet)

- Right: 295 mOsm/L
- Left: 316 mOsm/L



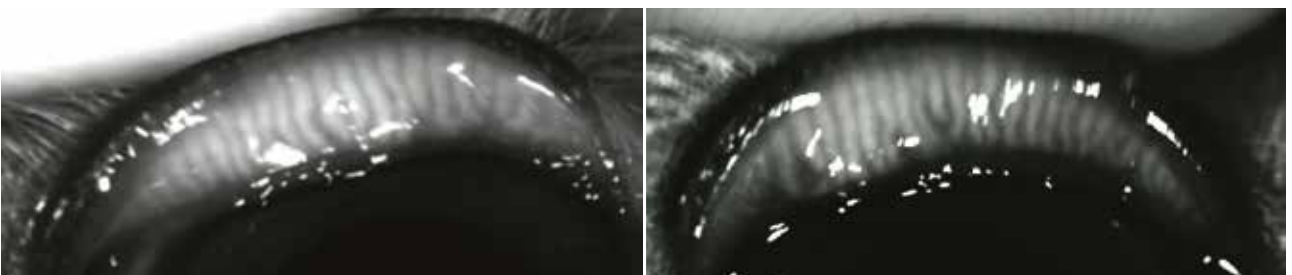
*Plugs were observed at the meibomian gland orifices.
When the lid was compressed a tooth-paste like meibum was observed.*

Interferometry



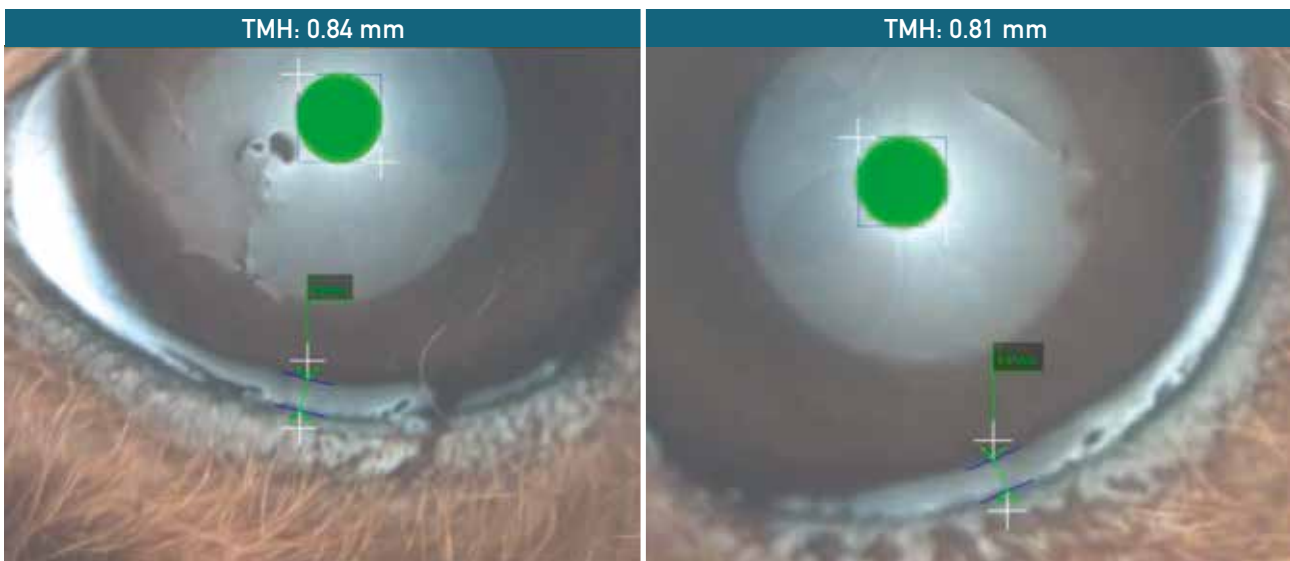
TF LL: 20-30 nm in both eyes.

Meibography



Meibomian glands were almost normal, and only a few were shortened.

TMH

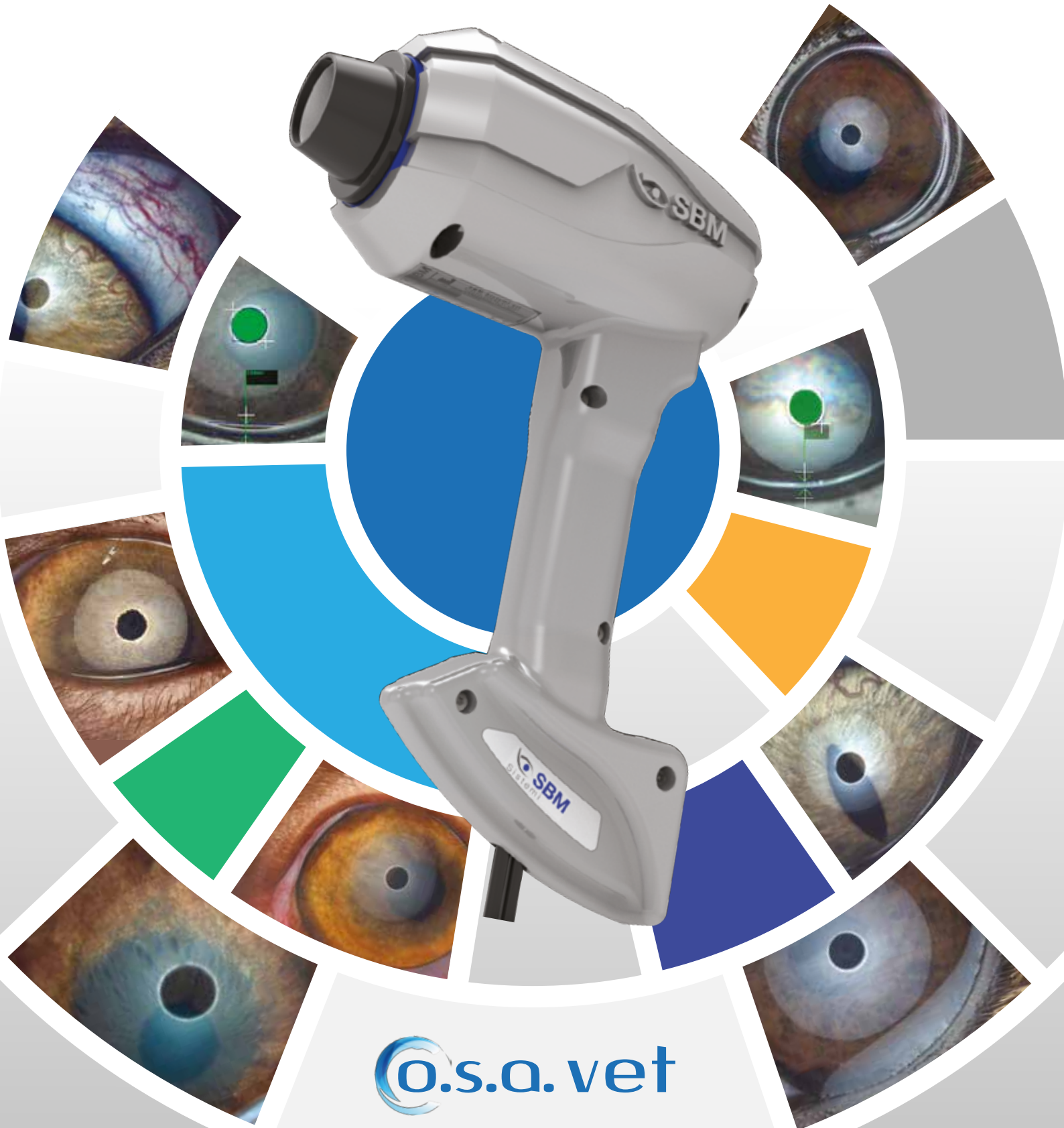

Both eyes displayed a high TMH.

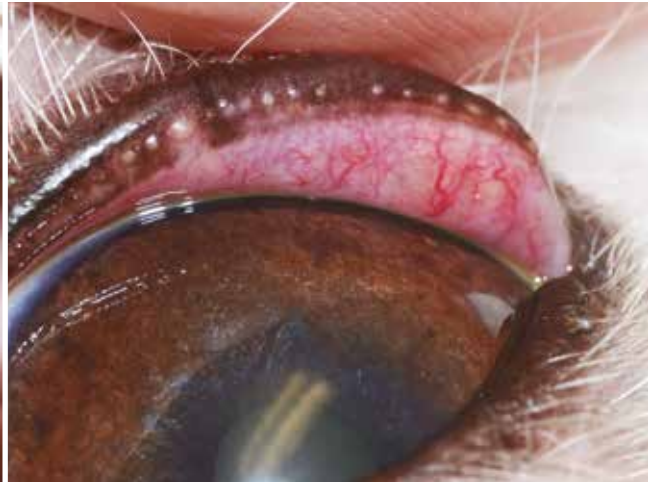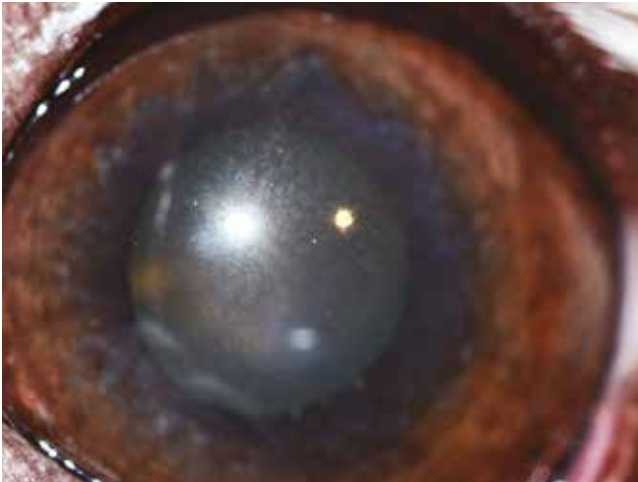
Diagnosis

Tear staining syndrome.

Interferometry to evaluate tear film lipid layer thickness, dynamics and tear meniscus height.



Authors: Federica Maggio, Stefano Pizzirani



Courtesy of Tufts Cummings School of Veterinary Medicine, North Grafton, Massachusetts.

Left eye, crystalline deposition.

Meibomianitis during active inflammation.

Case 11 – Mild corneal haziness and occasional squinting OU

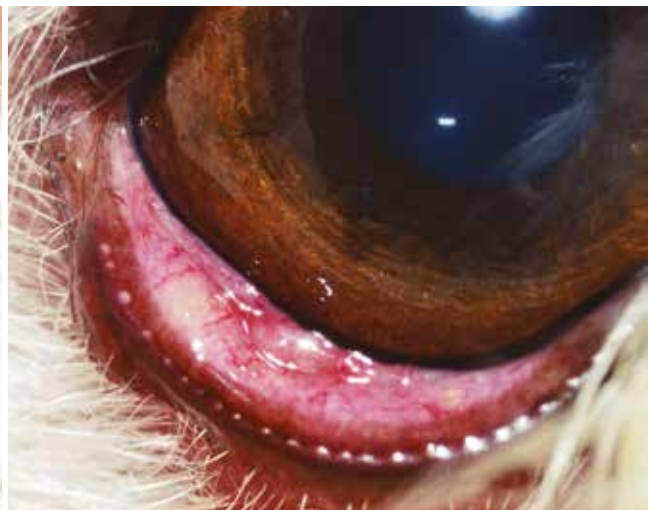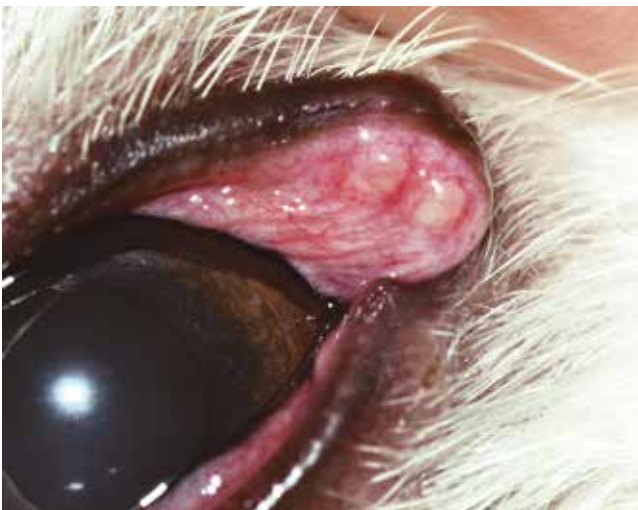Dog: Coton de Tulear, male castrated, 3 years old

Clinical history

The patient has been referred by a fellow ophthalmologist for assessment of the ocular surface by OSA. The dog had a two-year-long history of immunemediated meibomianitis and blepharitis, controlled on systemic immunosuppressants, although relapses have been frequent. Although recovered and well controlled on medications, the patient has been referred for assessment of mild bilateral corneal haziness and occasional squinting.

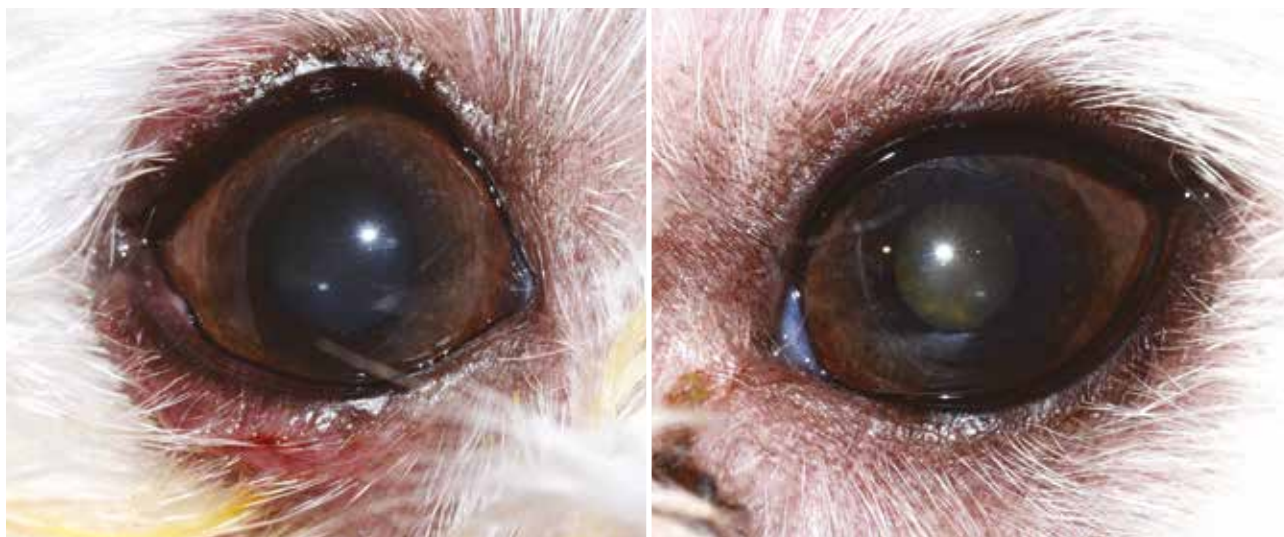
Clinical signs at presentation

At presentation, both eyes show rare, intermittent blepharospasm and faint central round crystalline deposition is present OU. Minor rounding of the eyelid margins is visible, and the rest of the ophthalmic examination is unremarkable.



Courtesy of Tufts Cummings School of Veterinary Medicine, North Grafton, Massachusetts.

Meibomian gland abscesses before treatment.



Courtesy of Tufts Cummings School of Veterinary Medicine, North Grafton, Massachusetts.

Post treatment.

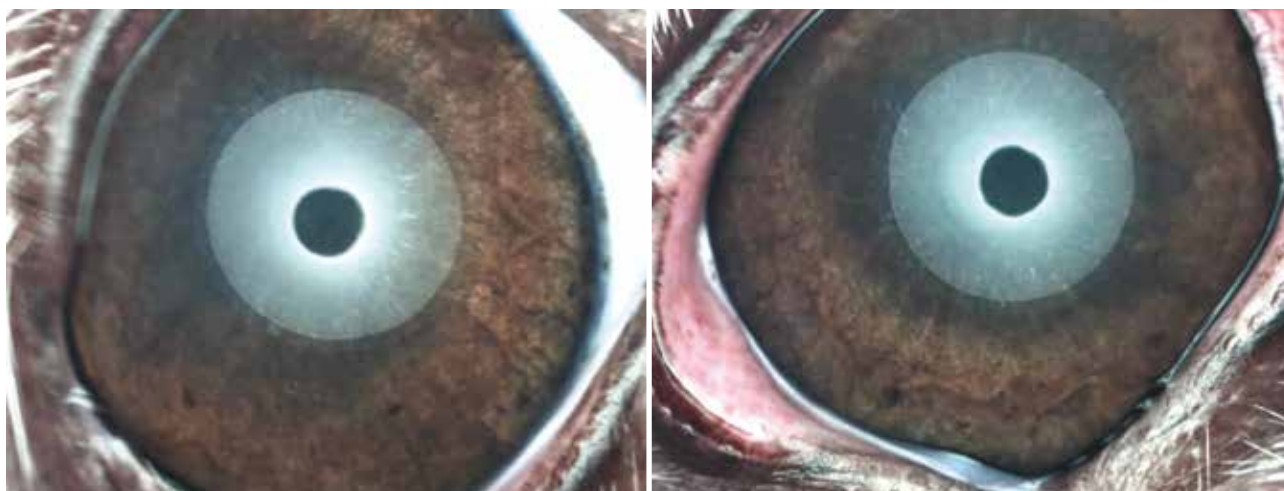
Key data after a complete ophthalmic examination

Inconsistent blepharospasm – Minor central corneal crystalline deposition – Minor rounding of eyelid rim.
STT

- Right eye 30 mm/min
- Left eye 35 mm/min

Fluorescein negative OU (mild central fluorescein stippling OU)

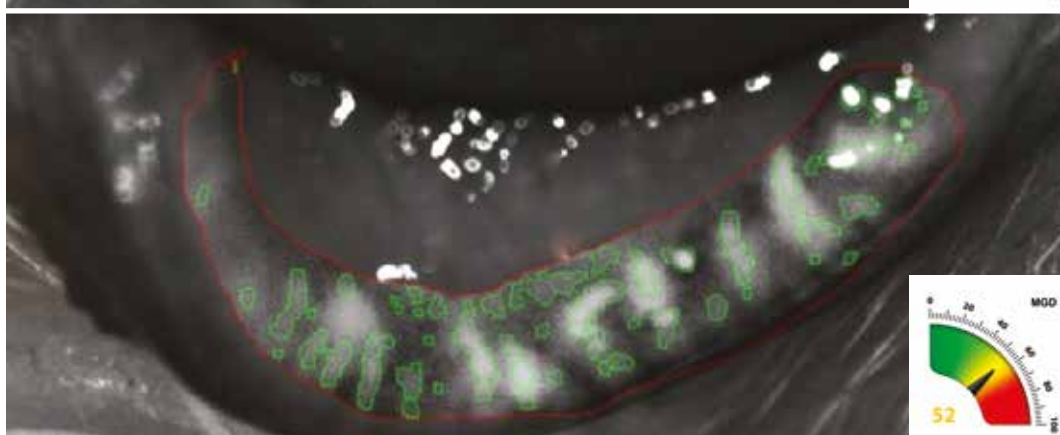
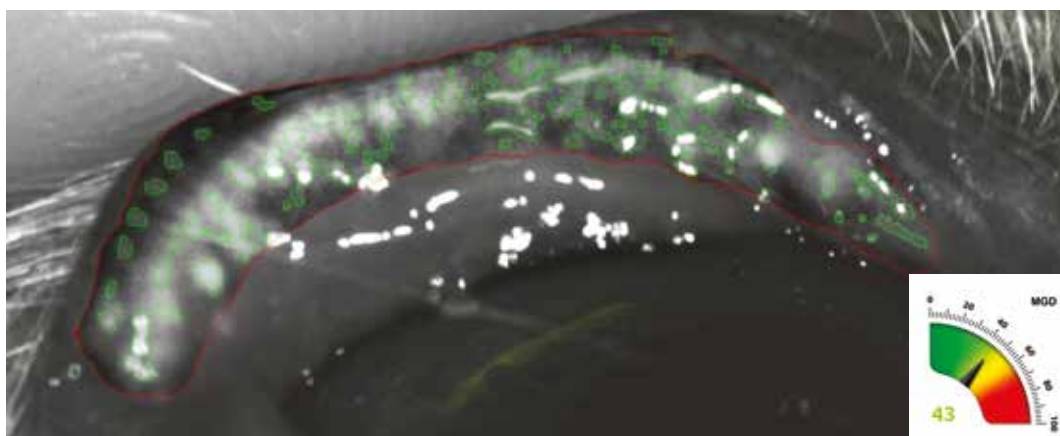
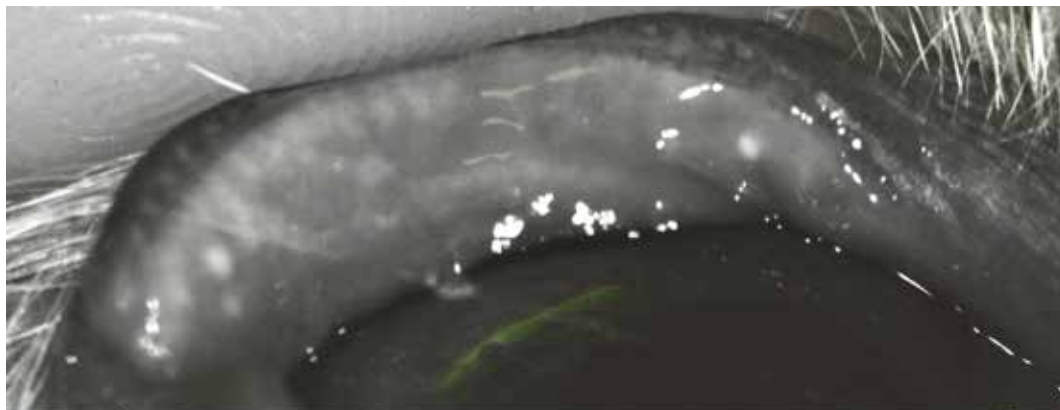
Interferometry



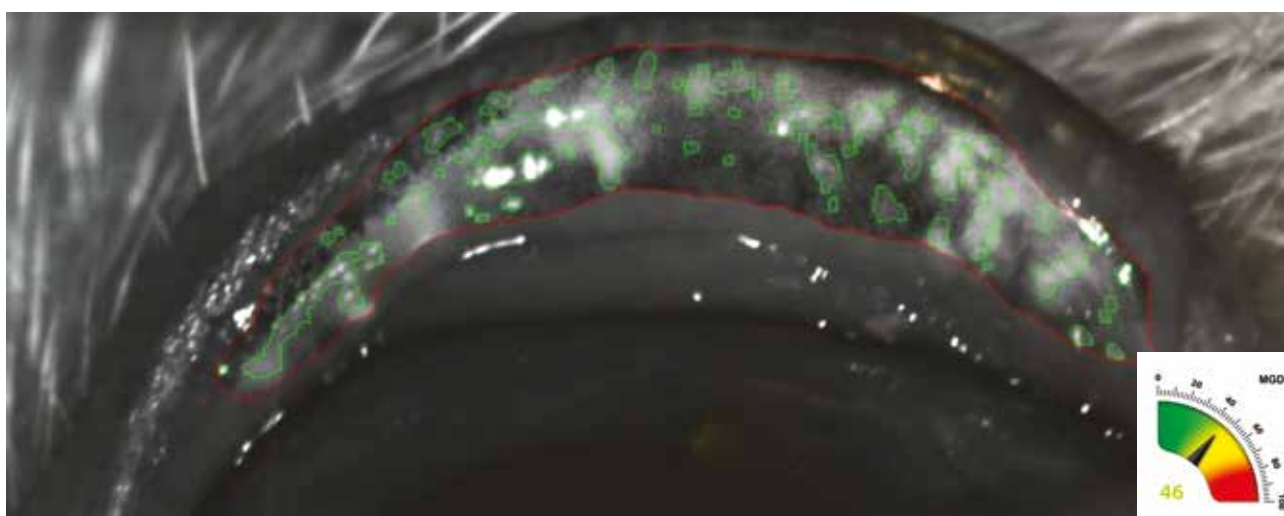
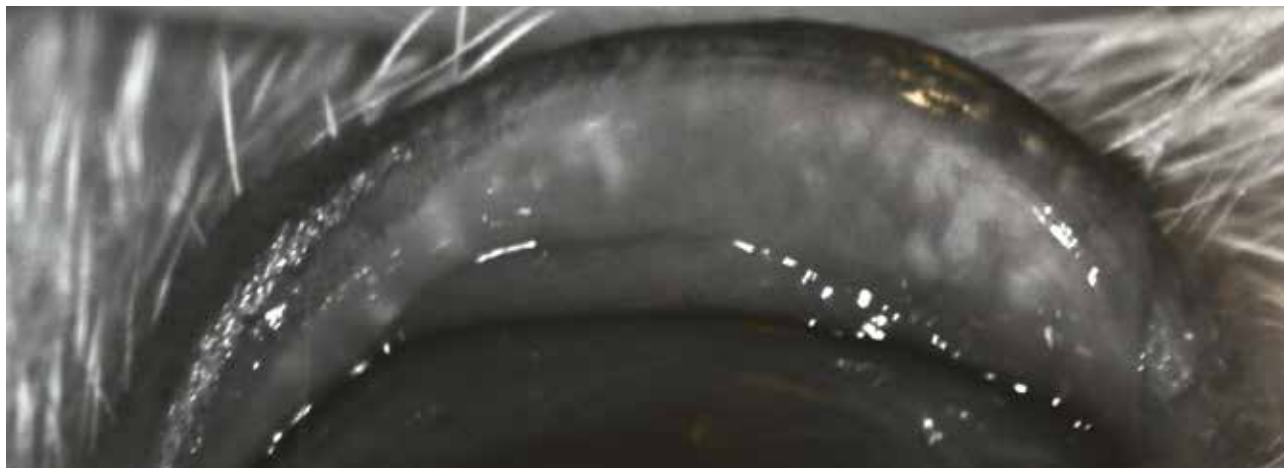
TF LL: 20-30 nm OU (grade 2 FGS).

Meibography

Right eye



Left eye



Diagnosis

Evaporative Dry Eye disorder, due to chronic damage of meibomian glands, with early corneal crystalline degeneration. The chronic damage from the immunemediated meibomianitis and blepharitis has significantly affected the lipid layer, with increased evaporation of the tear film and subsequent early central epithelial damage, with crystalline deposition.

In short: MGD, EDE.

Author: Ingrid Allgoewer



Case 12 – Chronic mucous discharge

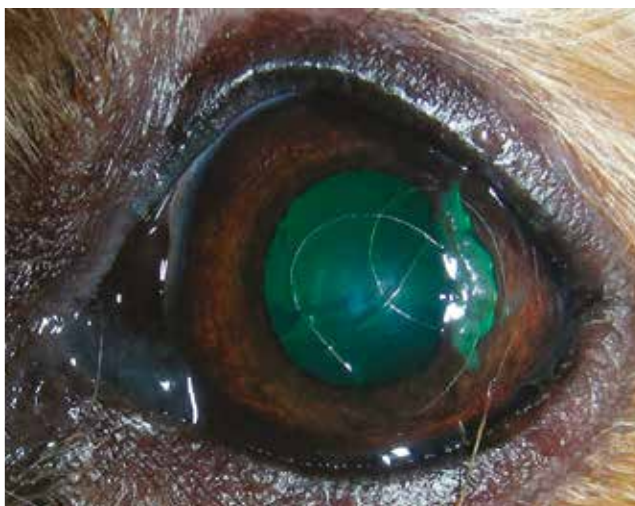
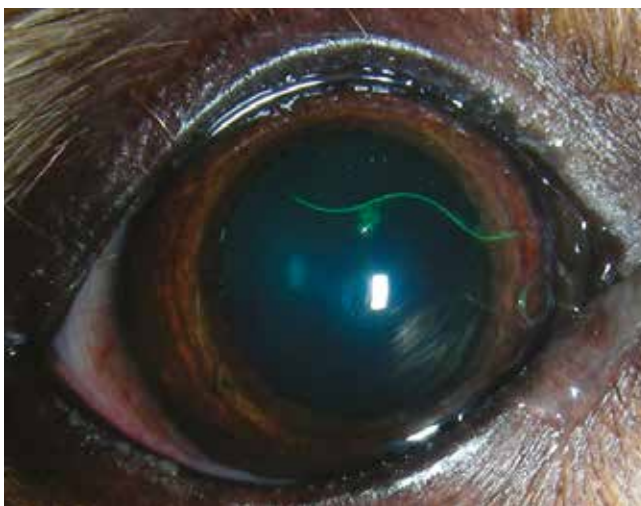
Dog: Norfolk Terrier, female, 3 years

Clinical history

Long standing mucoid discharge despite multiple topical therapies

Clinical signs at presentation

Debris and hairs on corneal center, mucous discharge, swollen lid with prominent MGs openings.



Key data after a complete ophthalmic examination

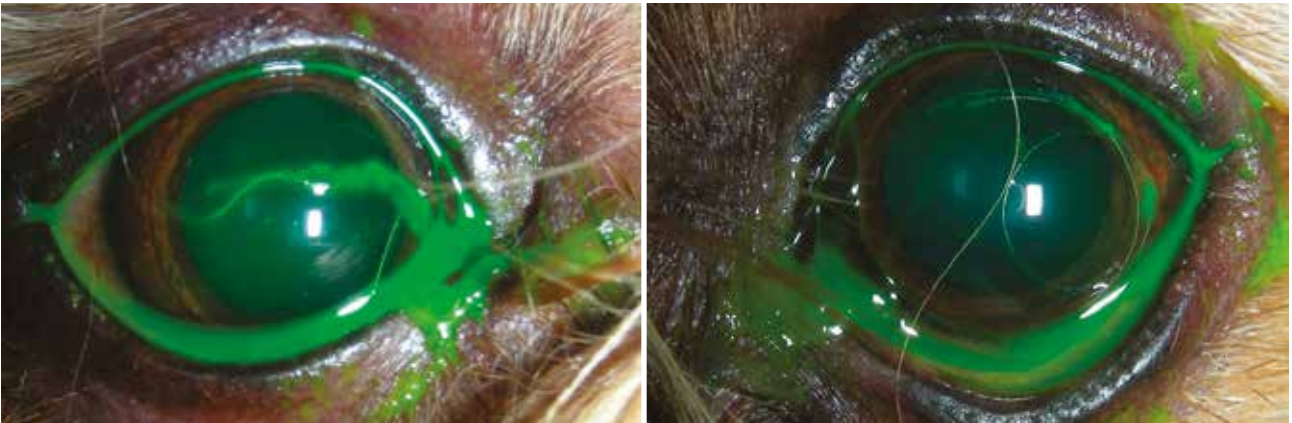
Blinking: 6 complete /17 incomplete blinks/min OS, 4 complete/10 incomplete blinks/min OD.

Fluoresceine and lissamine staining diffusely positive, multiple punctate areas.

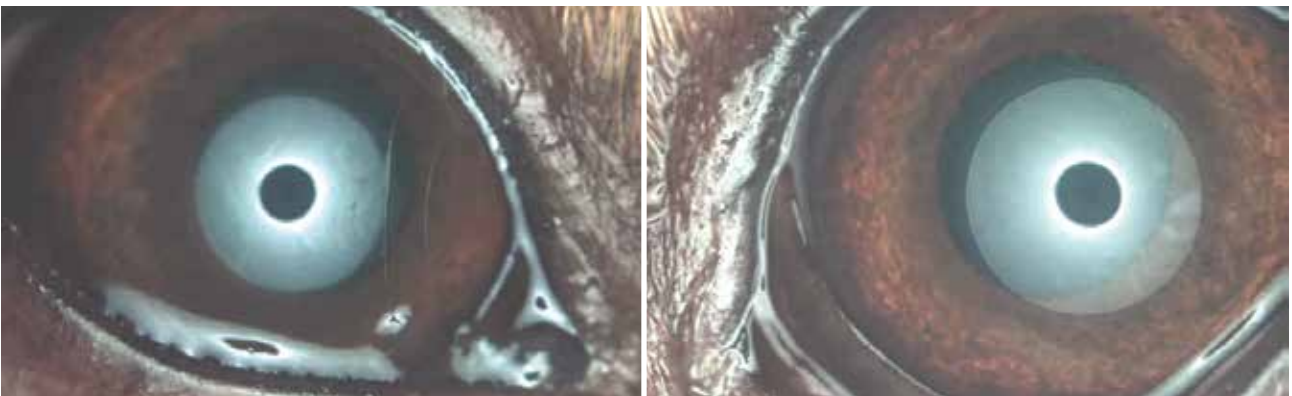
STT: 20mm/min OU.

Blockage of MGs openings.

Fluoresceine test

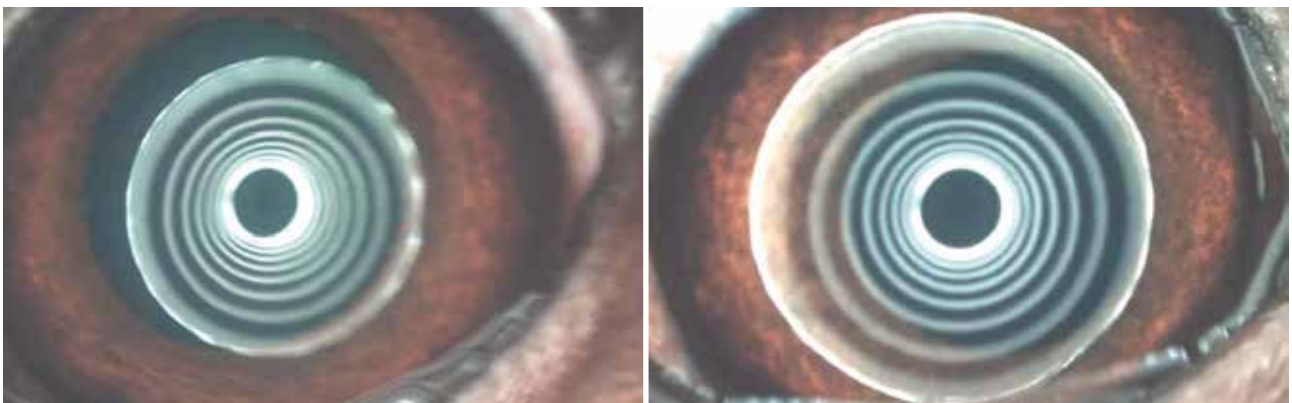


Interferometry



Thin and irregular TFL: 15 nm, no lipid waves visible.

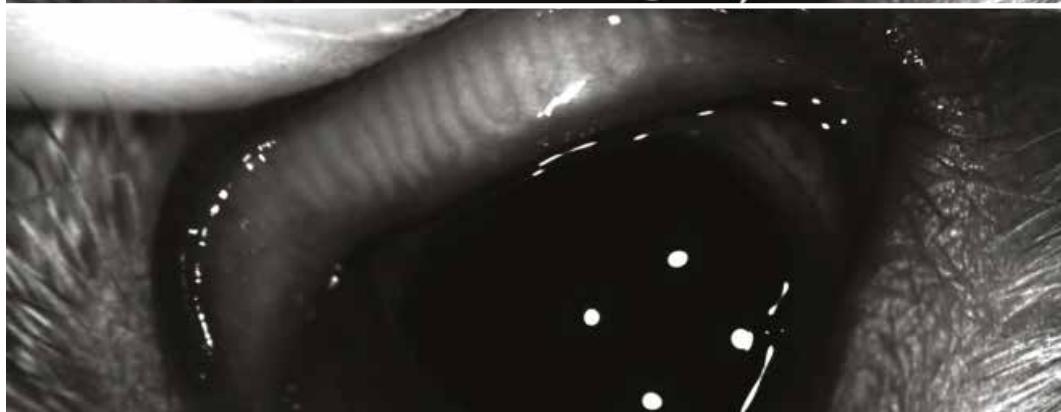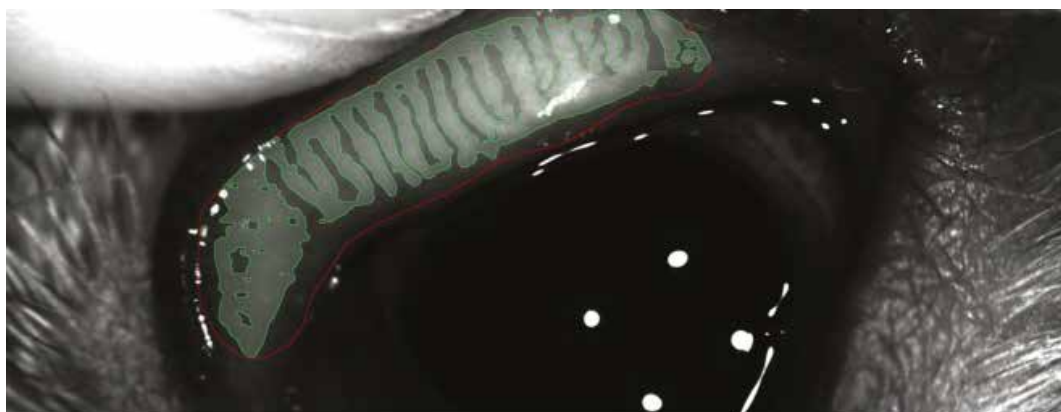
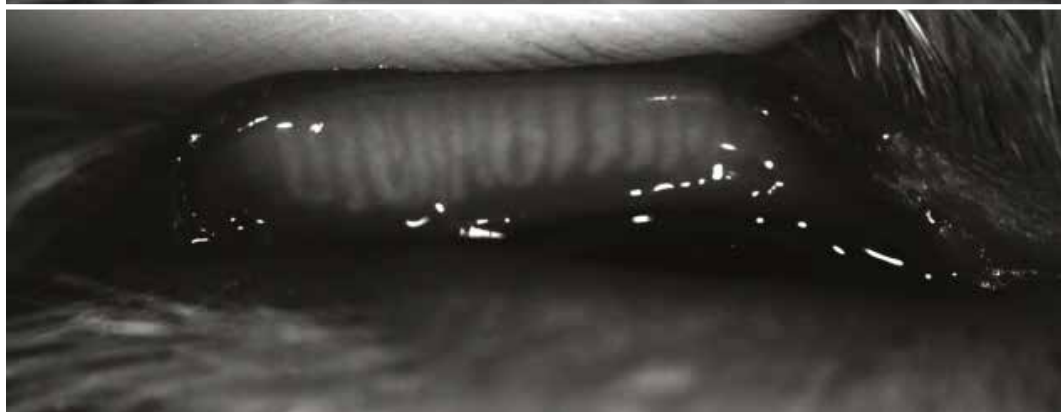
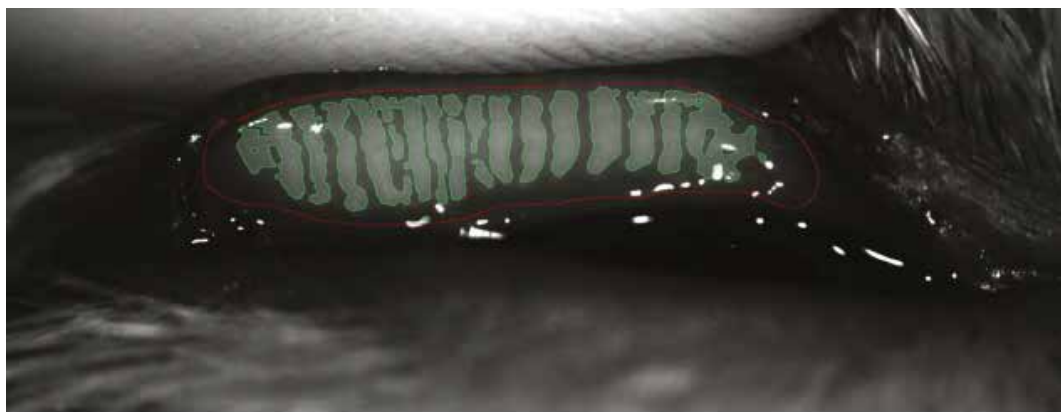
NIBUT



4.8 sec

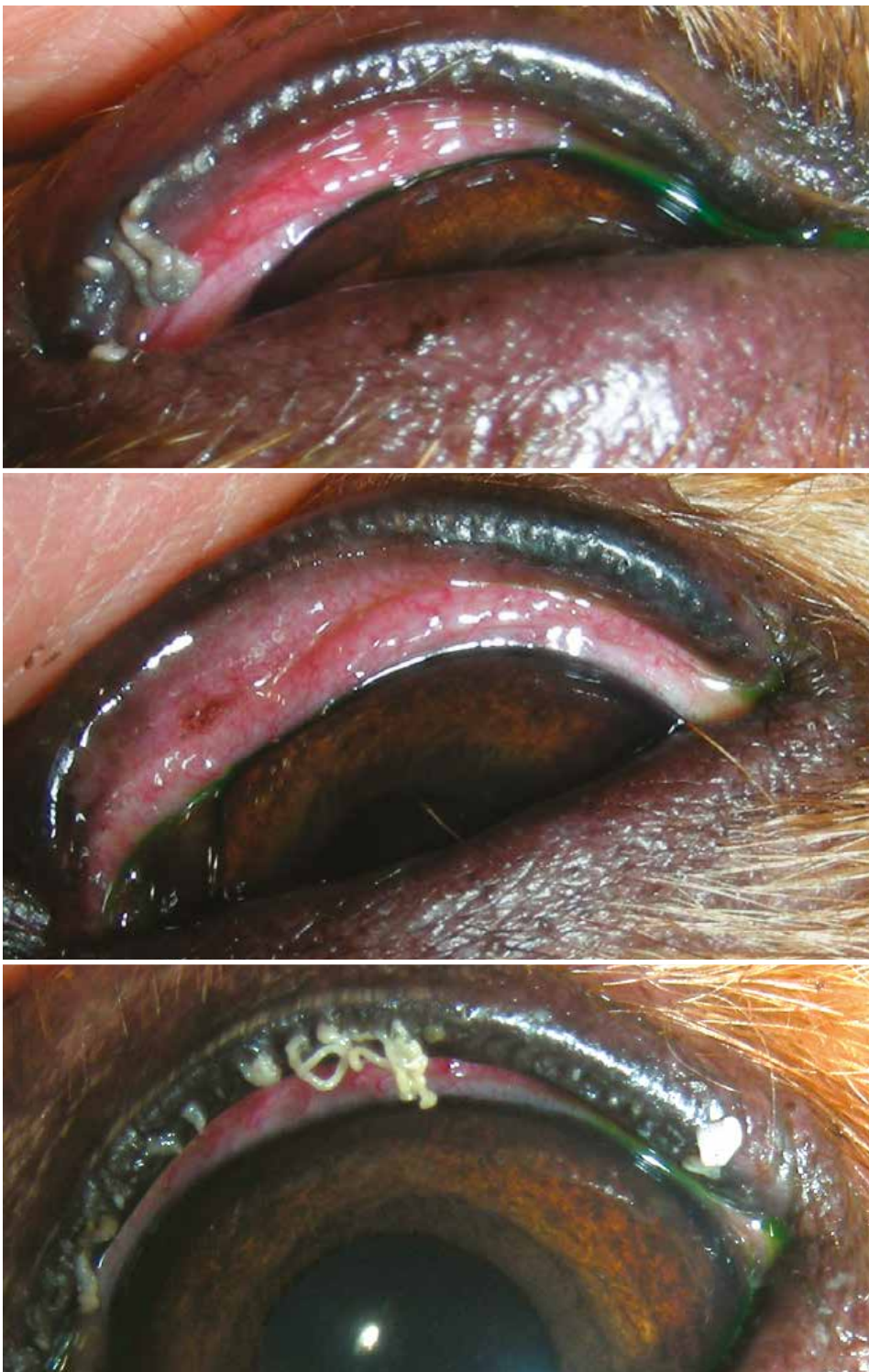5.4 sec

Meibography



MGs number reduced, MGs filled with secretion, dilation of the ductal system.

Expression of the MGs



Obstructed MGs openings, MGs secretion is thick and sticky.

Diagnosis

MGD with tear film instability and EDE.

The **obstructive Dysfunction** of the lipid-producing MGs leads to a lack of lipids, with resulting **Tear Film Deficiency** and **Evaporative Dry Eye Disease**.

The obstruction of lipid outflow from the gland causes **dilatation of the ductal system** and consecutive **pressure atrophy of the MG** with **atrophy of the secretory acini**.

Authors: Claudio Peruccio, Elena Barbasso, Daniela Terlizzi



Case 13 – Wet left eye with clinical signs of discomfort

Cat: Russian Blue, male neutered, 8 years old

Clinical history

The owner reported that the last few months the left eye started being wet, less open and with frequent blinks, while the right eye remained normal.

The treatment suggested by other veterinary surgeons, without a specific diagnosis, was based on tobramycin eyedrops but with no positive outcome.

Clinical signs at presentation

Frequent blinks and wet lower eyelid in the left eye, with a palpebral fissure of decreased size.

The right eye looks normal.

Key data after a complete ophthalmic examination

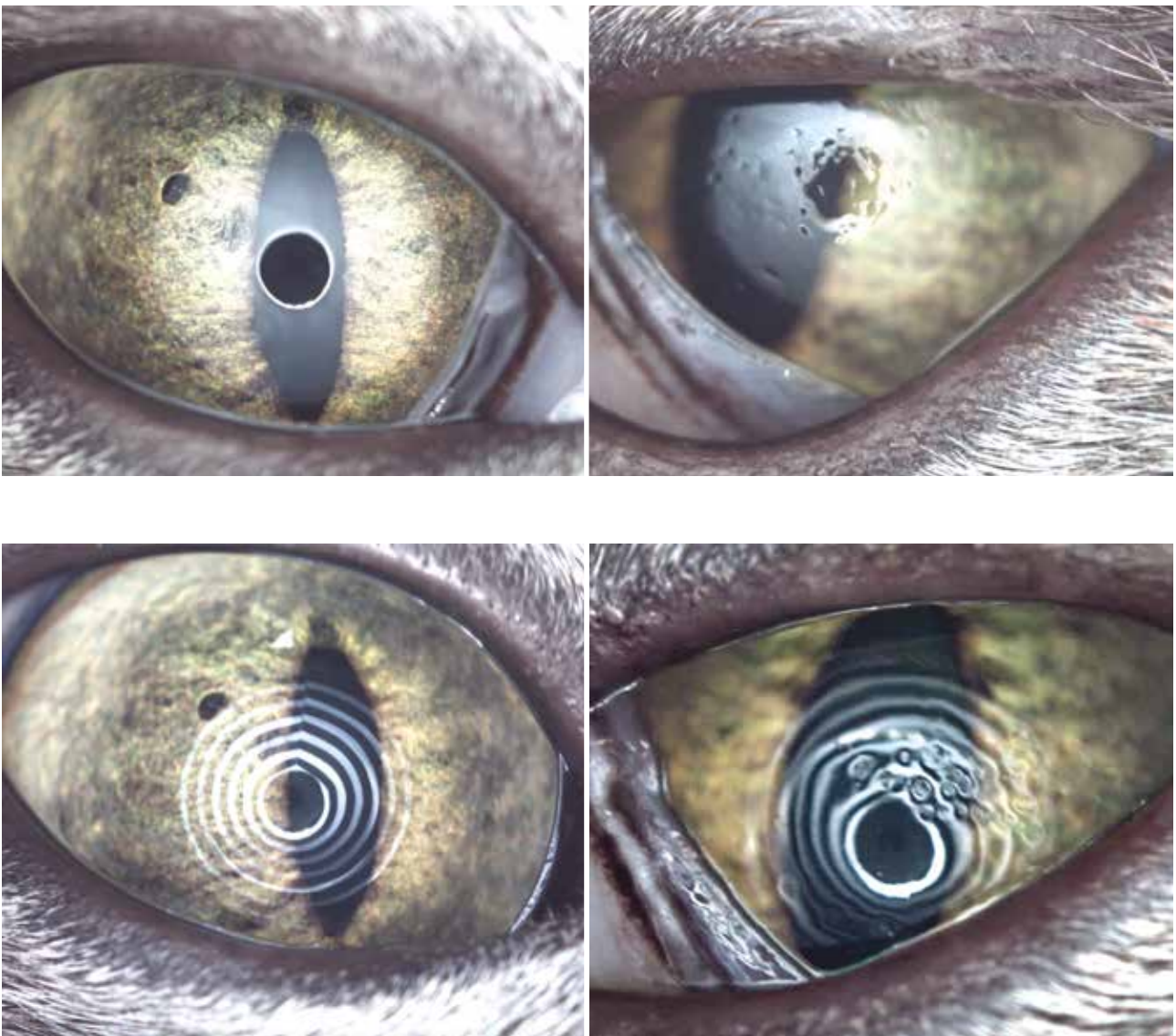
- Right eye: STT 16 mm/min, no clinical signs, a normal eye.
- Left eye: few small faint irregular corneal opacities, one linear with some branches, faintly positive to fluorescein stimulated by blue light, perhaps an outcome of herpes keratitis the owner couldn't confirm. At the slit lamp examination the ocular surface looks normal. Schirmer Tear Test: 15 mm/min.

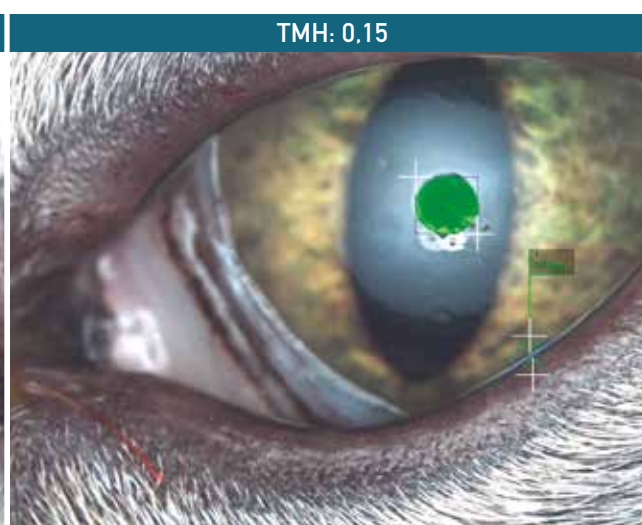
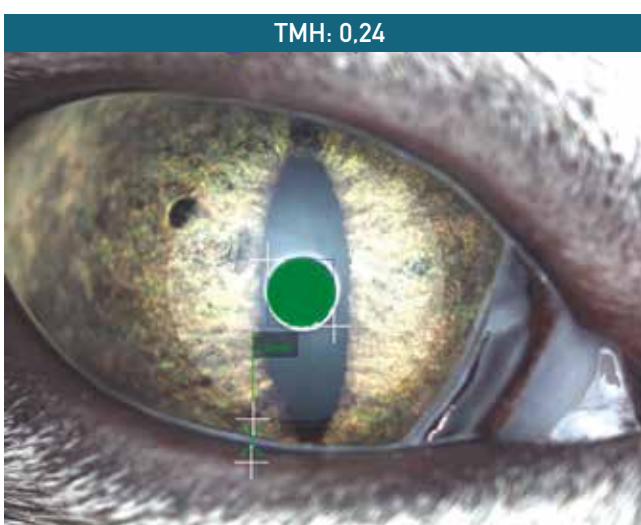
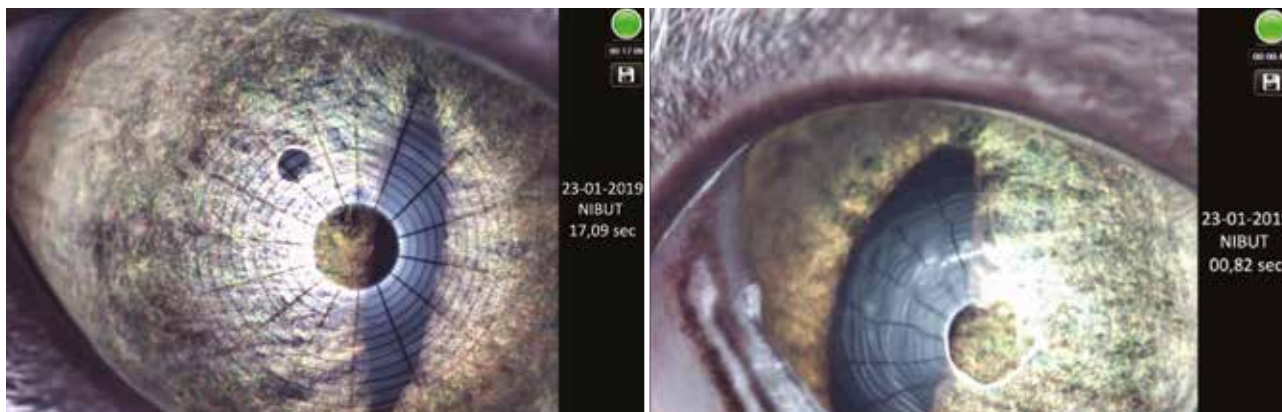
Meibography

The MGs appeared normal for size, number and regular distribution in both eyes.

Interferometry

- Right eye: the TF LLT was rated 20-30 nm (FGS), without irregular spots, the NIBUT was 17,09 seconds, and the TMH was 0,24 mm.
- Left eye: in depth examination of the ocular surface by interferometry and topography highlighted the presence of a TF LL 30-40 nm thick (FGS), with multiple dry spots, more concentrated in the center of the cornea. The TF LL was immediately broken after a blink, NIBUT value was less than 1 second, the TMH was 0,15 mm.





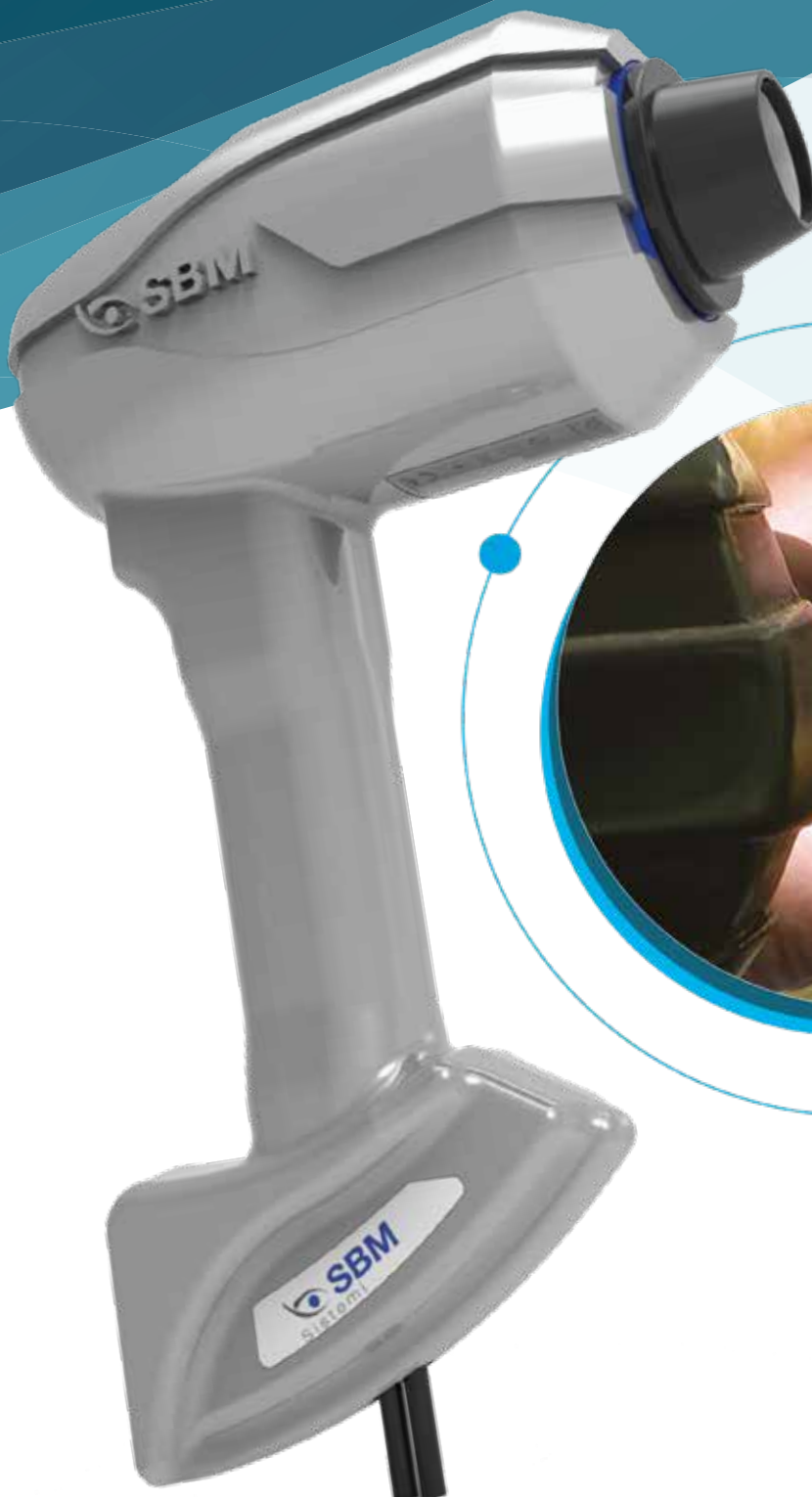
Diagnosis

Multifocal dry spots secondary to local loss of OS wettability, suggestive of defects of the corneal epithelium, with OS pain perception, increased tear production, frequent blinking and wet eye.

In short: LOSW, EDE.

A full assessment of the ocular surface is carried out through the combination of tests for the diagnosis of dry eye.

From tear film break-up time to tear meniscus height to test tear film stability, volume and composition.



Authors: Daniele Santillo, Robert Göllner



Case 14 – Right eye with clinical signs of discomfort

Cat: Domestic Shorthair, male neutered 8 years old

Clinical history

Right eye: the owner reported recurrent bilateral superficial ulceration over the last 2 years.

The patient had been previously diagnosed with bilateral dry eye and possibly FHV-1 infection by the referring veterinary surgeon. He had 2 episodes of large superficial ulcers with loose epithelium OD and 4 episodes in the left eye over the previous 10 months, when the above picture was taken. Both eyes had been treated with lubricants, topical antibiotics and Ganciclovir due to the suspected FHV-1 infection. Ulcers usually healed in 5-7 days with no complications.

Clinical signs at presentation

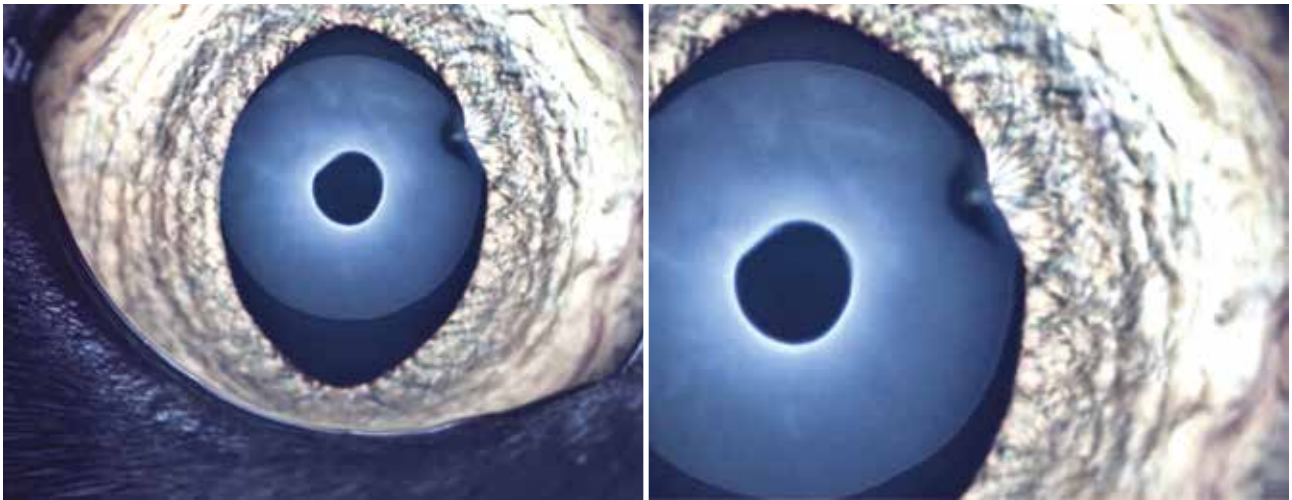
Blepharospasm and mild miosis with no fluorescein staining OD. The left eye appeared to be comfortable with no fluorescein uptake. However, the cat had a superficial ulcer 2 weeks before, which recurred a week after the ocular surface investigation.

Key data after a complete ophthalmic examination

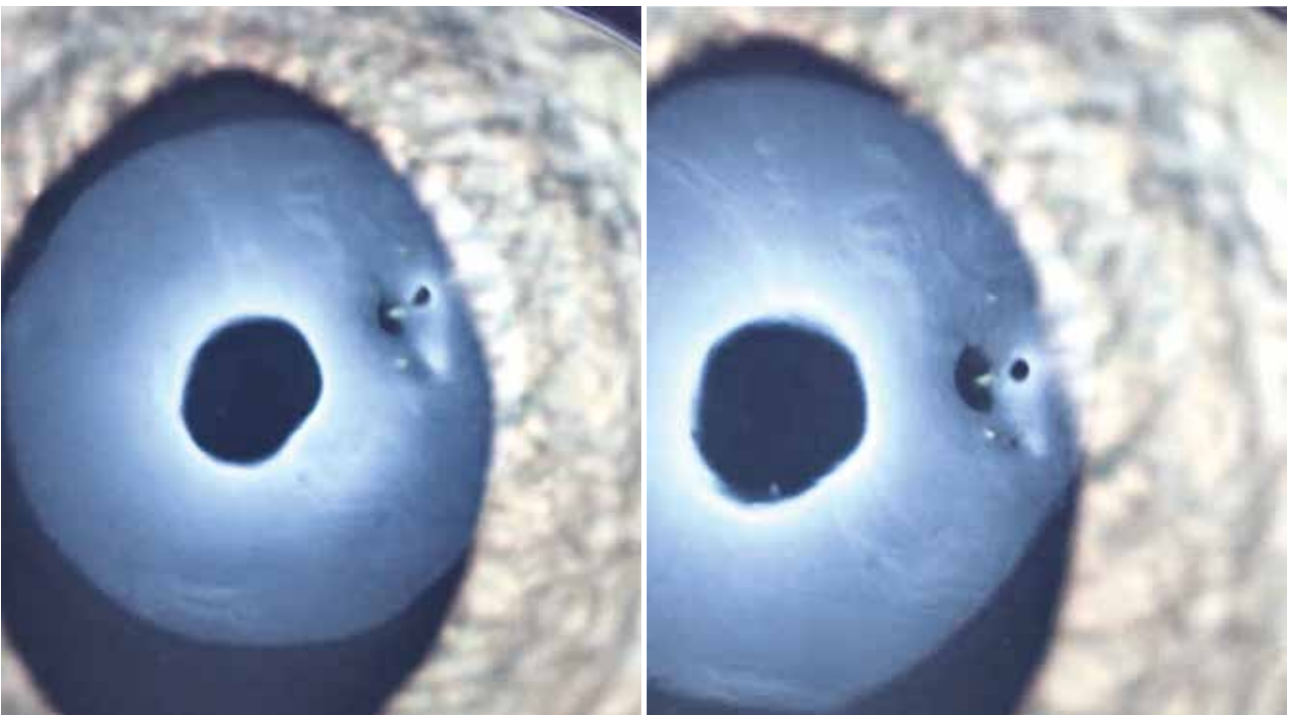
Mild ocular discomfort OD.

STT: 5 mm/minute OD, 9 mm/minute OS. Slit lamp examination was unremarkable.

Interferometry



The TF LL was rated 40-60 nm thick (FGS). A defective area of the interferometric pattern was present in the dorso-medial quadrant of the right eye.



A few seconds after a forced blink mucin aggregates and dry spots were evident in the defective area as a consequence of TF evaporation caused by the corneal fibrosis.

Diagnosis

Epithelial defect of the cornea with low STT, loss of OS wettability, dry spots and, as a consequence, increased TF evaporation and pain perception with resulting clinical signs.

In short: LOSW, ADDE, EDE.

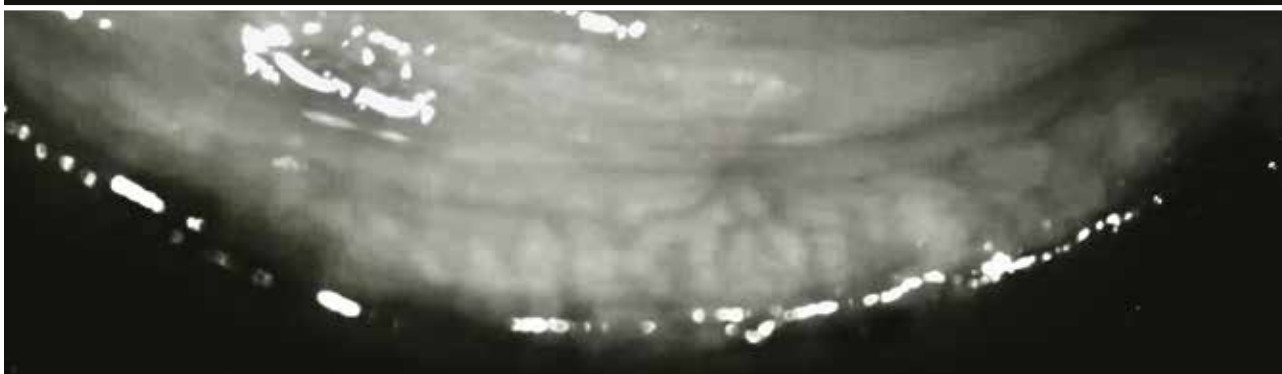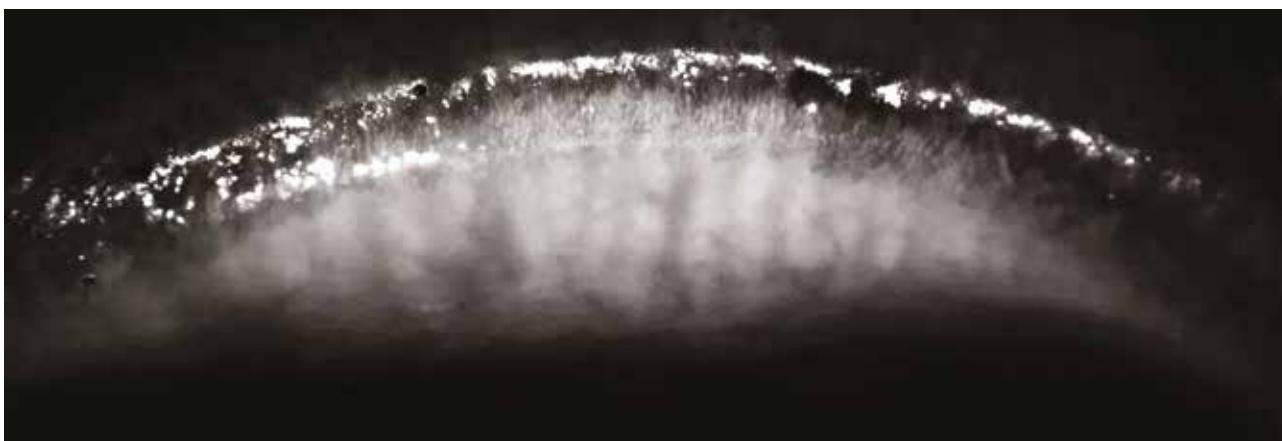
Authors: Alexia Cattaneo, Claudio Peruccio



Case 15 – Normal eyes

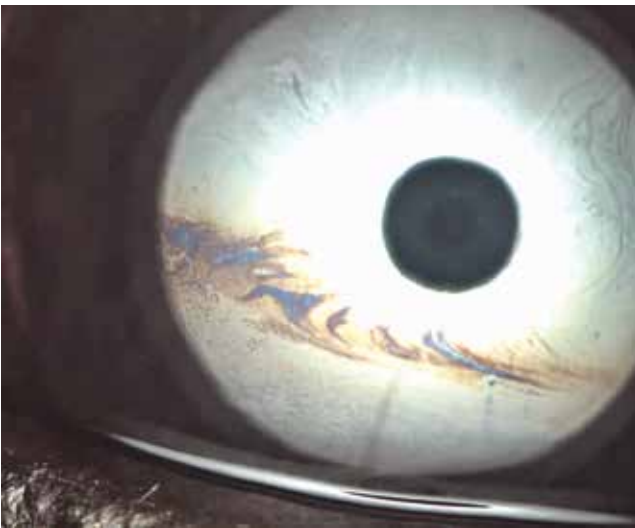Horse: Italian saddle horse, gelding, 11 years old

Meibography

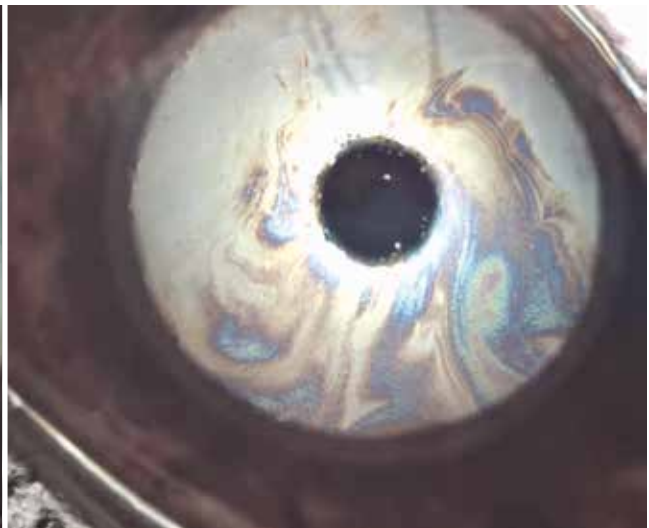


Normal distribution of MGs in the upper and lower eyelids.

Interferometry




Tear film lipid layer pattern with a streak of thicker lipids appearing as a coloured wave of interference fringes. Estimated LLT: 80 nm.



A relatively thick LL which displays a large islet with numerous coloured interference fringes. Estimated LLT >100 nm.

Placido disc topography



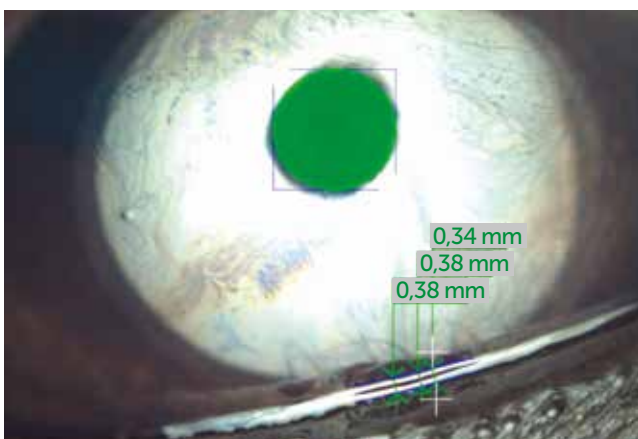
The Placido rings show the topography of a normal cornea.

NIBUT



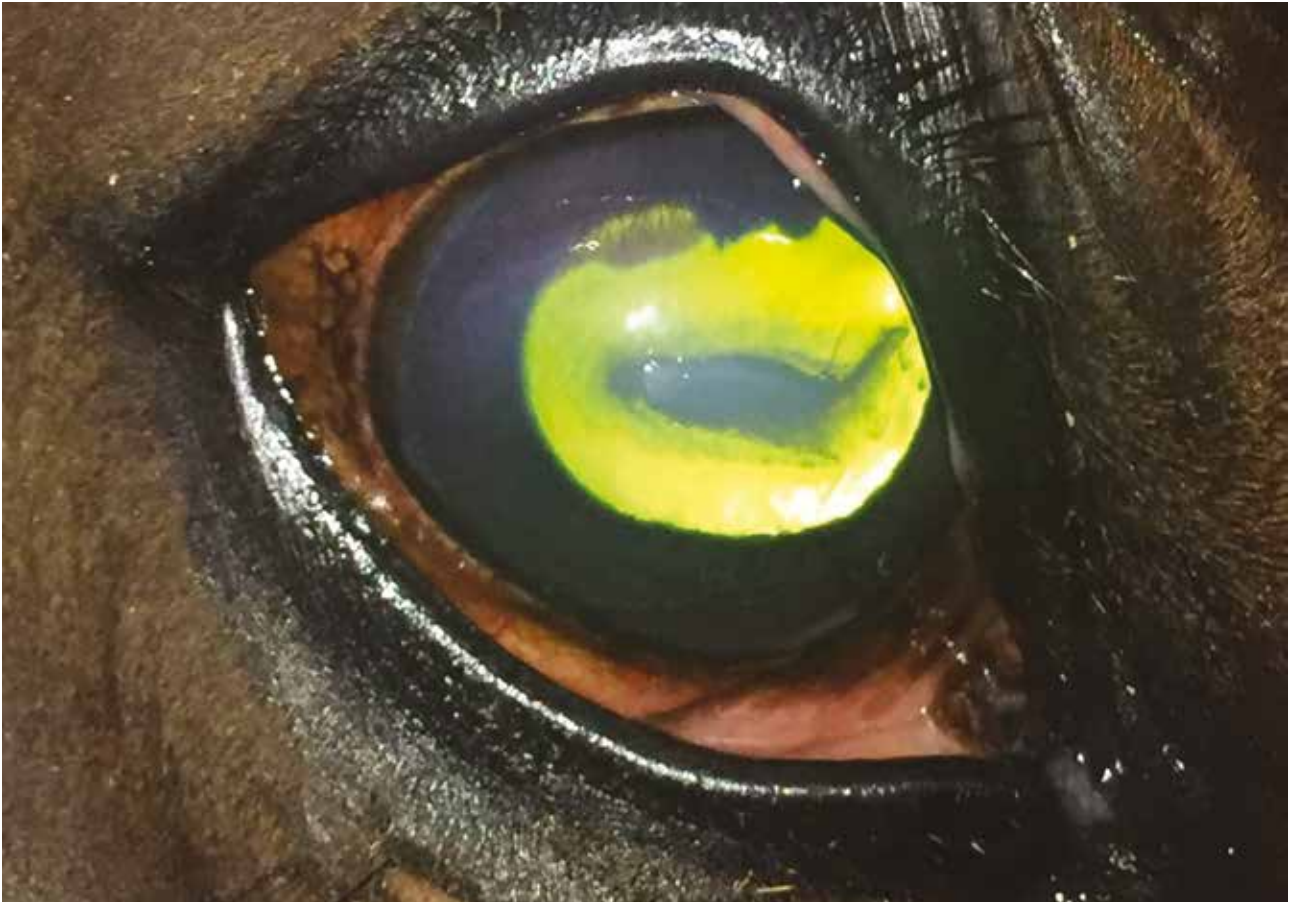The NIBUT grid can also be used for evaluation of corneal topography.

Tear Meniscus Height



TMH calculated as 0,36 mm, being the median value between the TMH measured in three different points: 0,38 mm, 0,38 mm, 0,34 mm.

Authors: Alexia Cattaneo, Claudio Peruccio



Case 16 – Right eye with fungal keratitis / blepharospasm and epiphora

Horse: Dutch harness horse, female, 16 years old

Clinical history

First examination: 9 days prior to interferometry and topography. The presumptive diagnosis of fungal keratitis was confirmed with culture of *Aspergillus flavus* by the laboratory.

Second examination: the day of OS analysis.

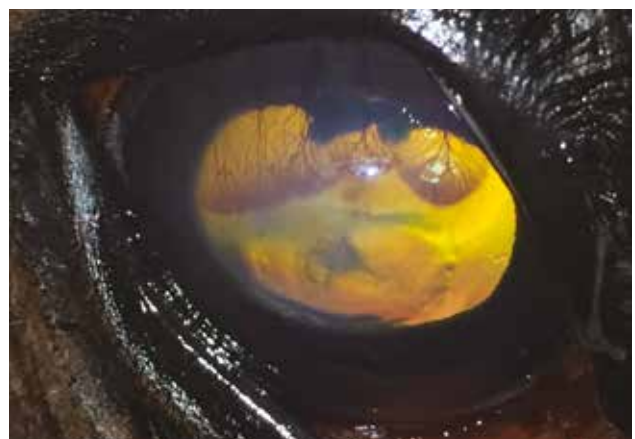
Clinical signs at presentation

Some blepharospasm and epiphora.

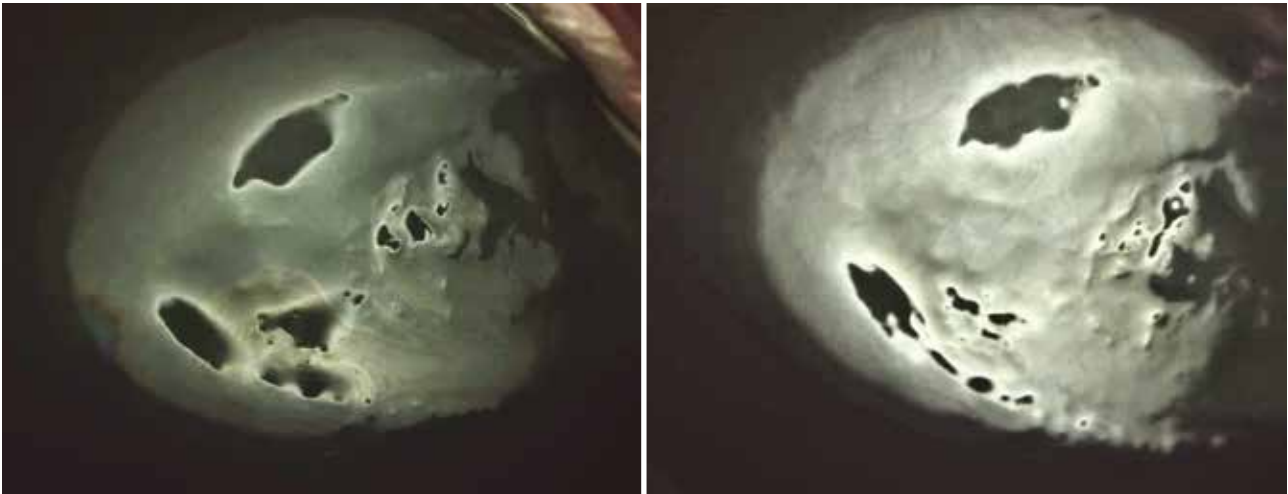
The cornea is undergoing a major keratitis, with the replacement of the initial fungal plaque with deep stromal vessels reaching the centre of the cornea.

Key data after a complete ophthalmic examination

Blepharospasm, epiphora, keratitis with neovascularisation starting superficial at the limbus, especially dorsally, and going deeper close to the initial lesion in the centre of the cornea.

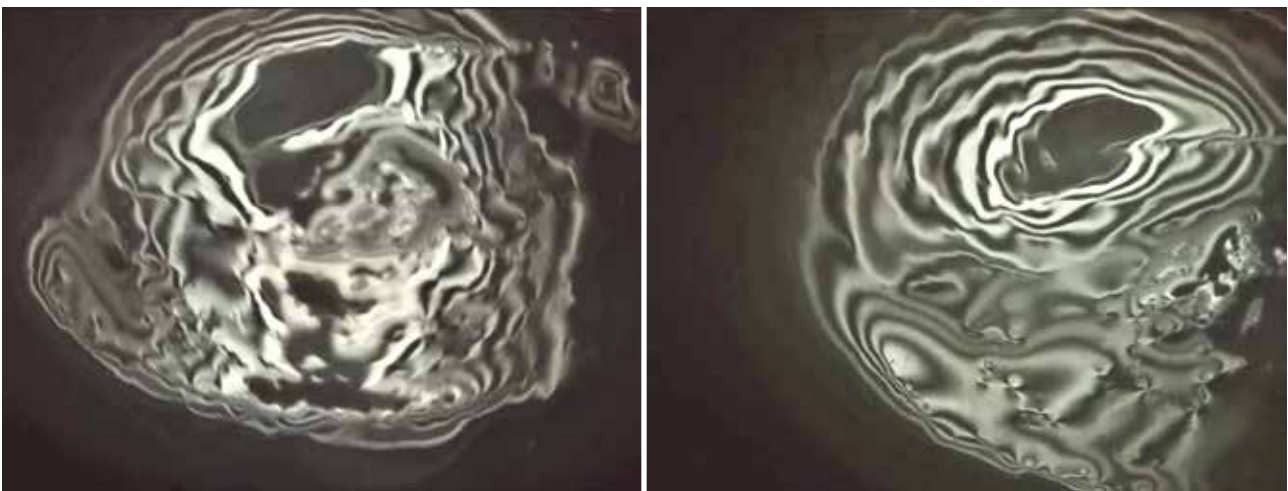


Interferometry



There is no smooth pattern of the cornea and LL thickness is not testable due to interruptions of the tear film.

Placido disc topography



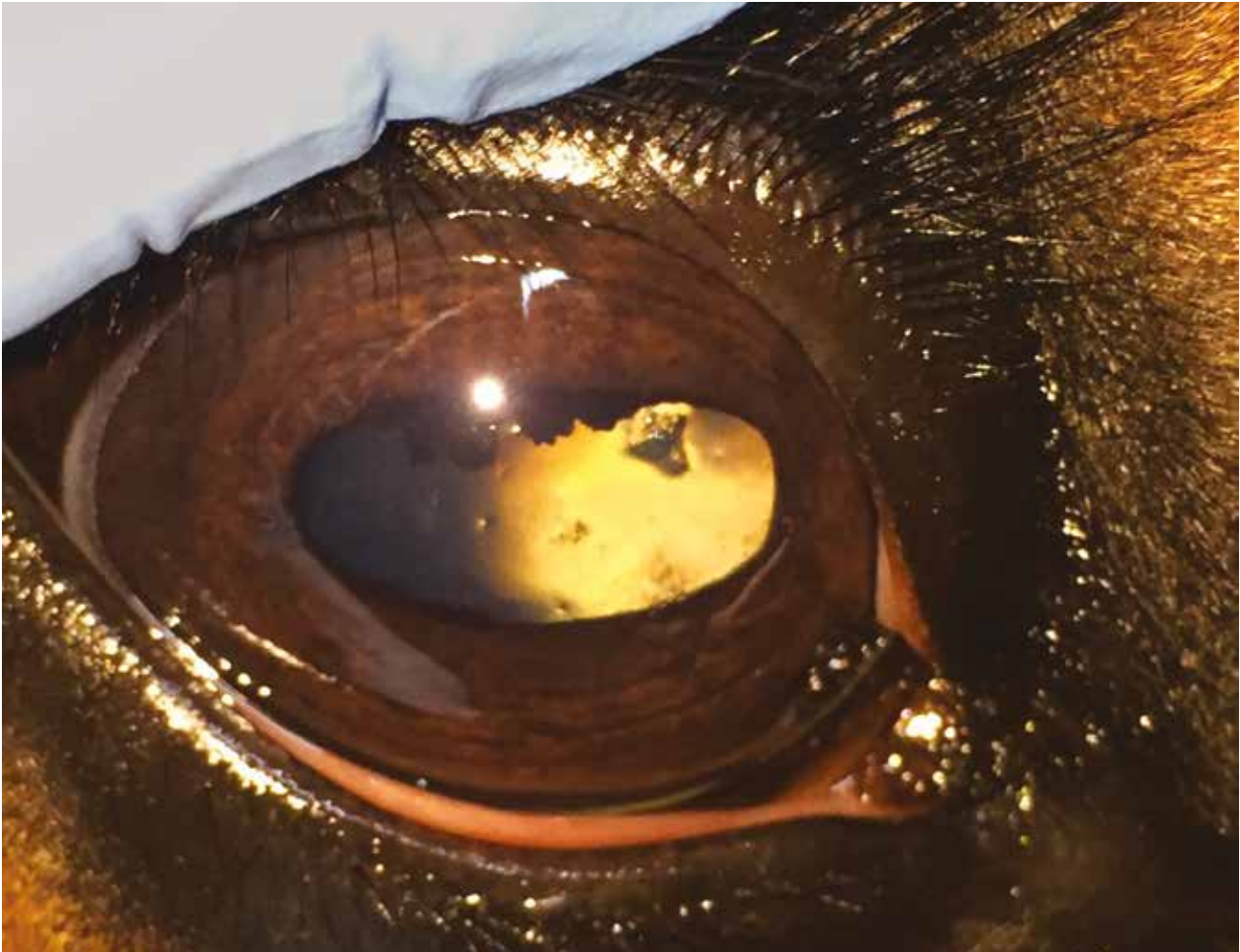
The irregularity of the ocular surface is easily seen.

Diagnosis

Fungal keratitis (*Aspergillus lavus*)

In short: Corneal irregularities, EDE, QLDE.

Authors: Alexia Cattaneo, Claudio Peruccio



Case 17 – Right eye with fungal keratitis / blepharospasm and epiphora

Horse: Spanish sport horse, female, 10 years old

Clinical history

Intense blepharospasm and epiphora of the right eye since one month and a half. The mare was treated with itraconazole and tobramycin for three weeks, then ciclosporin A and tobramycin, without any improvement.

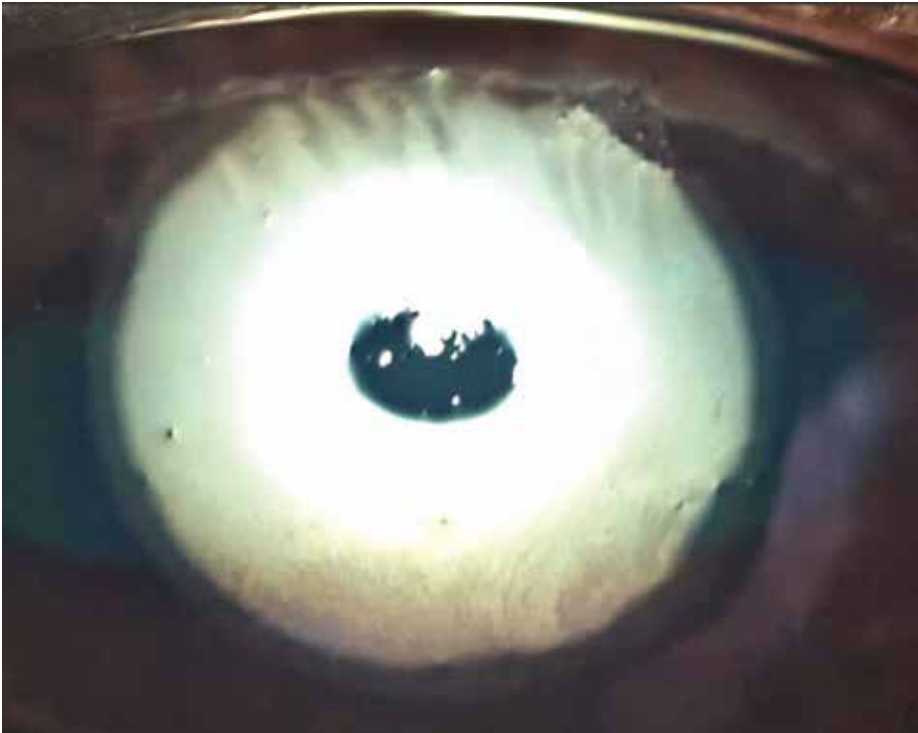
Clinical signs at presentation

Intense blepharospasm and epiphora.

Key data after a complete ophthalmic examination

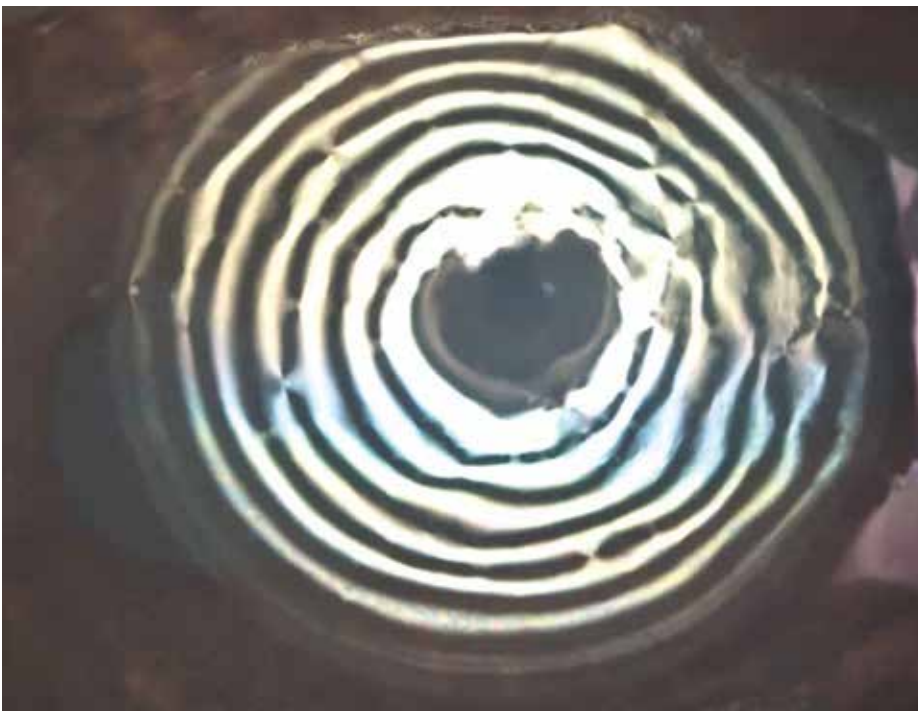There is punctate keratitis in the right eye and there are small white spider web-like lesions under the corneal epithelium. Some lesions are positively coloured with Rose Bengal and in one point the epithelium is not intact.

Interferometry



The punctate keratitis is easy to observe, as well as interruptions of the tear film.

Placido disc topography



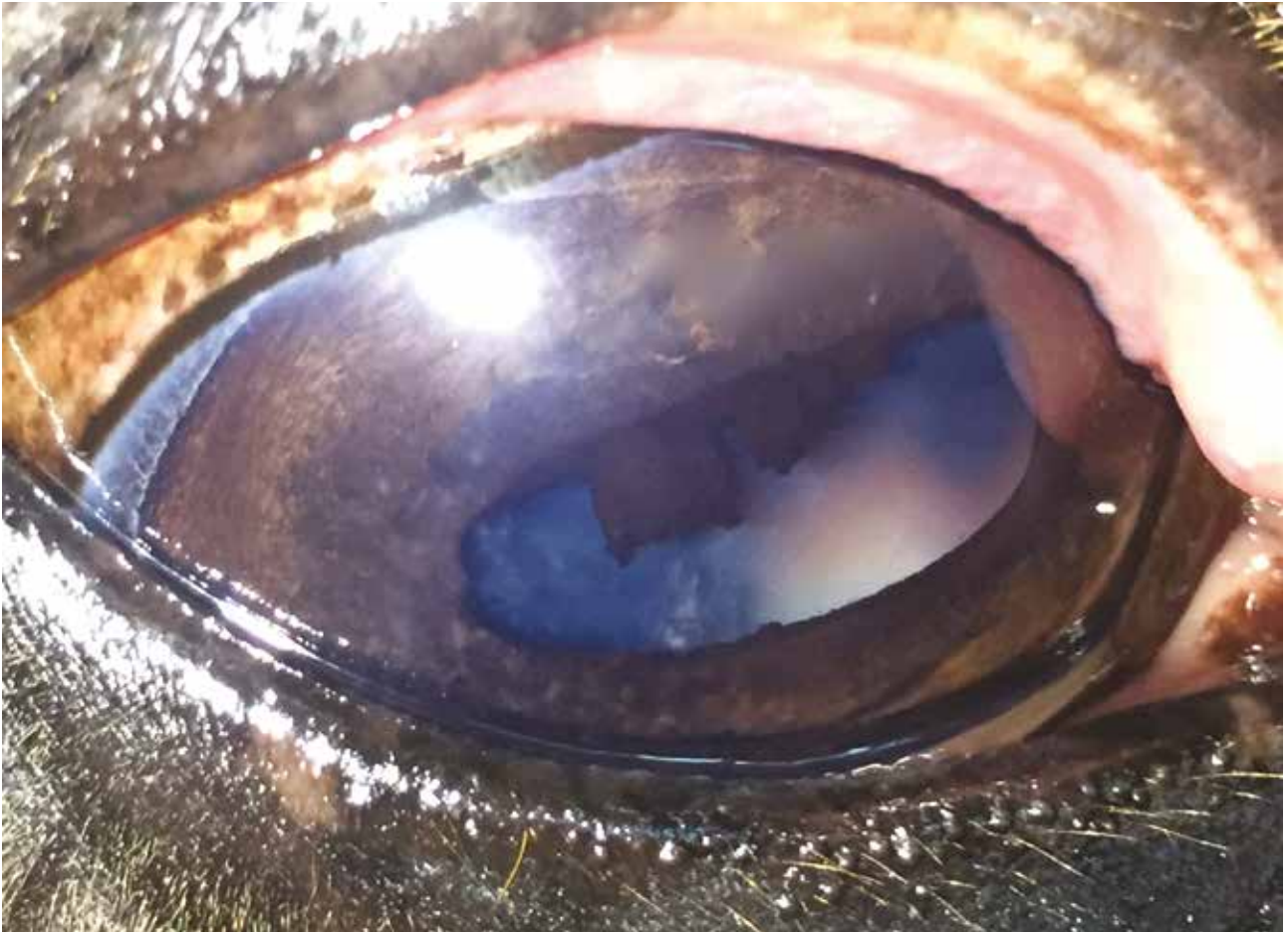With the Placido disc applied on the OSA-VET instrument, the altered corneal topography is evident.

Diagnosis

Fungal keratitis (*Aspergillus niger*)

In short: corneal defects, EDE.

Authors: Alexia Cattaneo, Claudio Peruccio



Case 18 – Right eye with punctate keratitis / blepharospasm and epiphora, swollen eyelids

Horse: Italian saddle horse, gelding, 17 years old

Clinical history

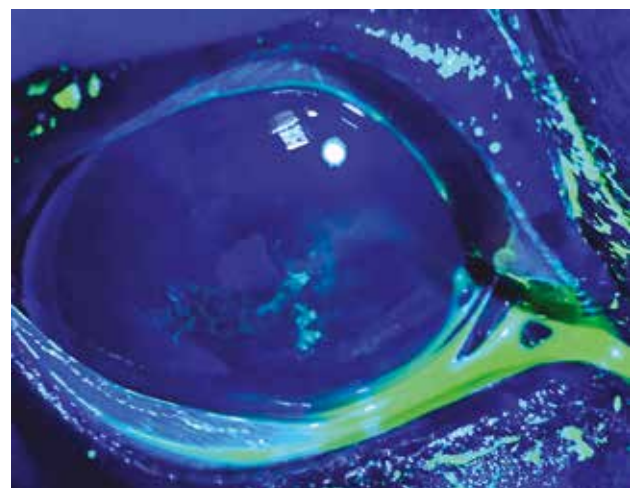
Blepharospasm, epiphora, oedematous eyelids of the right eye since a few days.

Clinical signs at presentation

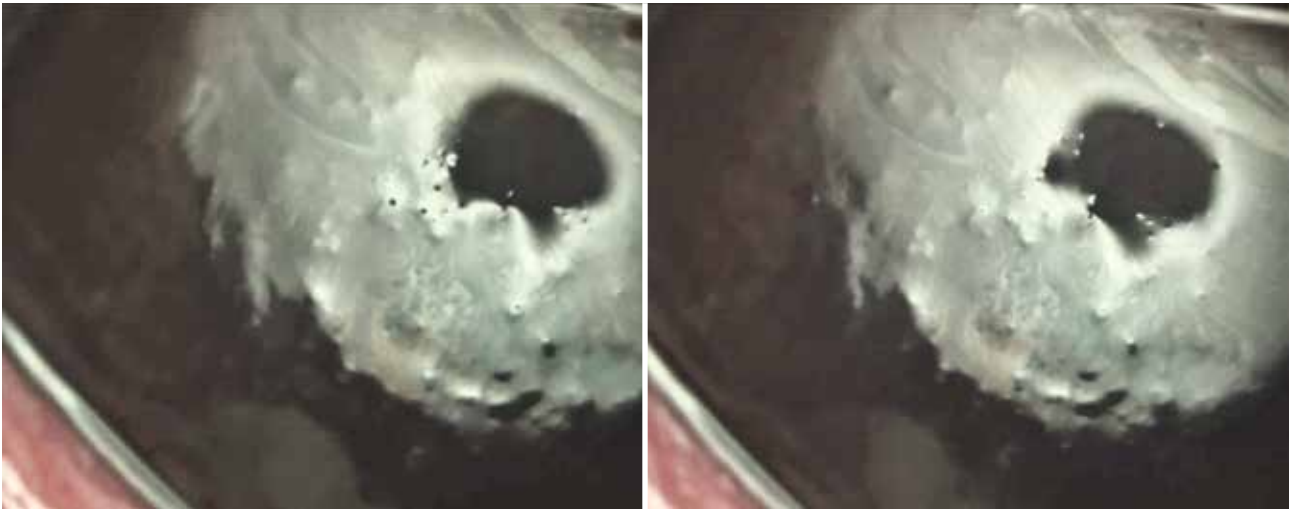
Blepharospasm and abundant epiphora, photophobia.

Key data after a complete ophthalmic examination

Punctate keratitis in the ventro-temporal quadrant of the cornea, with positivity both to fluorescein and rose Bengal dyes. White linear lesions underneath the epithelium.

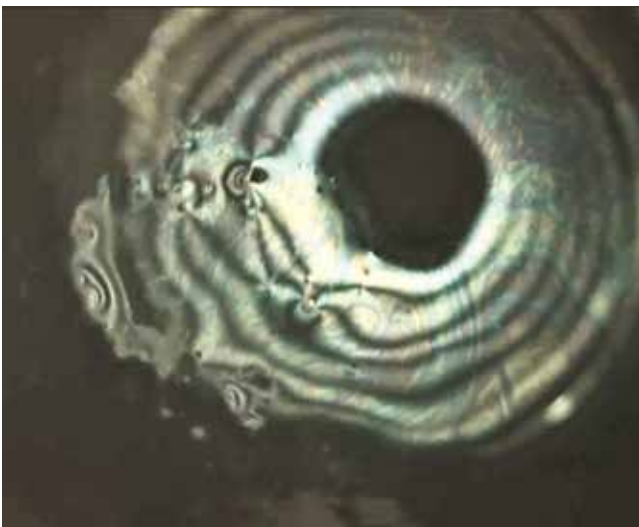


Interferometry



The ventro-temporal quadrant of the cornea has evident punctate keratitis and deformation (probably due to fungal keratitis).

Placido disc topography



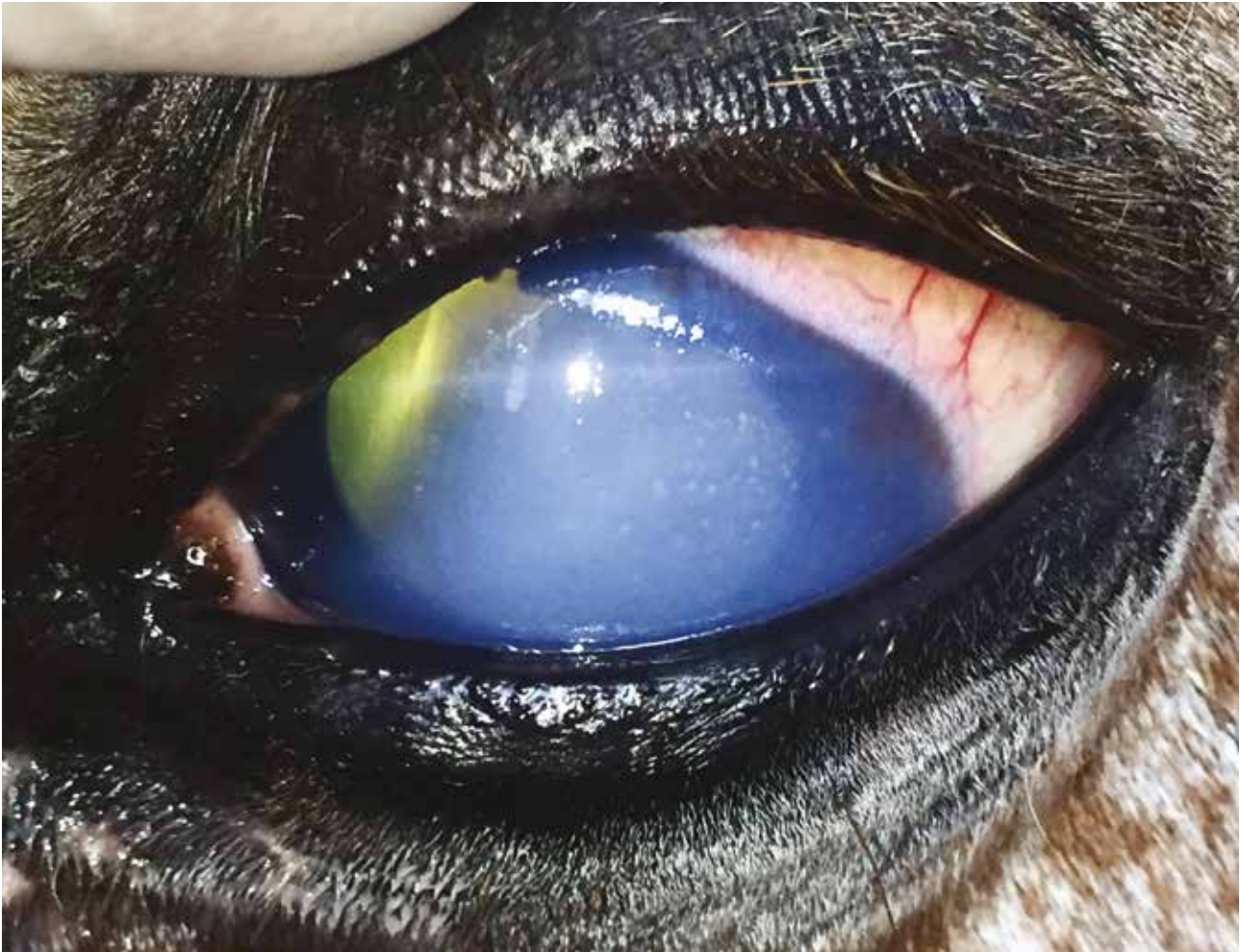The irregularity of the ocular surface is easily seen.

Diagnosis

Presumptive diagnosis of fungal keratitis.

In short: corneal defects, EDE.

Authors: Alexia Cattaneo, Claudio Peruccio



Case 19 – Left eye with bullous keratopathy / cloudy eye and epiphora

Horse: Typ Szlachetny horse, gelding, 18 years old

Clinical history

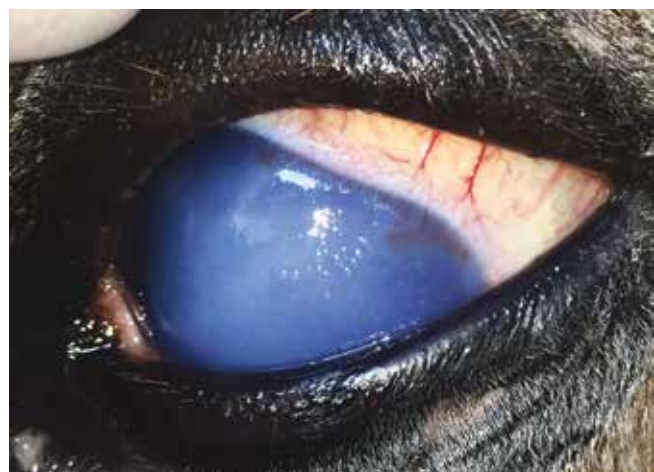Left eye with a diffuse opacity since 4 days, epiphora.

Clinical signs at presentation

Left eye with buphthalmos, bullous keratopathy and epiphora due to intraocular pressure of 45 mmHg.

Key data after a complete ophthalmic examination

Bullous keratopathy, IOP 45 mmHg.



Interferometry



The tear film is irregularly distributed on the cornea

Placido disc topography



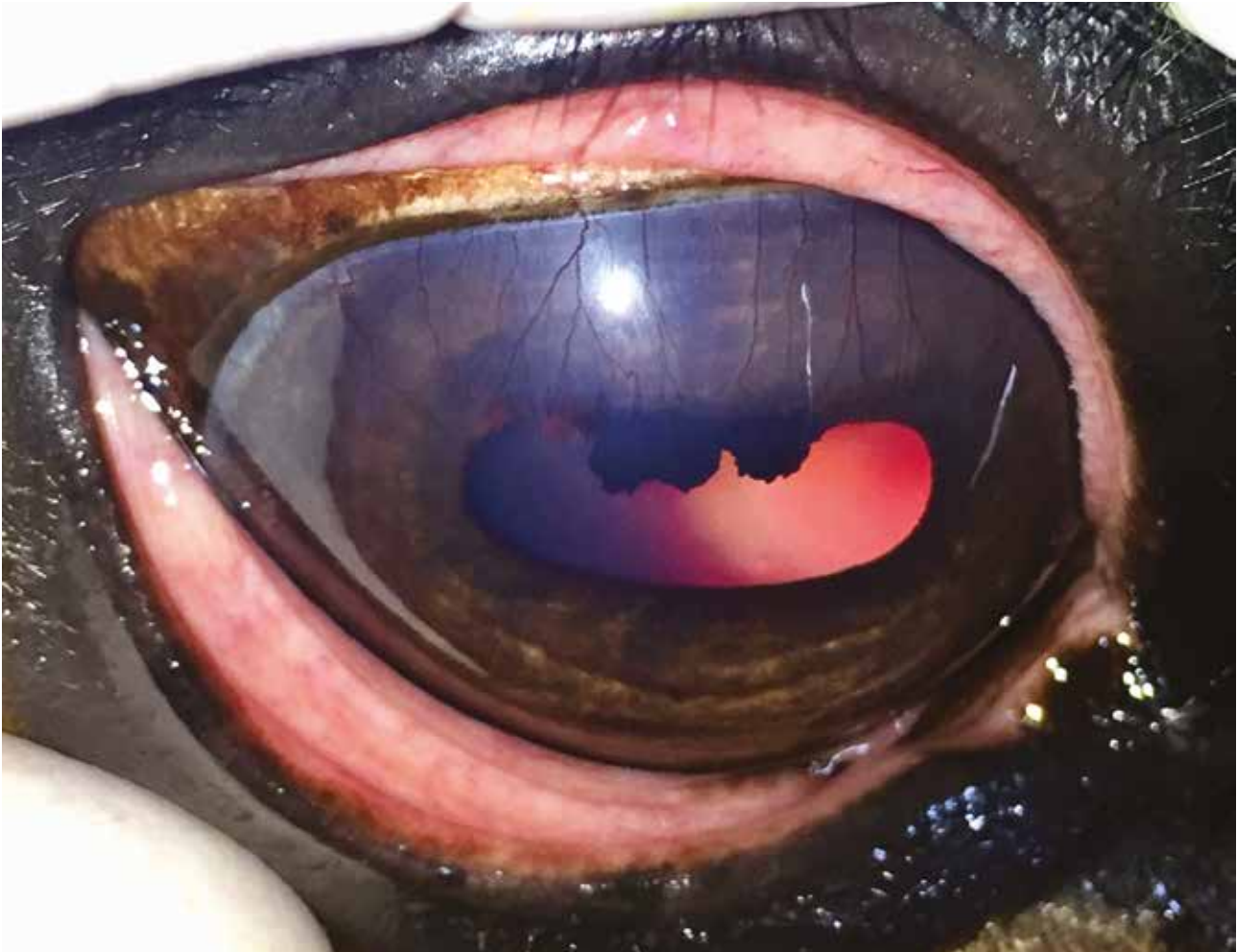Presence of bullae on the entire ocular surface.

Diagnosis

Bullous keratopathy due to glaucoma.

In short: corneal defects, EDE.

Authors: Alexia Cattaneo, Claudio Peruccio



Case 20 – Left eye with superficial IMMK / slight blepharospasm and epiphora

Horse: Italian saddle horse, gelding, 11 years old

Clinical history

Six months history of recurrent episodes of blepharospasm of the right eye, that spontaneously resolve within a few days.

Clinical signs at presentation

Slight blepharospasm, abundant epiphora, in absence of overt signs of pain.

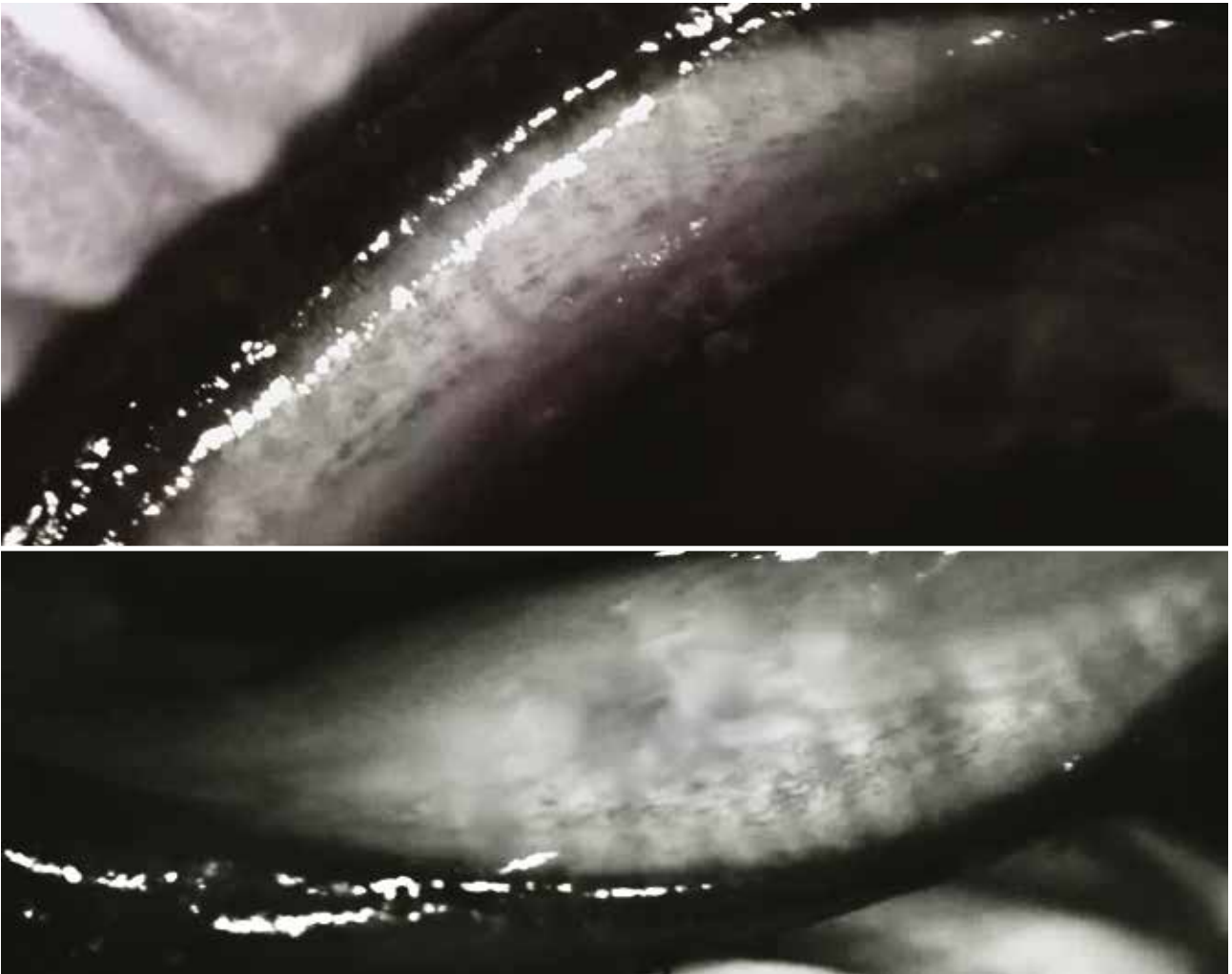
Key data after a complete ophthalmic examination

Slight blepharospasm, epiphora, superficial keratitis with dorsal superficial neo-vascularization in the right cornea, with intact epithelium and no positive coloration with fluorescein or rose Bengal dyes.

Chorioretinitis scar medially to optic nerve head (similar to ERU scar).

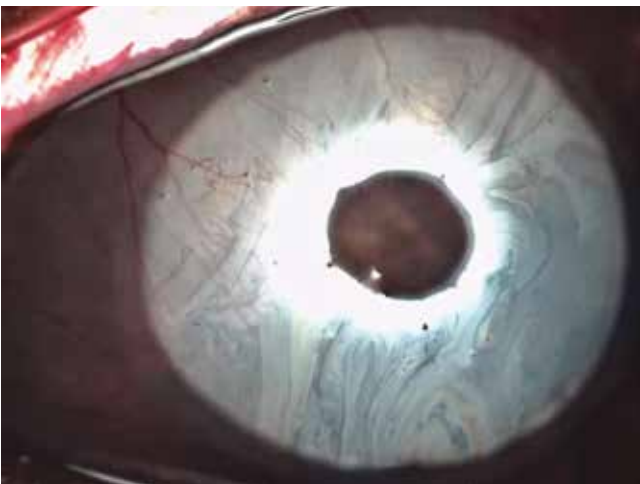
STT > 35 mm in 10".

Meibography



Normal MGs in both upper and lower eyelids.

Interferometry



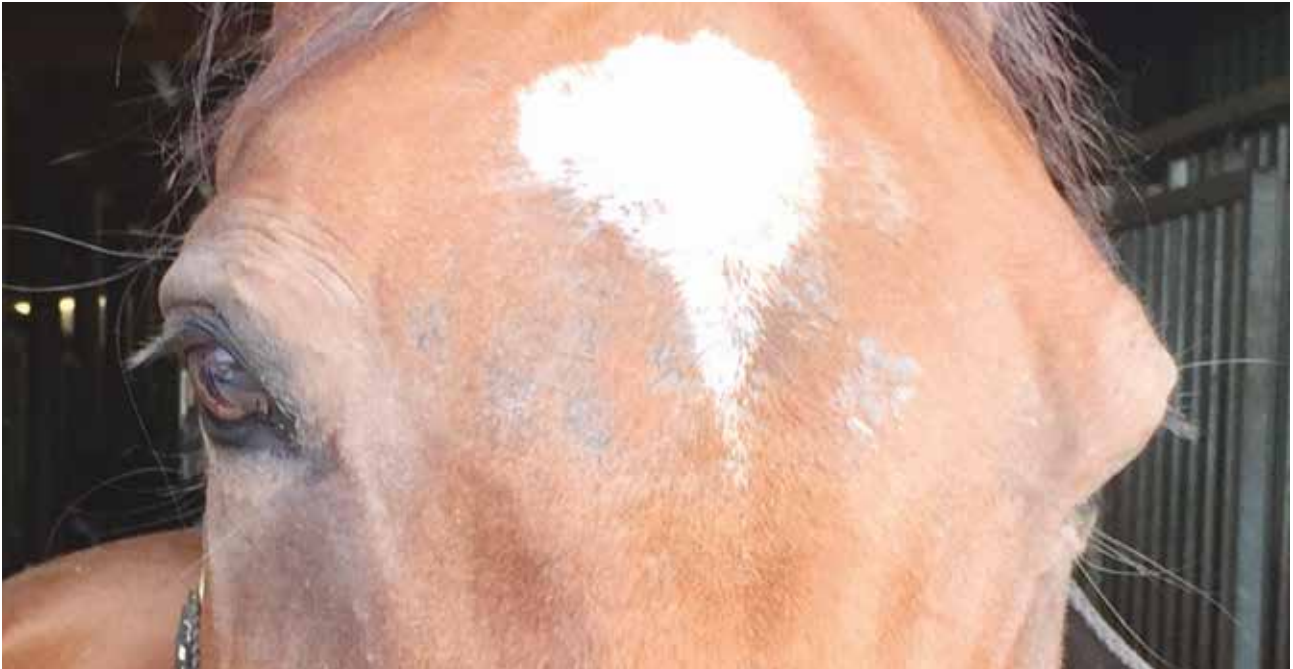Presence of normal tear film with an 80-100 nm LLT.

Diagnosis

Superficial IMMK with normal MGs.

In short: slight corneal deformation.

Authors: Alexia Cattaneo, Claudio Peruccio



Case 21 – Superficial IMMK / Blepharospasm and epiphora OU

Horse: Holsteiner, female, 13 years old

Clinical history

Two weeks history of recurrent blepharospasm and epiphora of the left eye, and then the right eye.

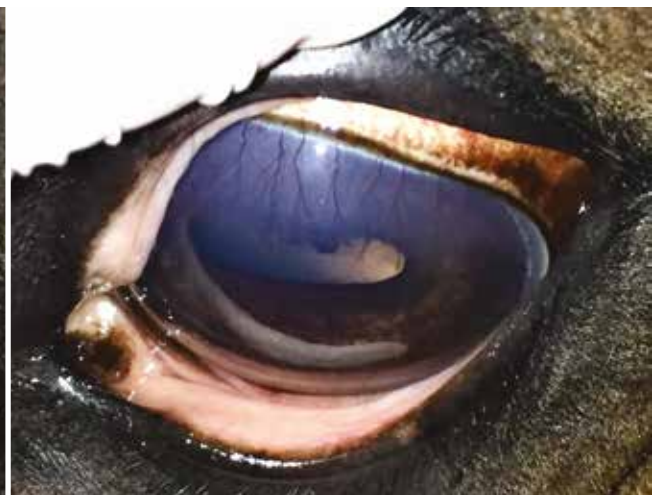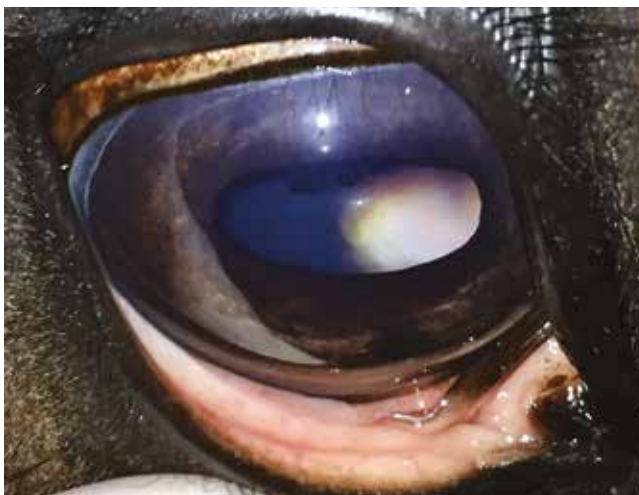Clinical signs at presentation

Blepharospasm and epiphora of the left eye, mild blepharospasm of the right eye.

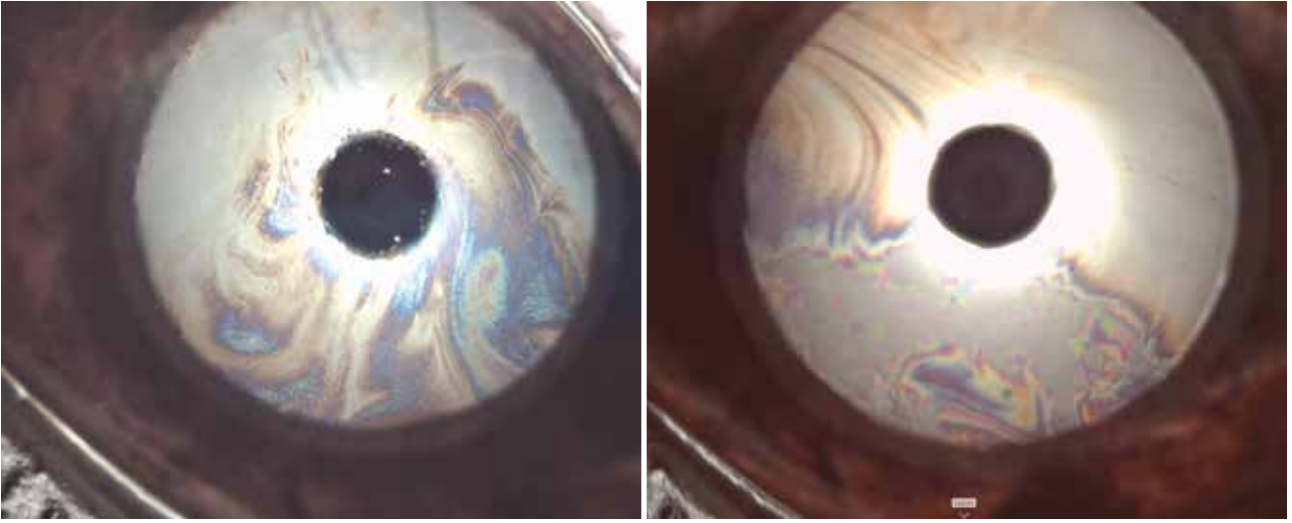
Key data after a complete ophthalmic examination

Left eye: STT 23 mm / 1 min, superficial keratitis with dorsal superficial vascularization of the cornea and opacity of the dorsal half of the eye.

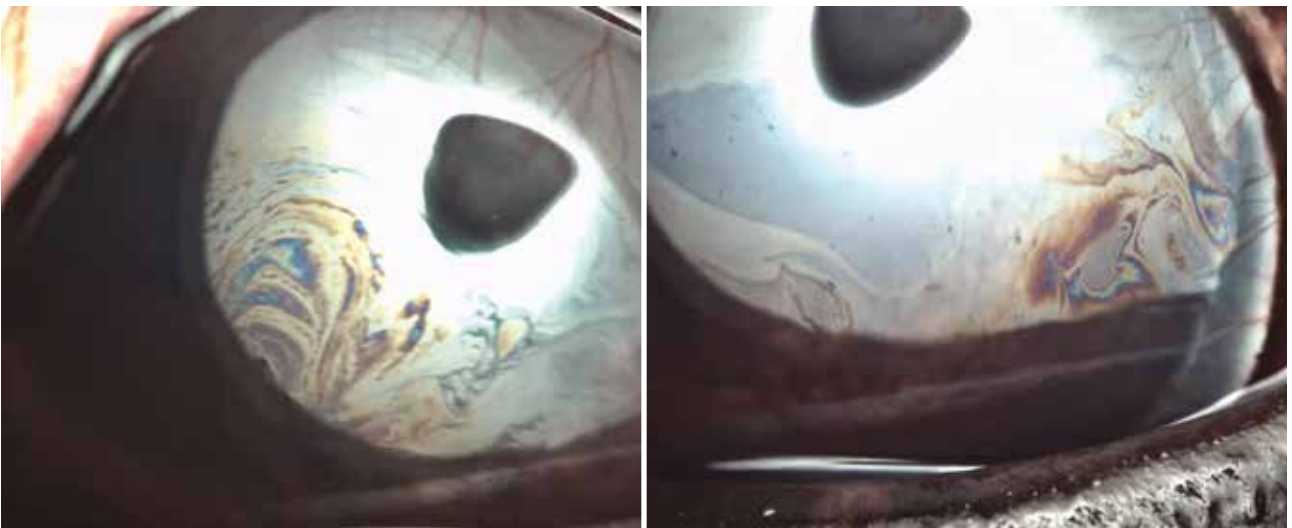
Right eye: STT 25 mm / 1 min, superficial keratitis with dorsal superficial vascularization of the cornea with short vessels and only a slight opacity of the dorsal part of the eye.



Interferometry



Right eye: thick LL (>80 nm) and normal tear film distribution, less deformation of the dorsal part of the cornea.



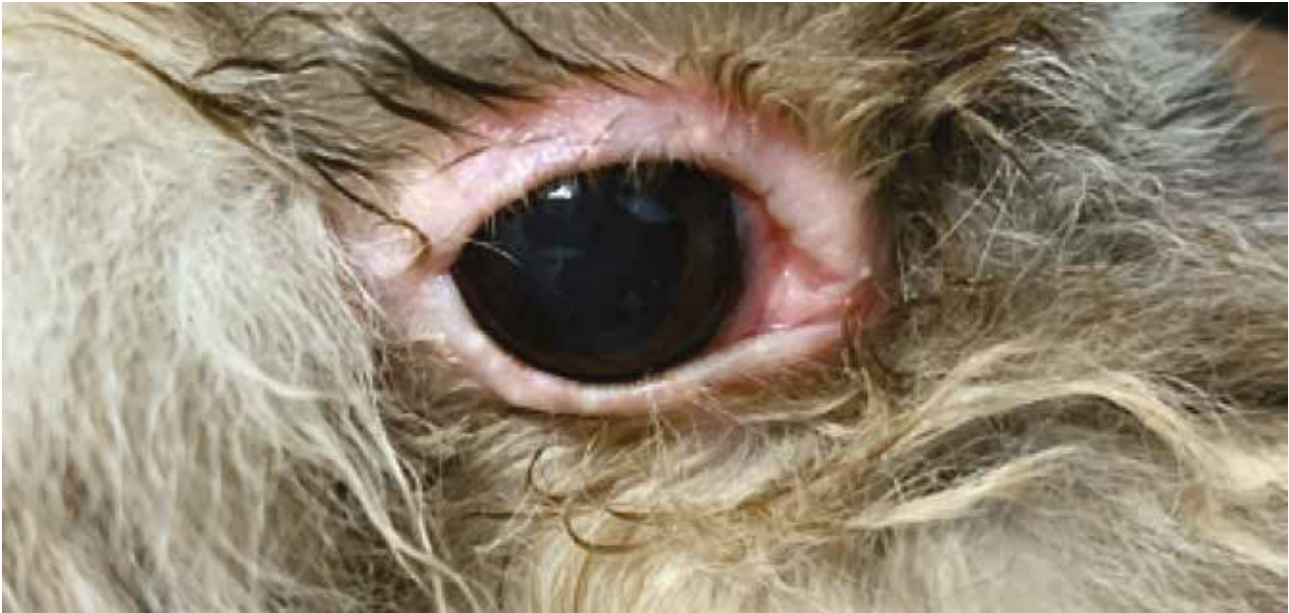Left eye: thick LL (>80 nm) and normal distribution of the tear film on the cornea. Deformation of the dorsal part of the cornea that is more evident by adding the Placido disc to the OSA-VET instrument.

Diagnosis

Superficial IMMK with normal MGs.

In short: slight corneal deformation.

Authors: Francesca Corsi, Adolfo Guandalini



Case 22 – Wet eyes, blepharitis

Rabbit: Holland Lop, neutered female, 6 years old

Clinical history

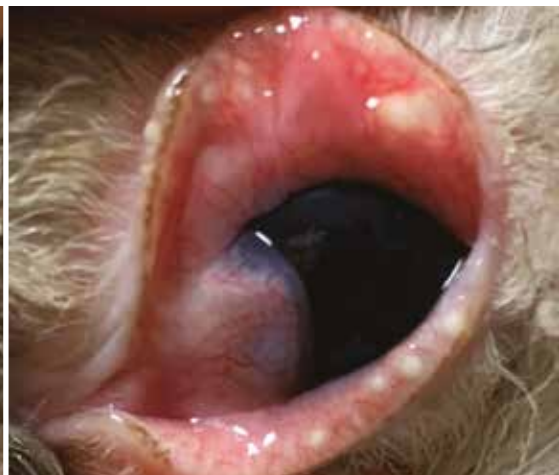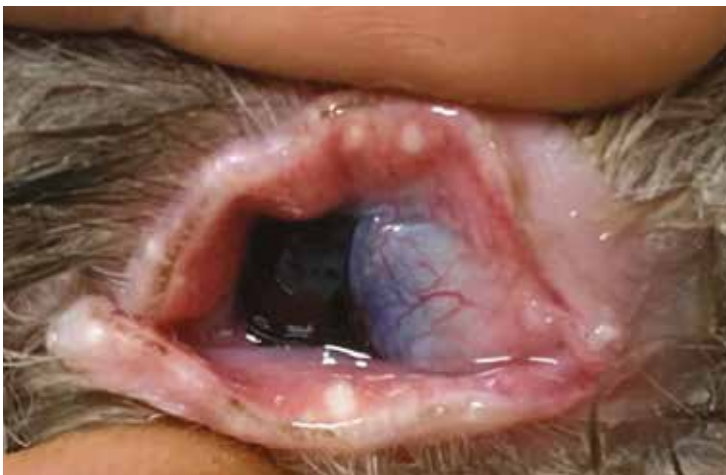History of chronic mucous discharge.
Referred because of constantly wet eyes.

Clinical signs at presentation

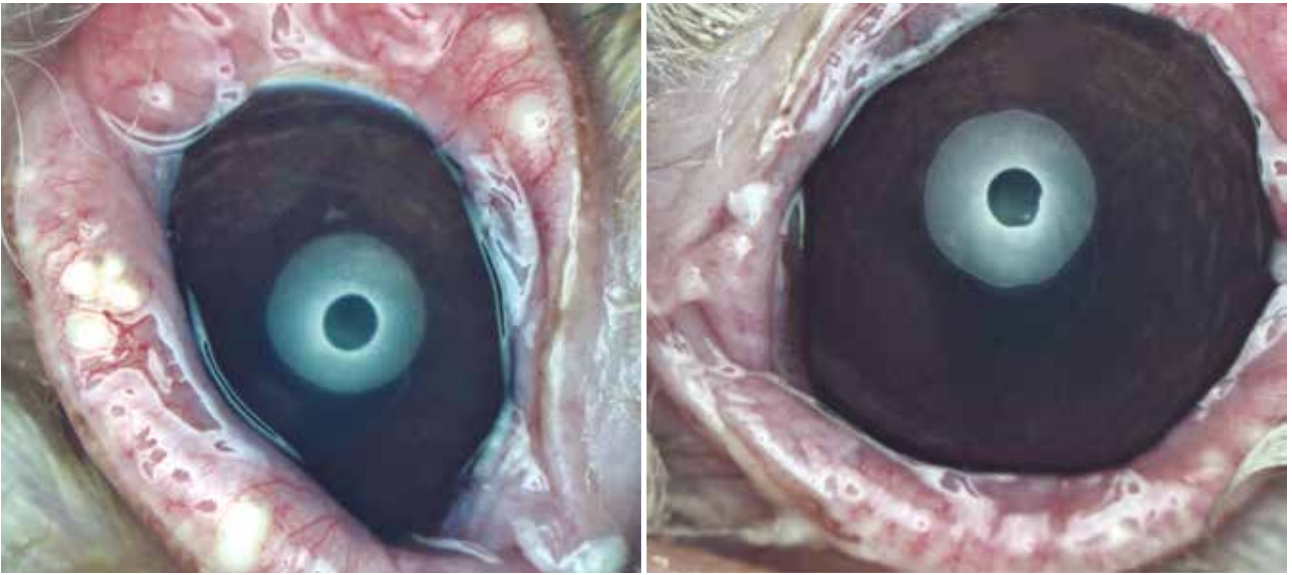
The skin of the eyelids is wet, especially in the right eyelids. Bilateral blepharitis and moderate periocular alopecia. The MGs and their ductal openings are significantly altered OU.

Key data after a complete ophthalmic examination

- Wet eyes
- Mucous discharge
- STT: 16 mm/min RE; 16 mm/min LE
- Osmolarity: 366 mOsm/L RE; 379 mOsm/L LE
- MGD in the 4 eyelids



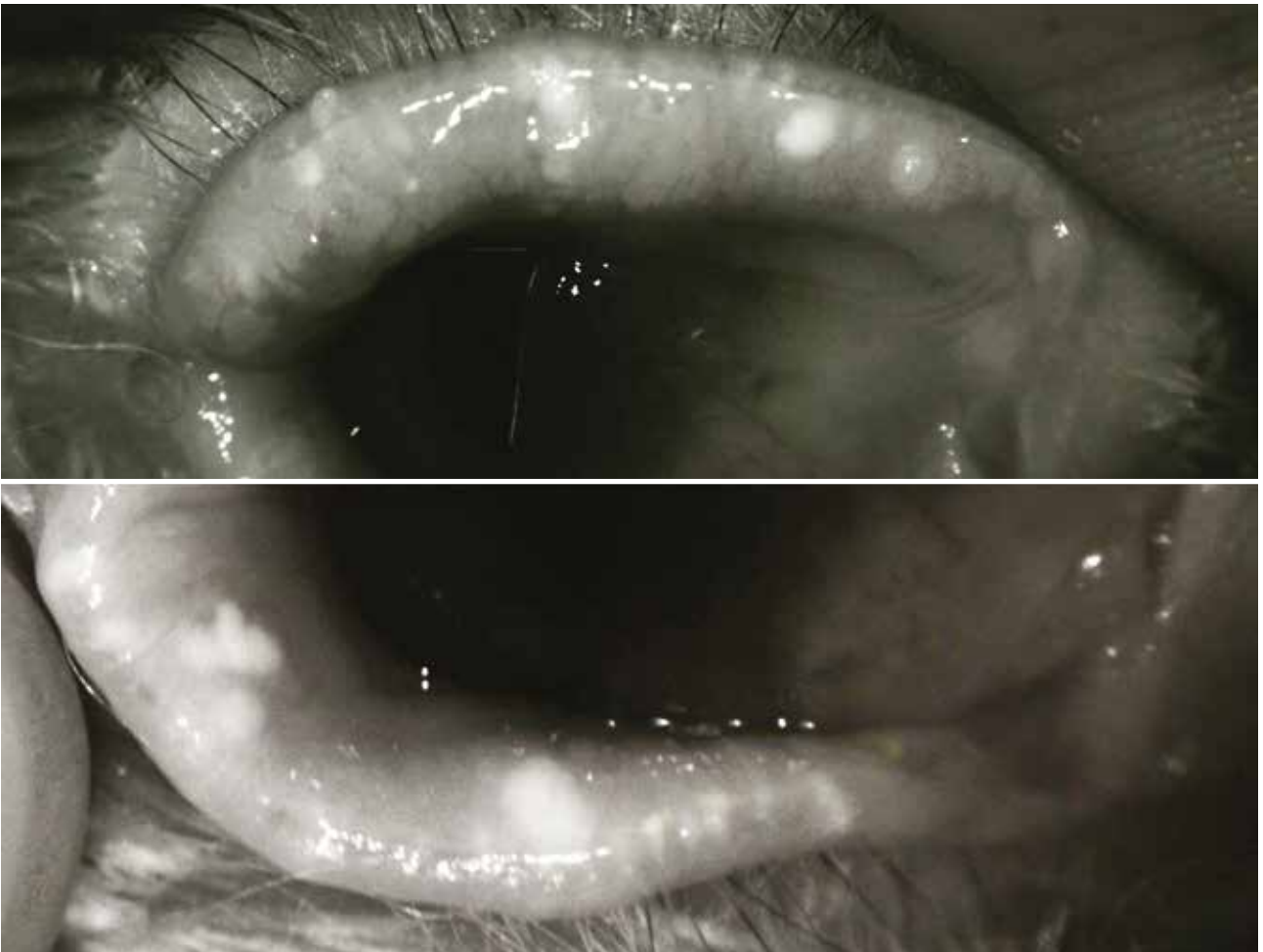
Interferometry



TF LL: right eye 20-30 nm (grade 2 FGS); left eye 20-30 nm (grade 2 FGS).

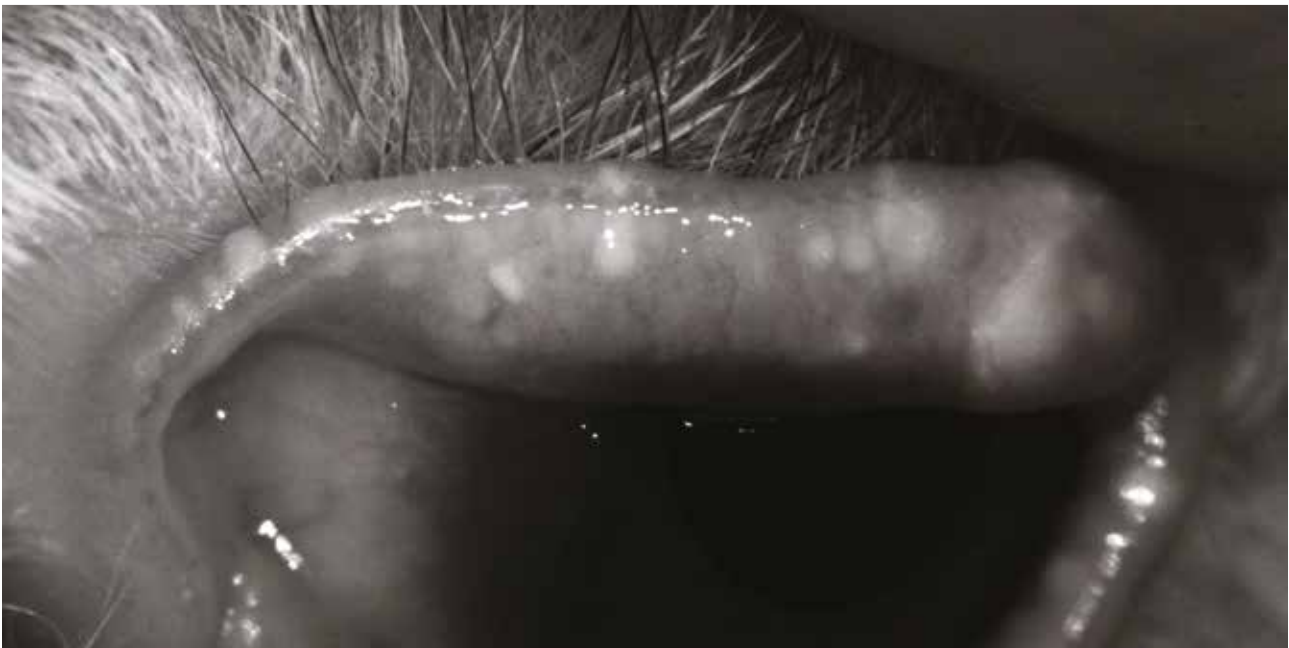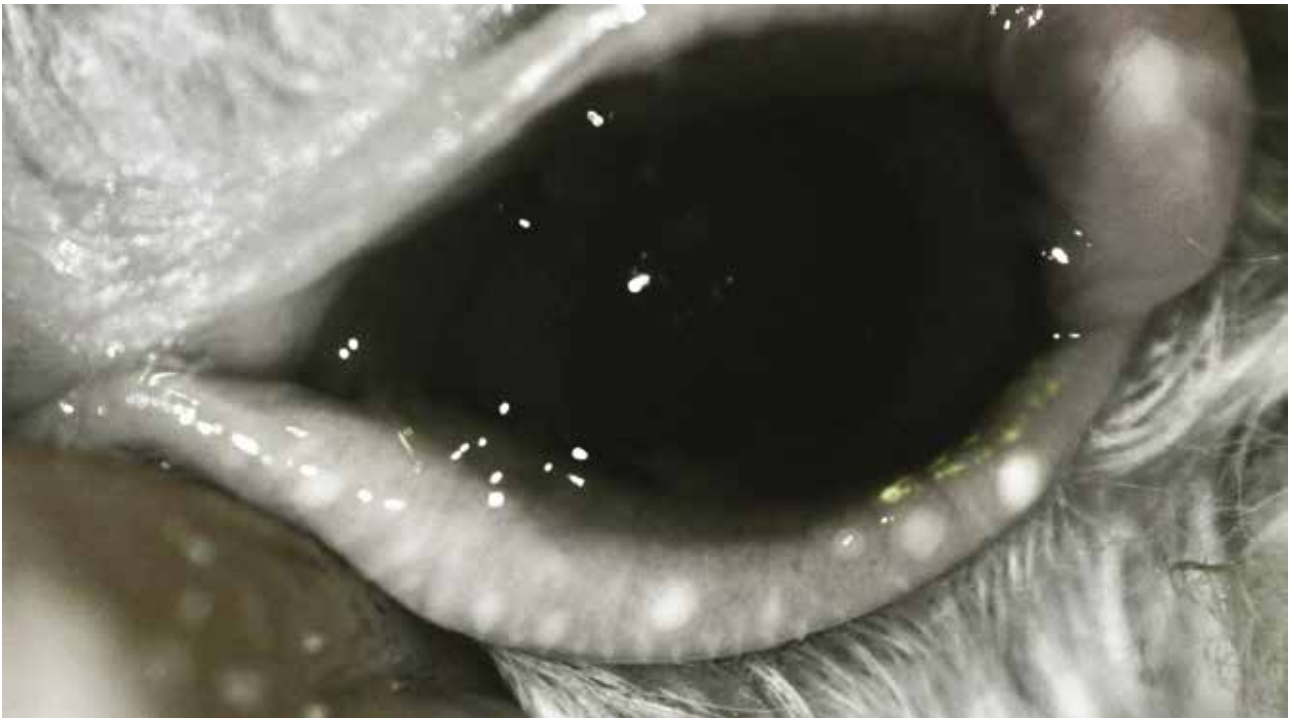Meibography

Right eye



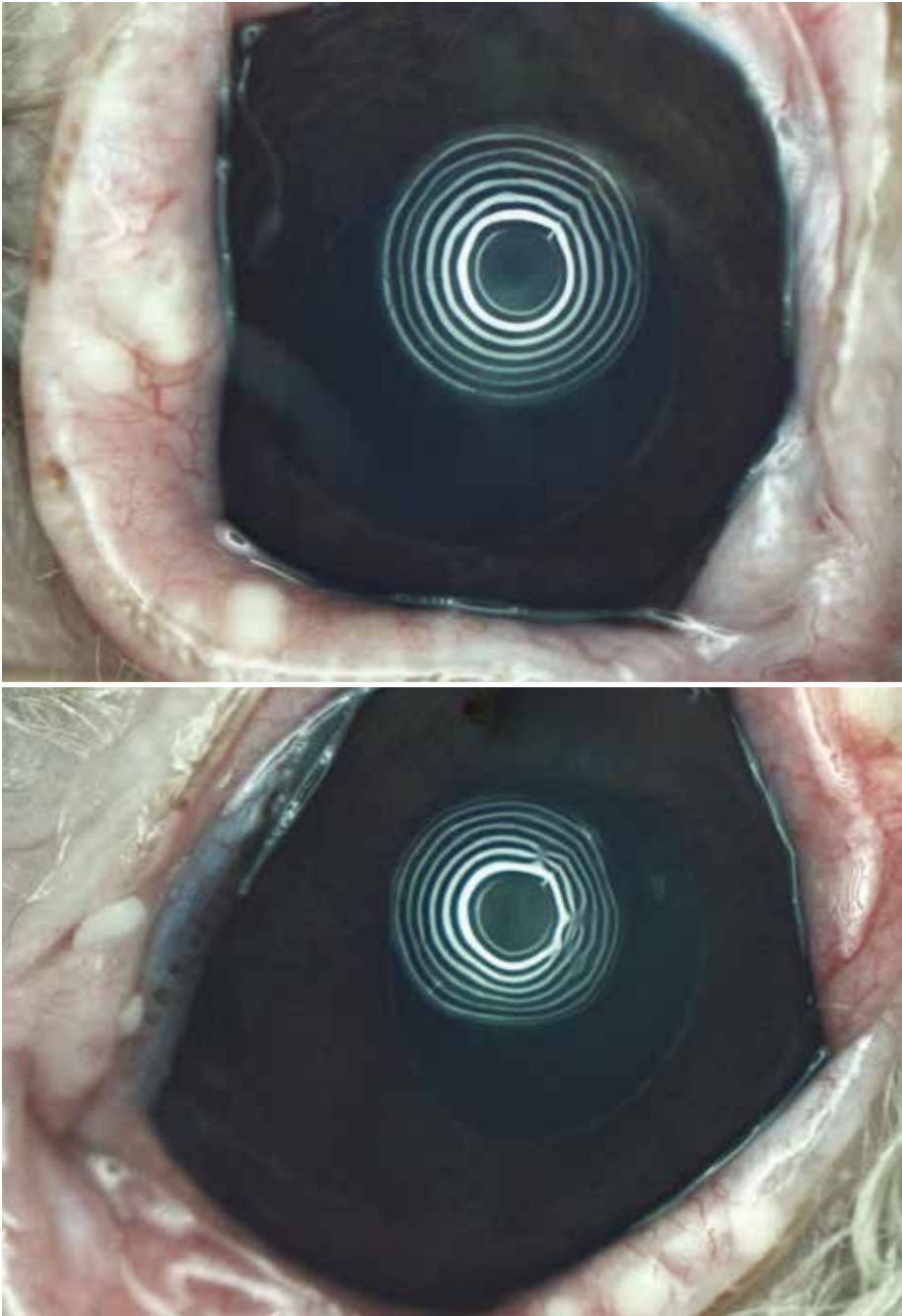
RABBIT

Left eye



The four eyelids are affected by MGD with occlusion of the ductal openings. Multiple chalazia are clearly visible with NCIM in both the upper and lower eyelids.

Placido disc topography



OST: right eye slightly irregular in the dorso-medial quadrant; left eye irregular in the lateral quadrant.

Diagnosis

MGD with TF instability, QLDE and EDE.

In short: MGD, QLDE, EDE.

Authors: Francesca Corsi, Adolfo Guandalini



Case 23 – Wet eyes, loss of meibomian glands

Rabbit: Holland Lop, neutered male, 5 years old.

Clinical history

Chronic mucopurulent discharge in the left eye. Treated with nasolacrimal flushes with physiological solution and systemic NSAIDs.

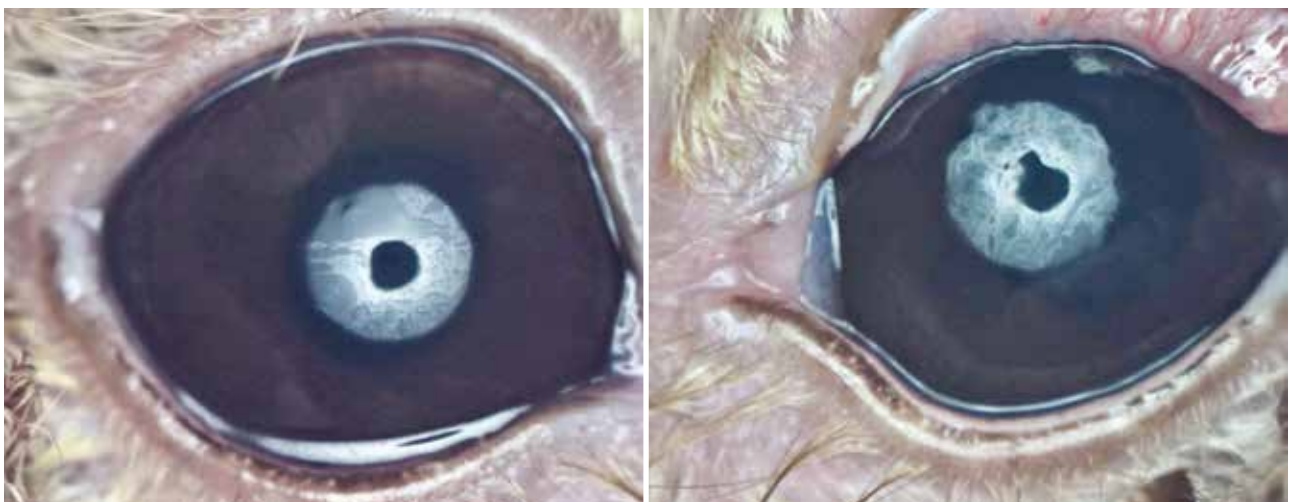Clinical signs at presentation

Left eye: crusty and wet eyelids. Mucopurulent discharge.

Key data after a complete ophthalmic examination

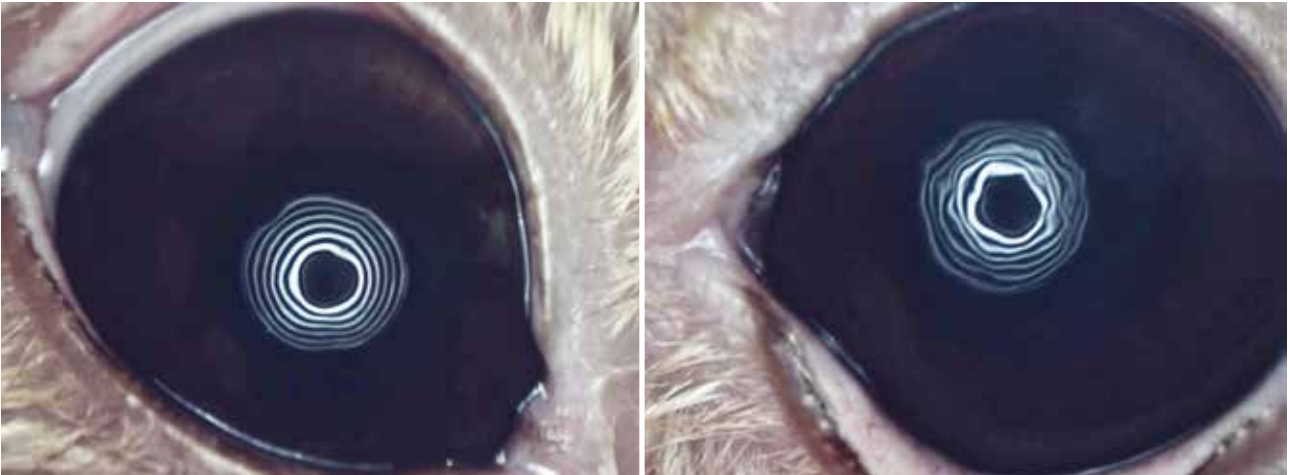
- Wet left eye
- Mucopurulent discharge in the left eye
- Left eye with red eyelids

Interferometry



TF LL: right eye 30-40 nm (grade 3 FGS); left eye 30-40 nm (grade 3 FGS), unstable tear film. Visible waves OU.

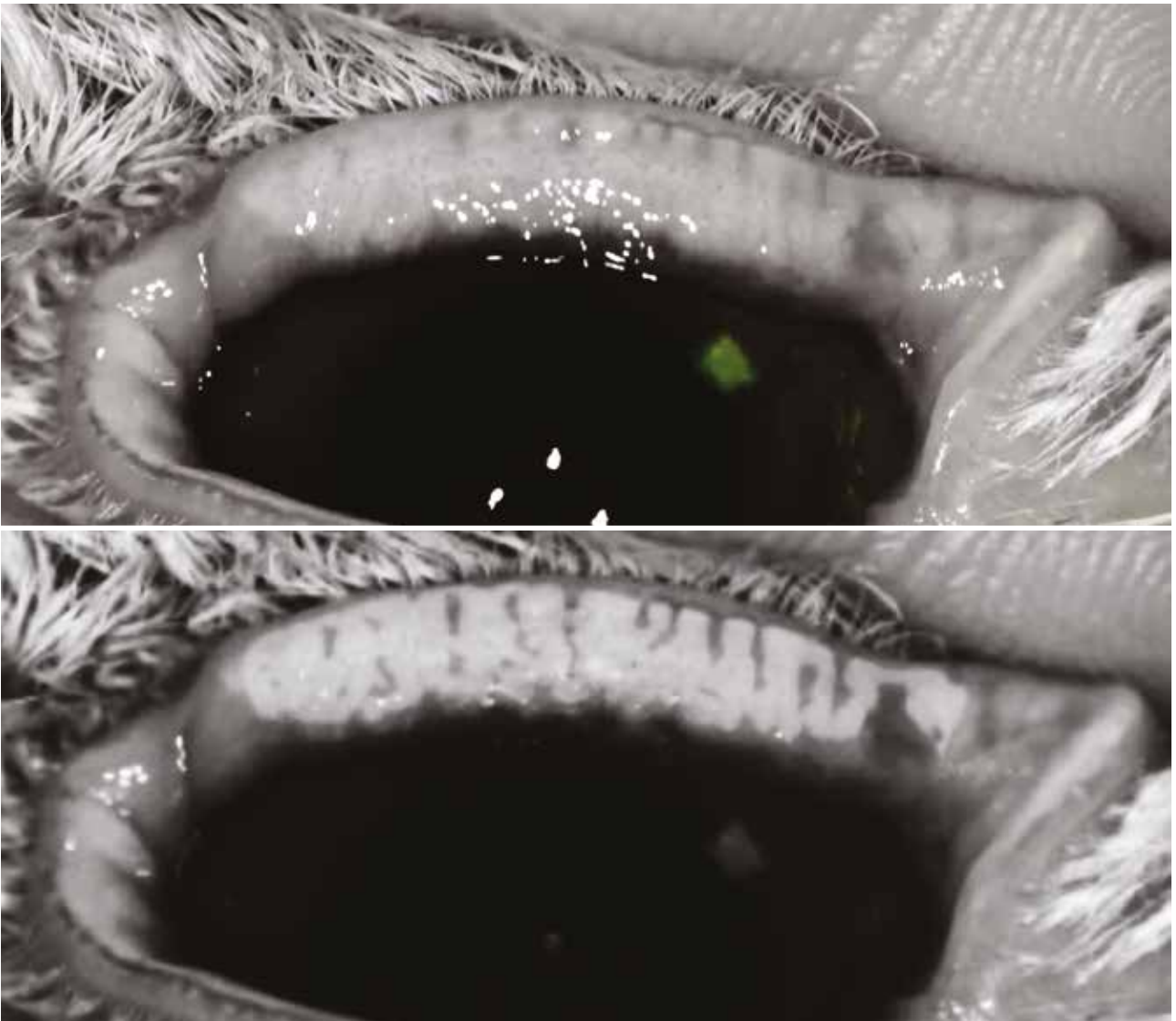
Placido disc topography



The OS topography is altered in the left eye.

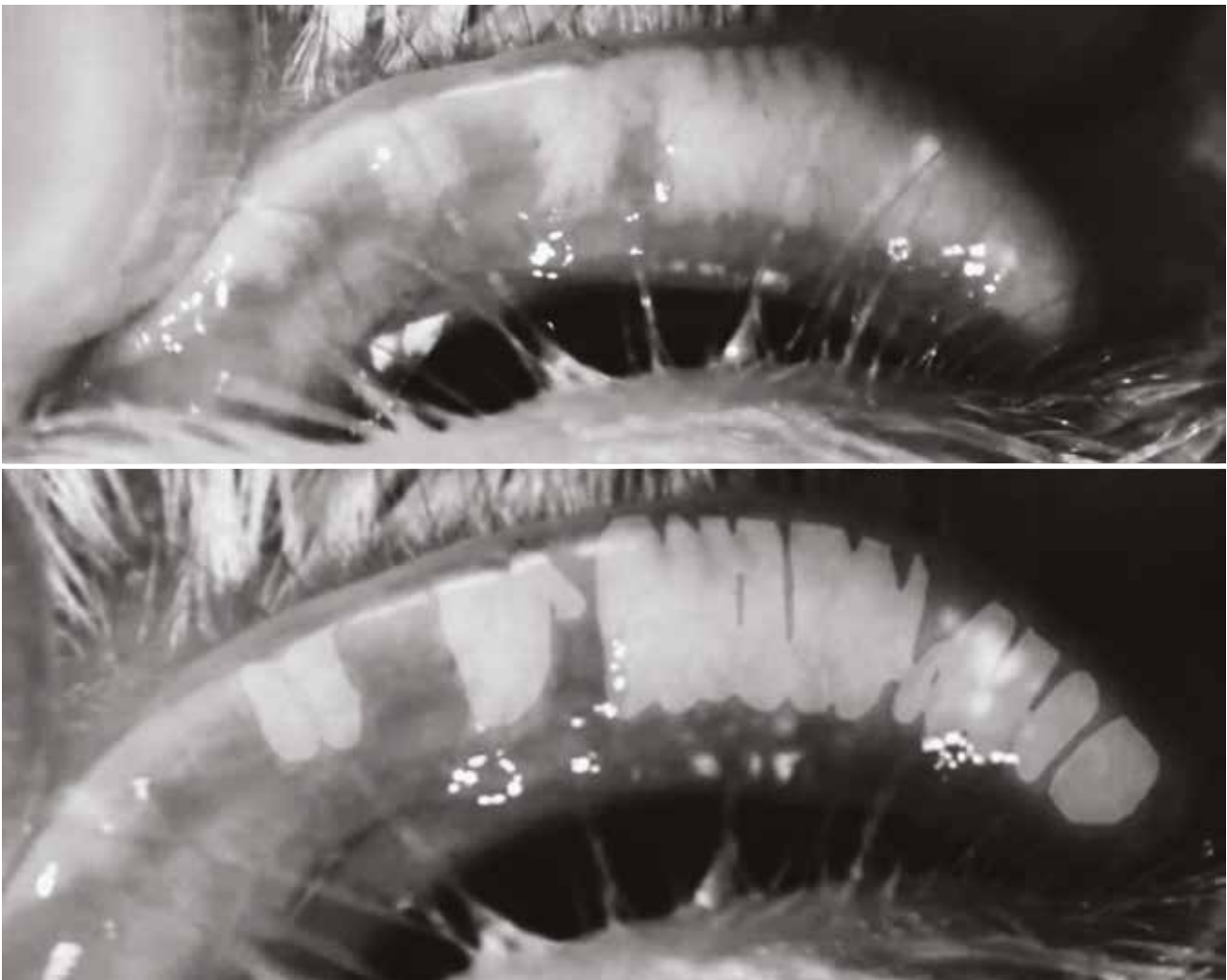
Meibography

Right eye



The MGs loss area in the right eyelids with manual examination is 6%.

Left eye

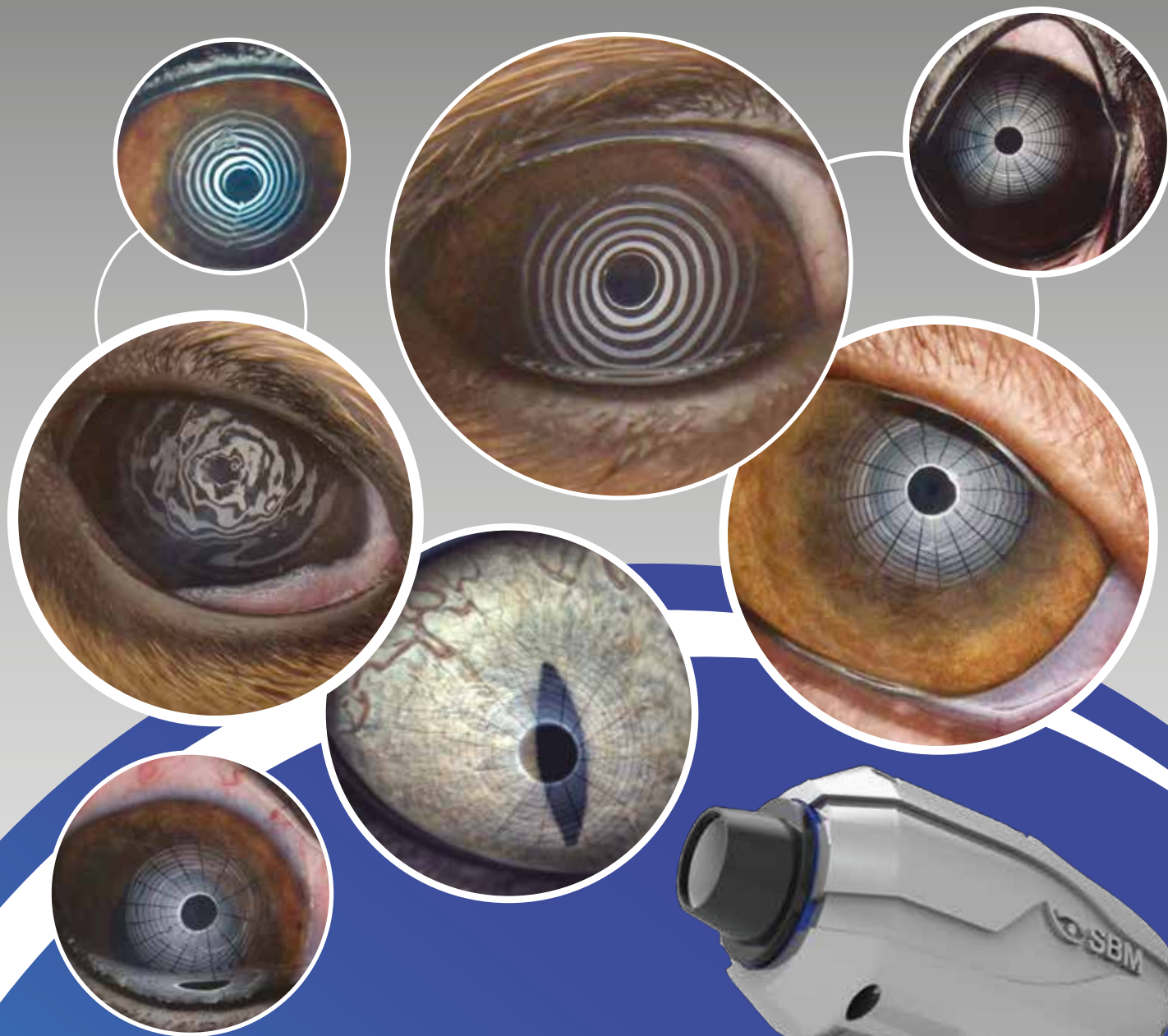

The MGs loss area in the left eyelids with manual examination is 39%.

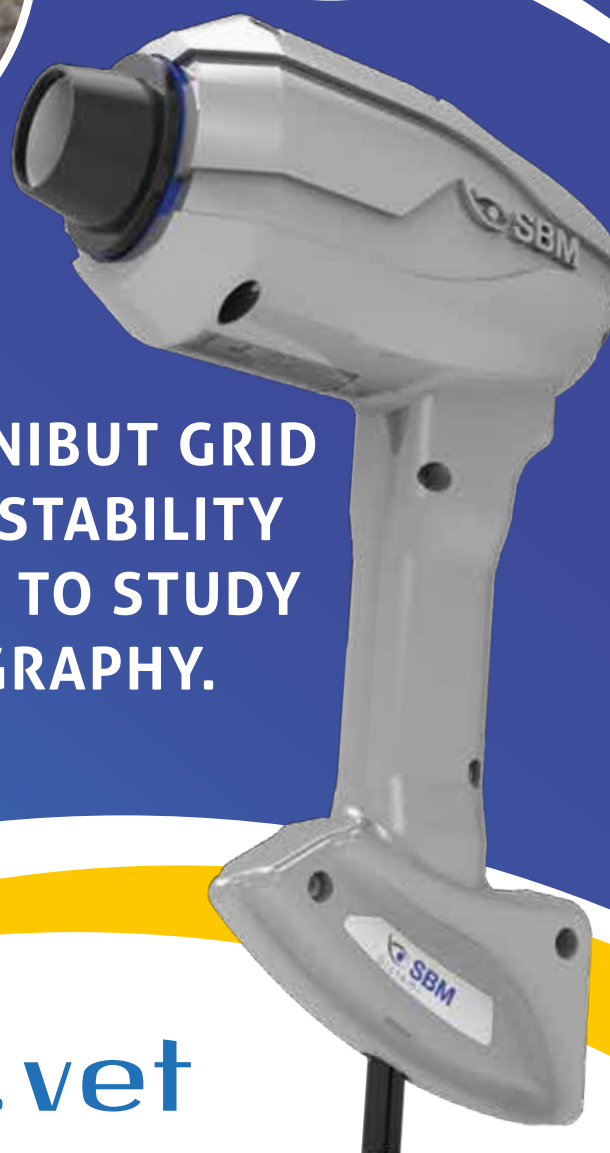
Diagnosis

MGD with tear instability, QLDE and EDE in the left eye.

In short: MGD, QLDE, EDE.



**INTERFEROMETRY WITH NIBUT GRID
TO EVALUATE TEAR FILM STABILITY
AND WITH PLACIDO DISC TO STUDY
OCULAR SURFACE TOPOGRAPHY.**



@.s.a.vet

Authors: Francesca Corsi, Adolfo Guandalini



Case 24 – Congenital anomalies of the meibomian glands

Rabbit: Holland Lop, female, 3 months old.

Clinical history

The owners complain that the eyes are always dirty.

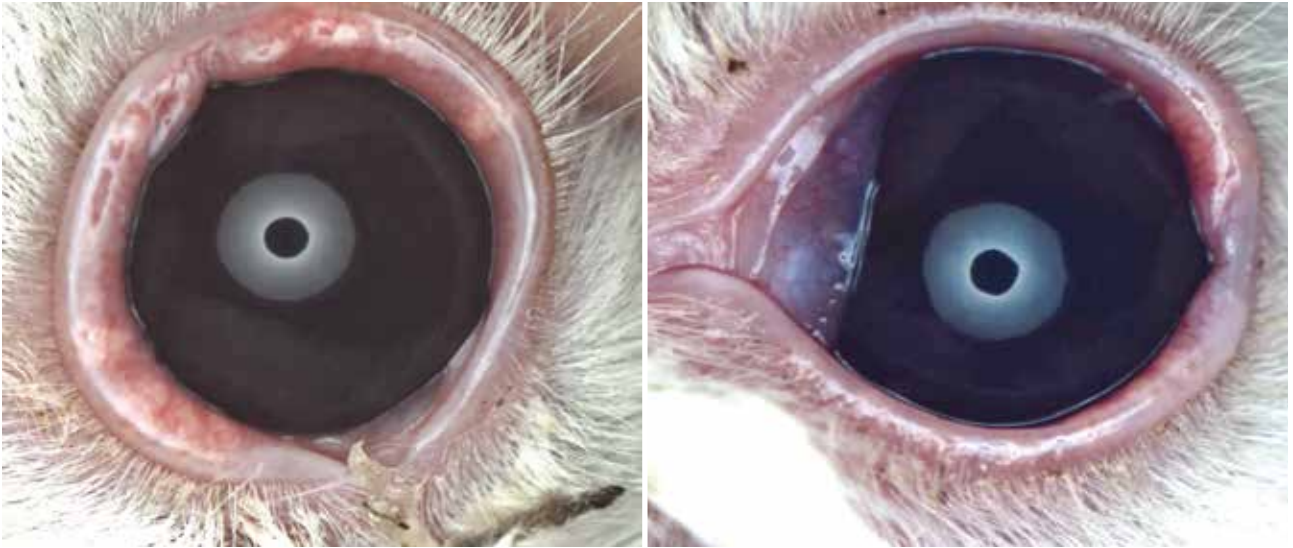Clinical signs at presentation

Crusty eyelids and wet eyes with mucous discharge.

Key data after a complete ophthalmic examination

- Wet eyes
- Mucous discharge
- Crusty eyelids
- STT: 10 mm/min RE; 6 mm/min LE
- Osmolarity: 335 mOsm/L RE; 354 mOsm/L LE

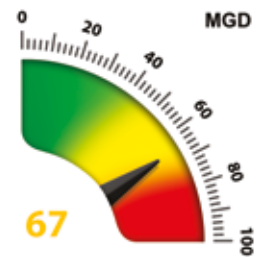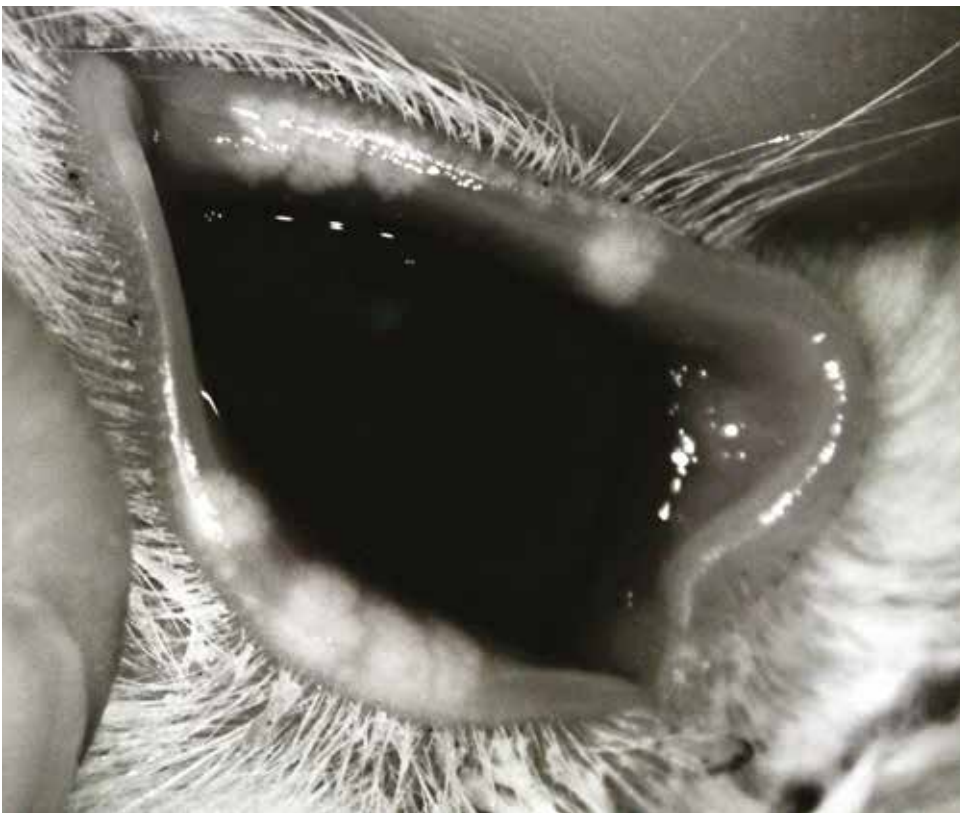Interferometry



TF LL: right eye 20-30 nm (grade 2 FGS); left eye 20-30 nm (grade 2 FGS). No visible waves OU.

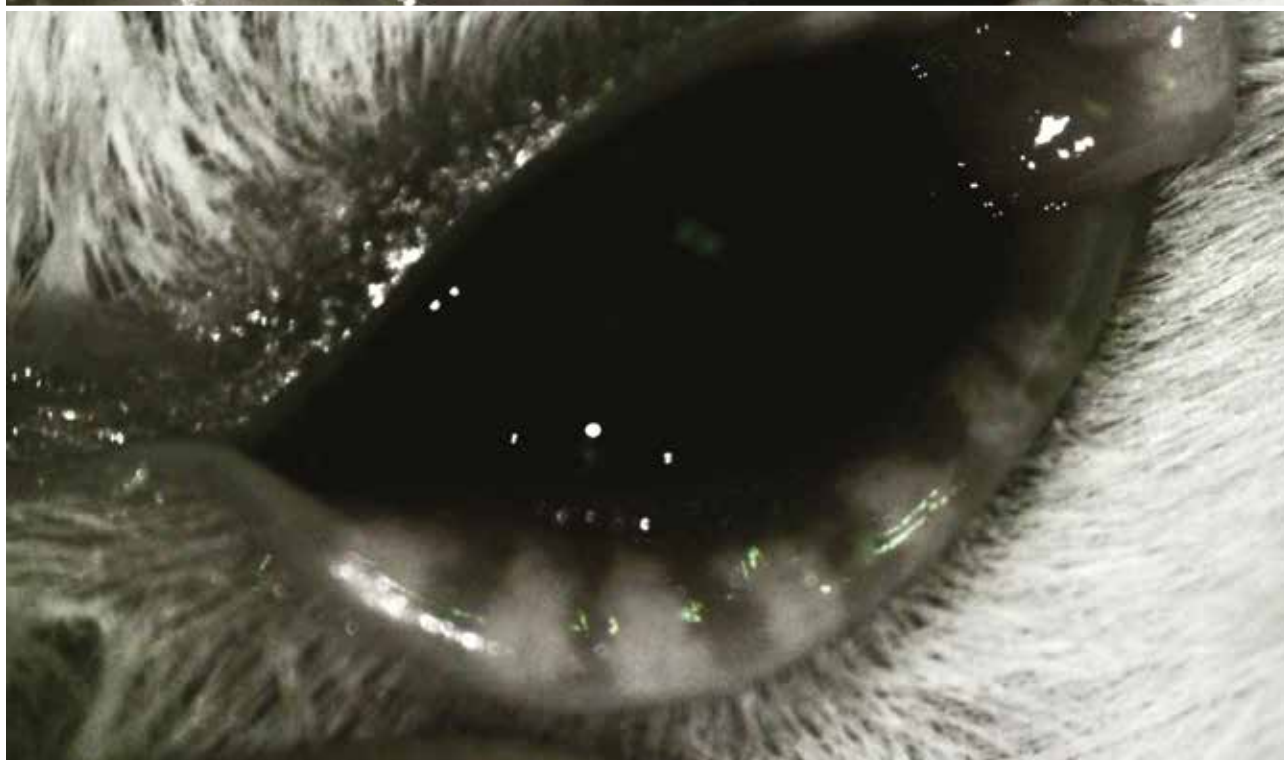
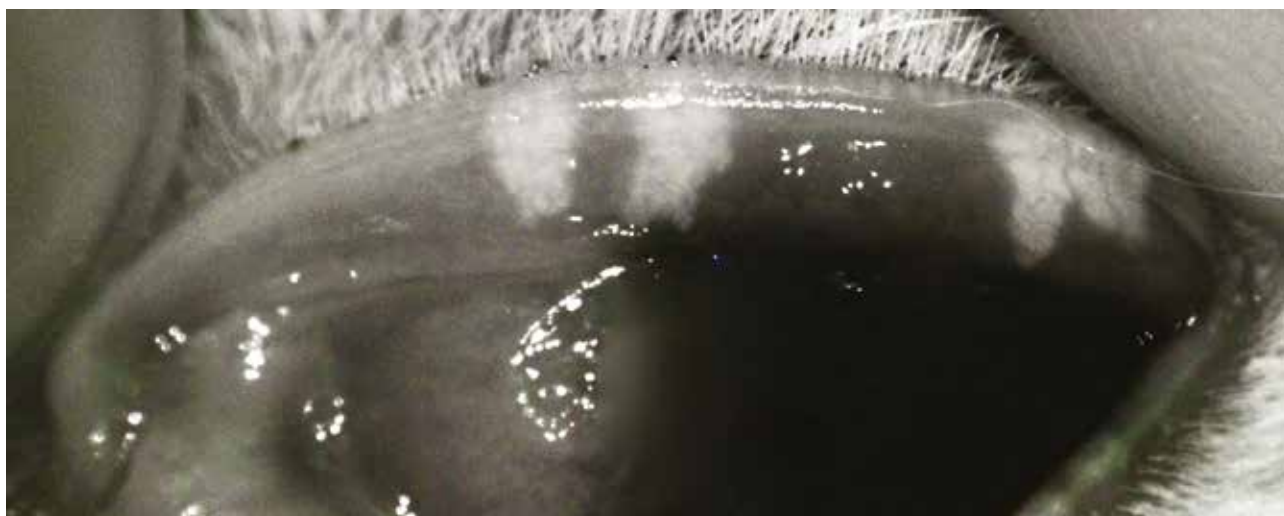
Meibography

Right eye

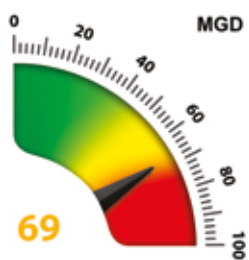

The MGs loss area with manual examination is 67%.

Left eye

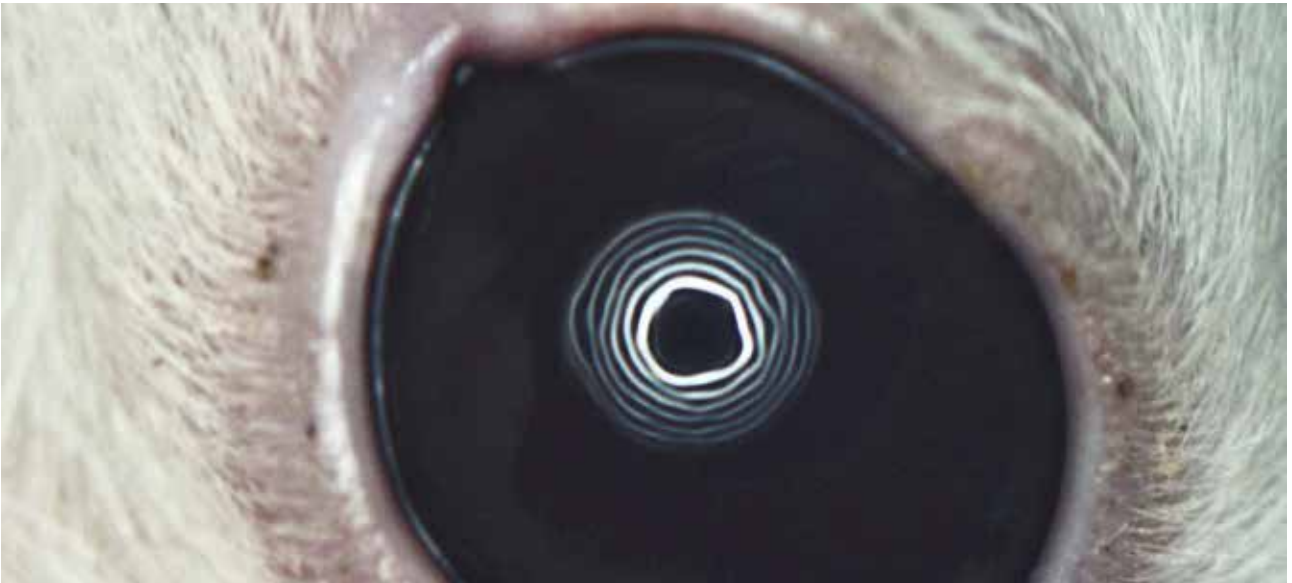


The MGs loss area with manual examination is 69%.



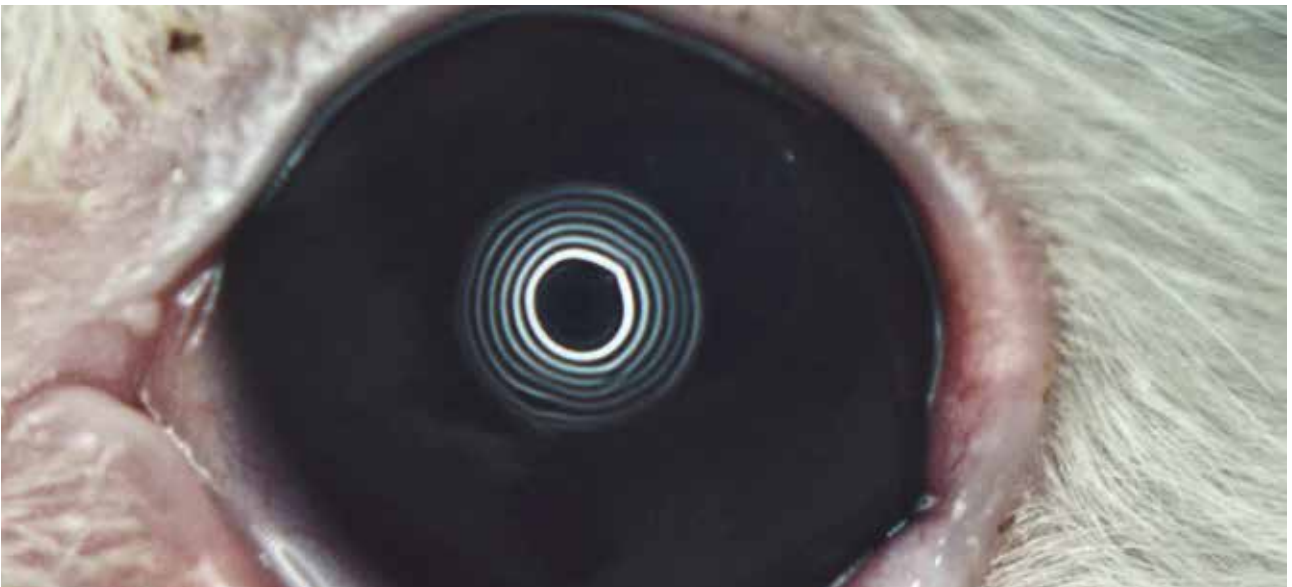
Placido disc topography

Right eye



OST: right eye irregular in all quadrants.

Left eye




OST: left eye irregular in the ventral quadrant.

Diagnosis

Suspected congenital anomalies of the meibomian glands.

In short: MGD, QLDE, EDE.

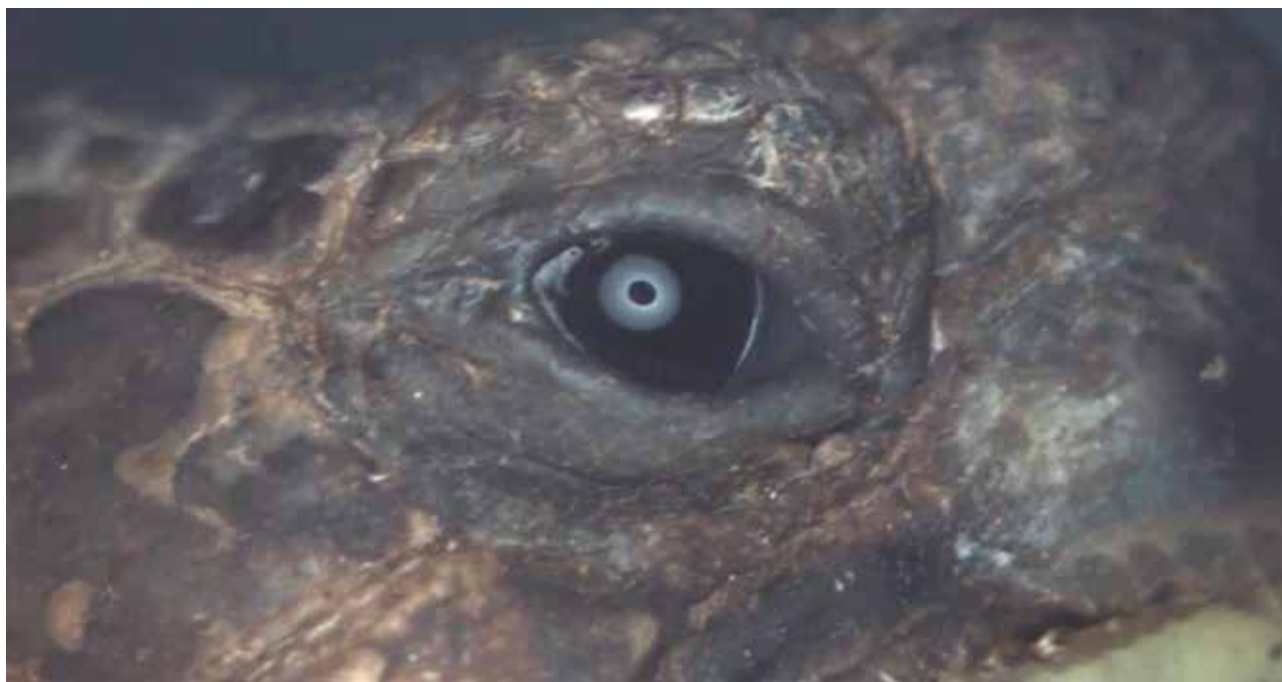Authors: Nunzio D'Anna, Marta Viñas Portillo



Case 25 – TF examination in an exotic species

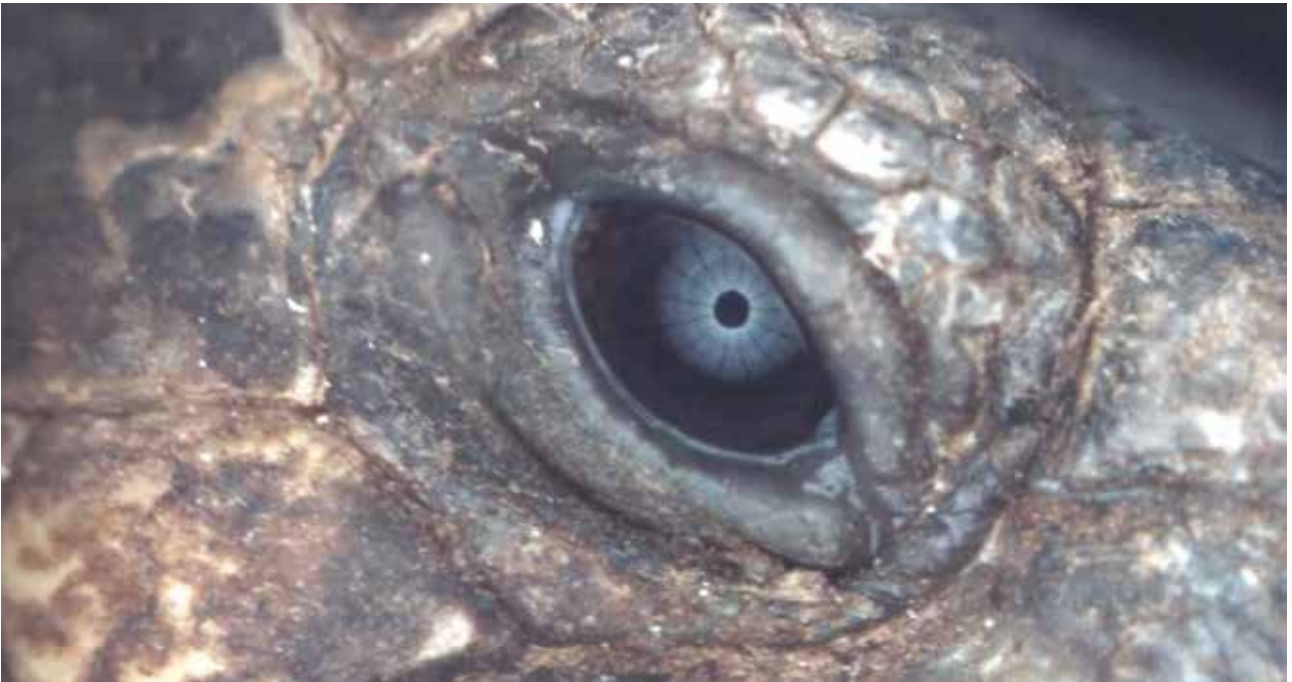Turtle: Testudo hermanni, male, 4 years old.

Interferometry



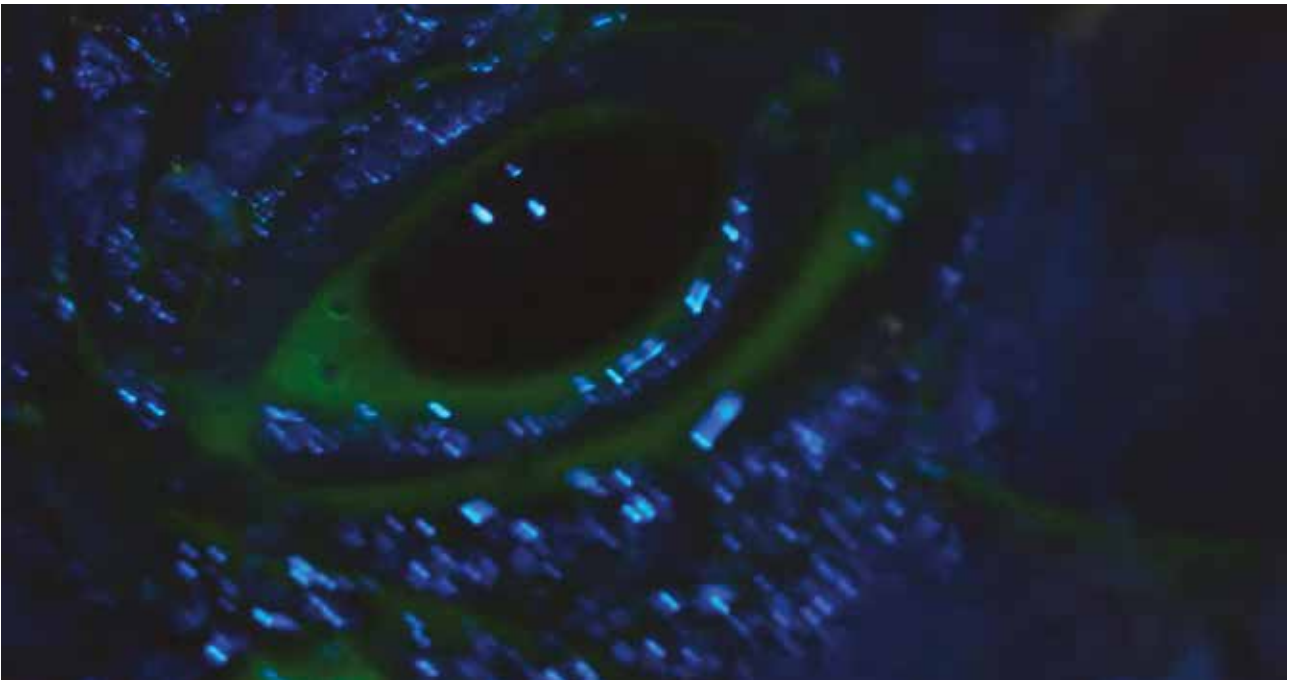
*Interferometry shows a significant difference in LLT between species.
There are no published data concerning a clinically healthy Turtle.
Estimated LLT 60 nm.*

NIBUT



The NIBUT can also be used for the evaluation of corneal topography.

BUT



*To the best of our knowledge, BUT has not been yet determined for this species.
After 20 seconds the tear film did not show interruptions due to evaporation, it has been considered normal.*

Authors: Nunzio D'Anna, Marta Viñas Portillo



Case 26 – Corneal degeneration secondary to presumed cholesterol deposits.

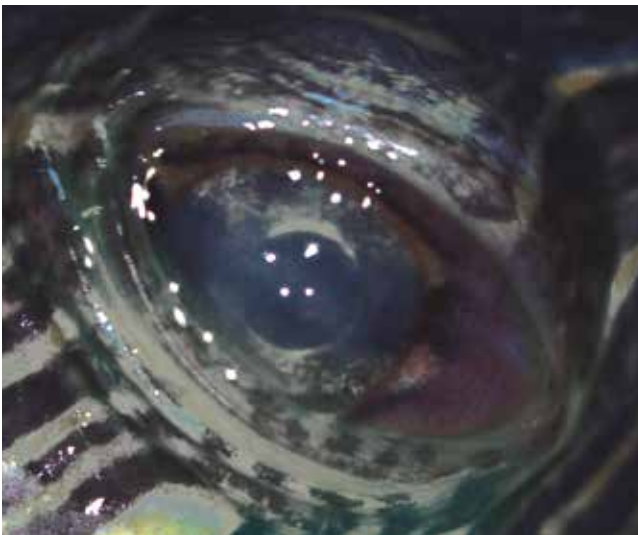
Turtle: *Trachemys scripta elegans*. The following pictures are from a female, 25 years old.

Clinical history

Cloudy eyes and hypercholesterolemia.

Clinical signs at presentation

Bilateral discharge and corneal opacification.



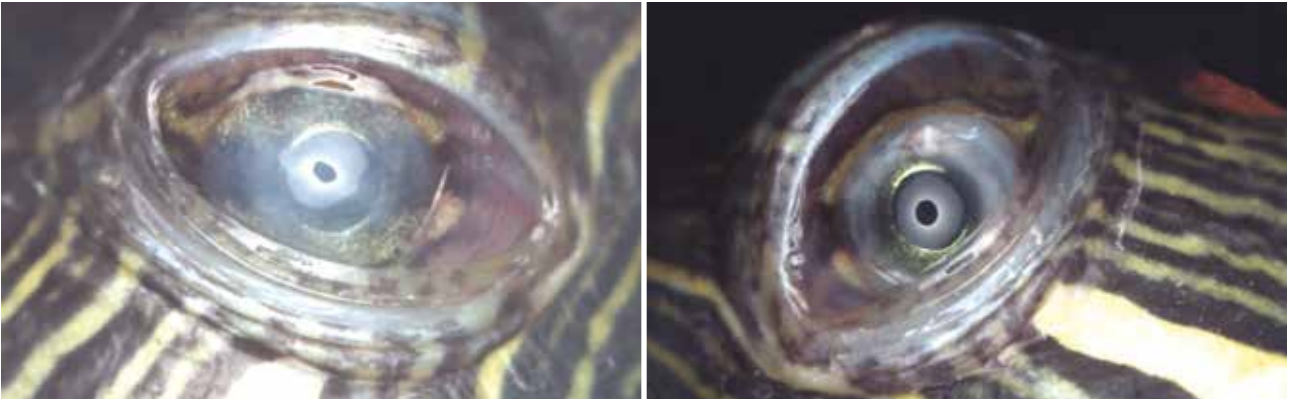Key data after a complete ophthalmic examination

Bilaterally:

- Severe diffuse bilateral conjunctival hyperemia.
- Corneal mineral deposits.
- Moderate peripheral circular shaped corneal opacification.
- Diffuse superficial corneal vascularization.

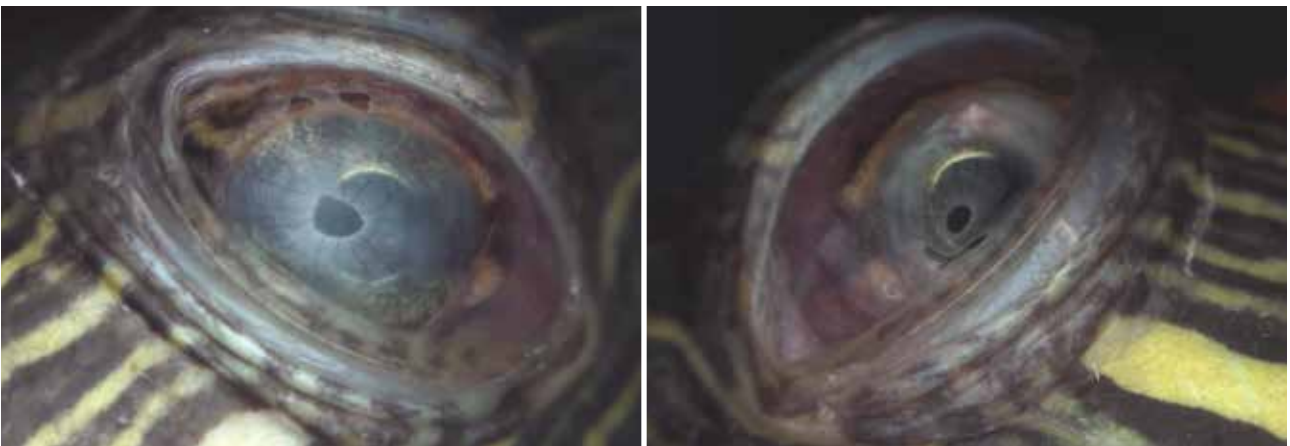
Left eye: Circumscribed corneal abscess localized at 1 o'clock.

Interferometry



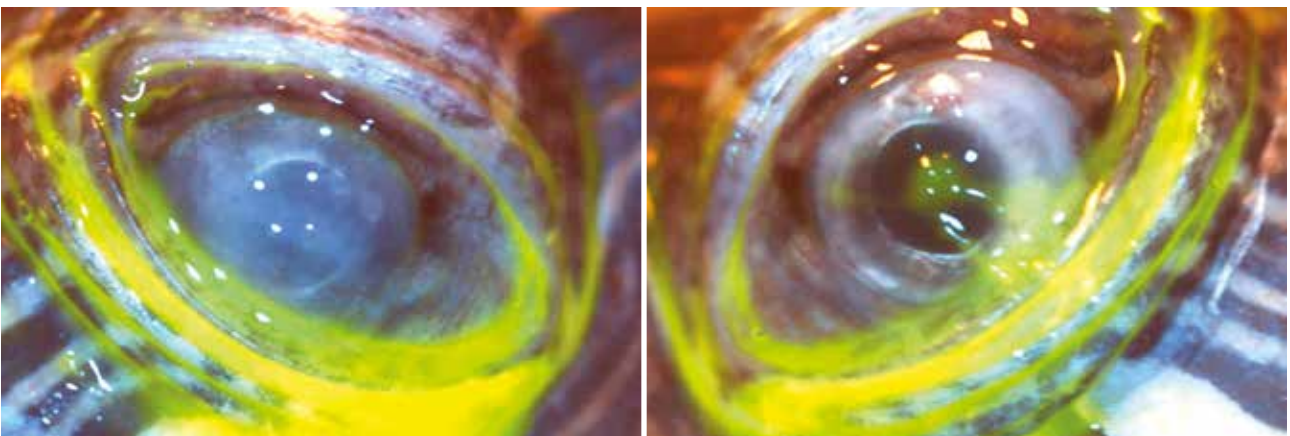
*There is no smooth pattern of the cornea and this is more obvious in the left eye.
Estimated LLT 60 nm.*

NIBUT



The use of the NIBUT grid shows an alteration of the corneal topography.

BUT



*To the best of our knowledge, BUT has not been yet determined for this species.
After 20 seconds the tear film did not show interruptions due to evaporation, it has been considered normal.
In the left eye there is mucus on the corneal surface.*

Diagnosis

Corneal irregularities due to corneal degeneration.

Authors: Nunzio D'Anna, Marta Viñas Portillo

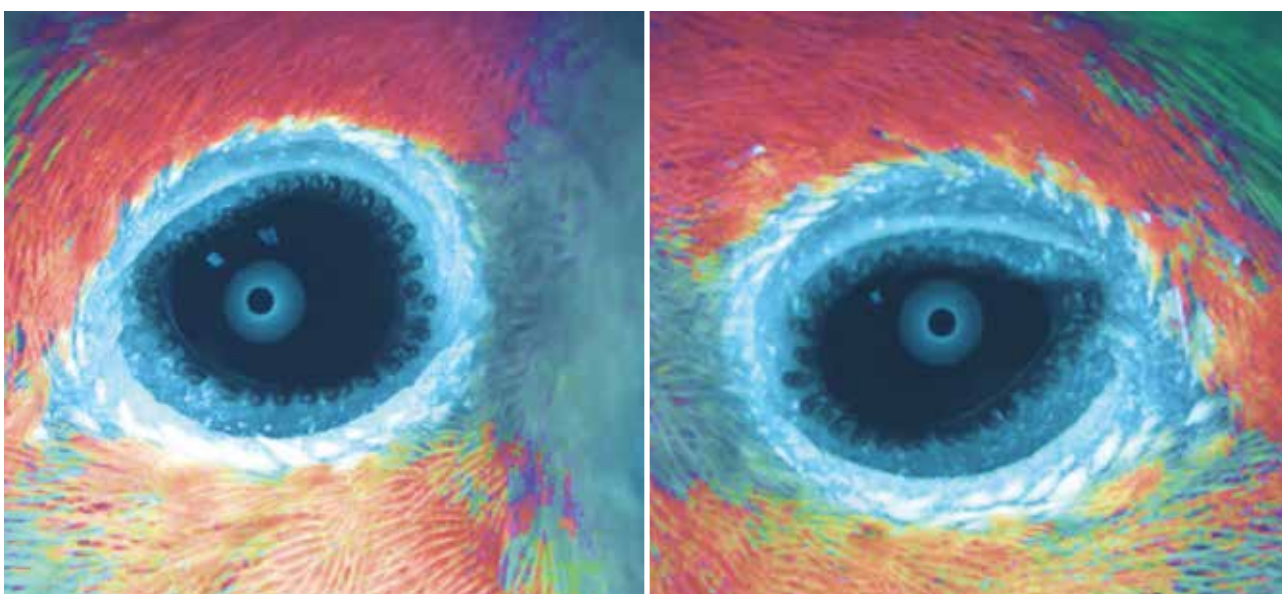


Case 27 – TF evaluation in a parrot

Parrot: Wally Agapornis, inseparabile parrot.

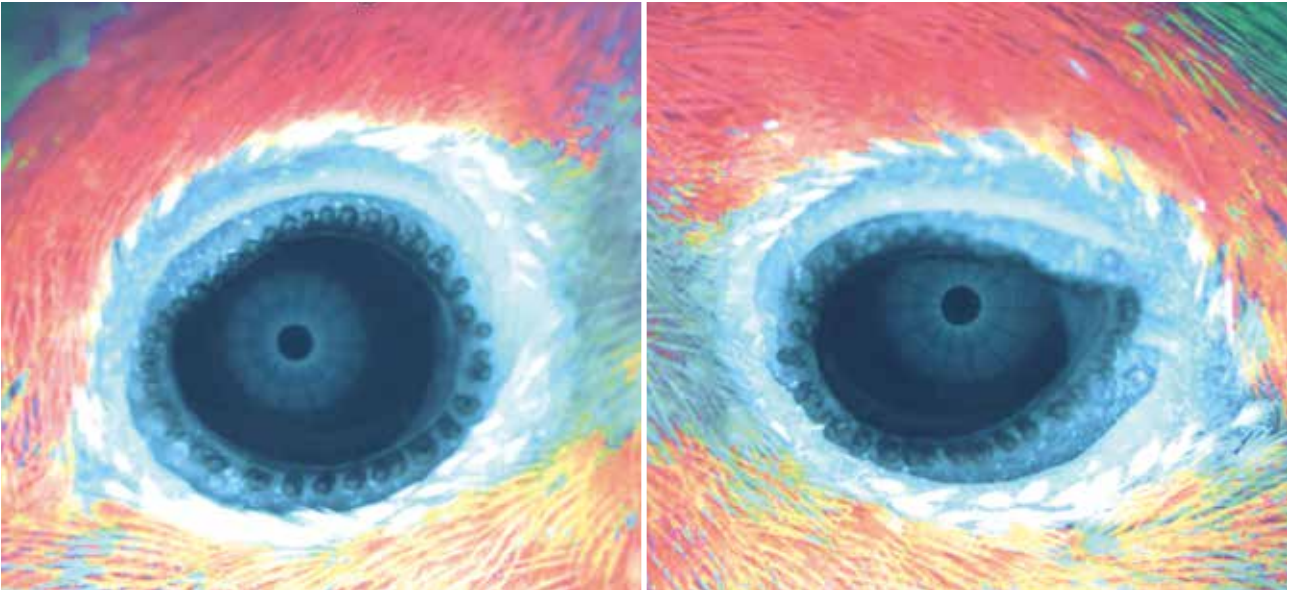
The interferometry and NIBUT pictures are from a 3 years old parrot.

Interferometry



Estimated LLT 60 nm.

NIBUT



The NIBUT grid can also be used for the evaluation of corneal topography.

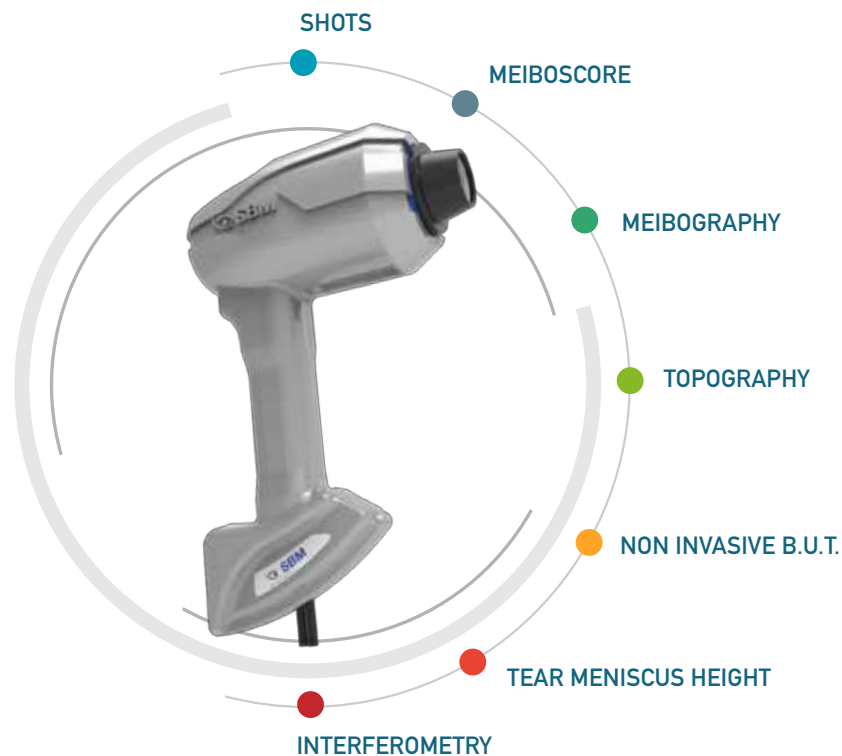OSA-VET MACRO-PHOTOGRAPHY

The OSA-VET may be used with interferometry to take macro-shots or record videos of the ocular surface, eyelids, and conjunctiva.

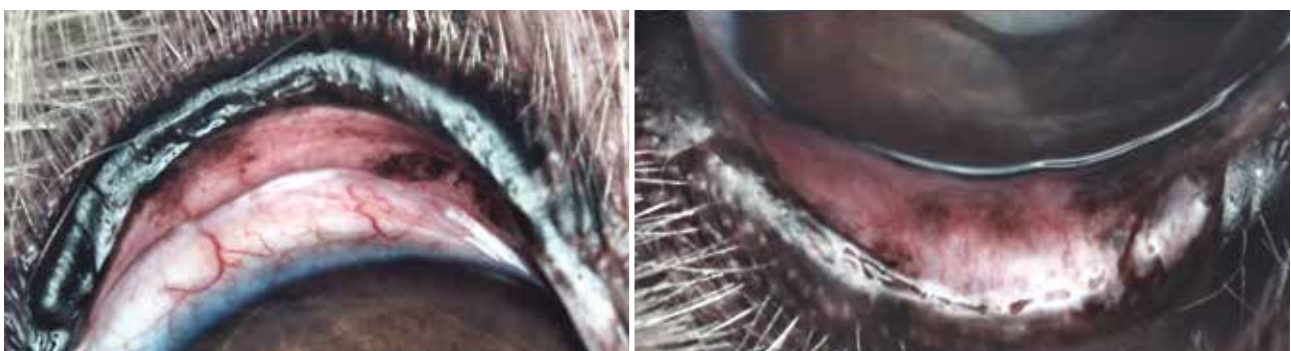
The infrared leds used for meibography are also useful to highlight the size and boundaries of focal pigmented spots of the iris. In the next few pages some pictures are shown as an example.

OSA-VET EXAMINATION

Standard procedure



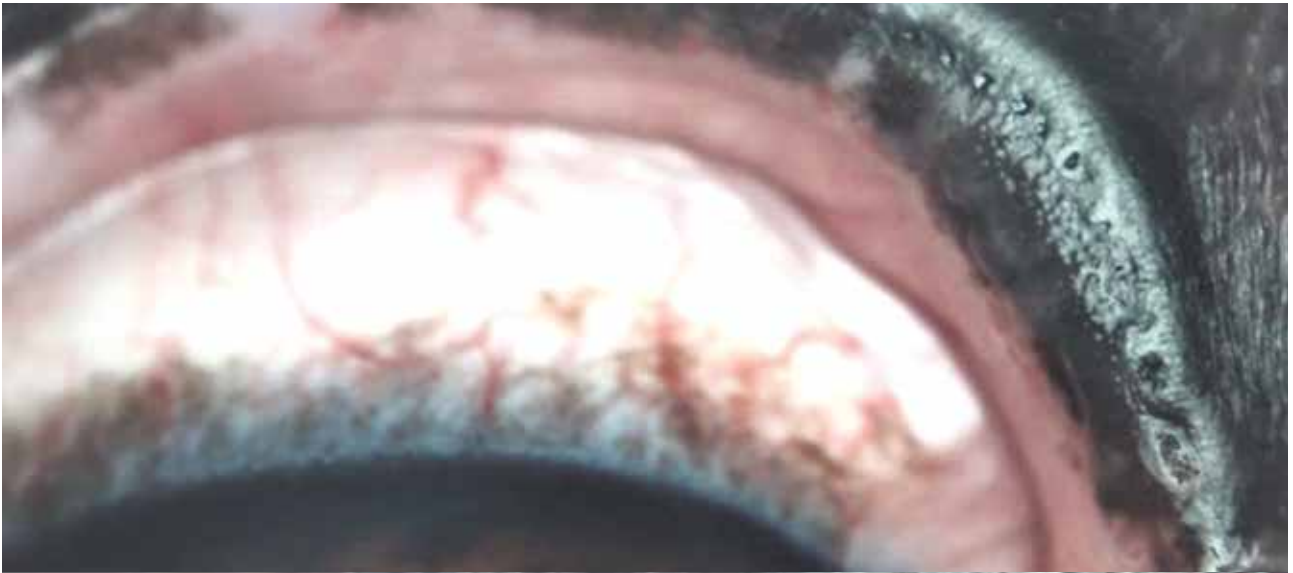
MGS DUCTAL OPENINGS AND LIPID SECRETION ON THE EYELID MARGIN



Bichon Frisé male, 8 years old. Main clinical signs at presentation: increased aqueous production with epiphora and red, wet eyes. Diagnosis: outcome of blepharitis with eyelid scarring, MGD, keratoconjunctivitis and EDE.

The upper eyelid is extensively deformed, a few displaced MGs ductal openings are visible, some are occluded. Only a small amount of lipids is visible with interferometric reflection on the eyelid margin.

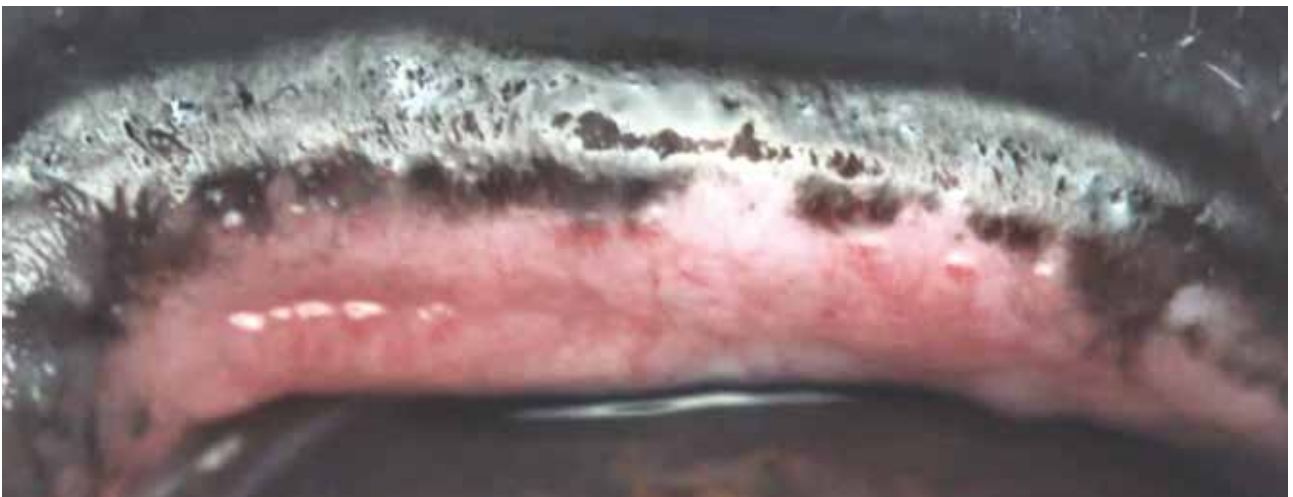MGs secretion is spread over the conjunctival surface of the lower eyelid, the lipid layer highlights the tear meniscus at the conjunctival lower fornix (OSA-VET shots).



Crossbred female, 6 years old, right eye. Main clinical signs at presentation: 42 blinks/minute (only 4 complete), increased aqueous secretion with epiphora and wet eyes OU.

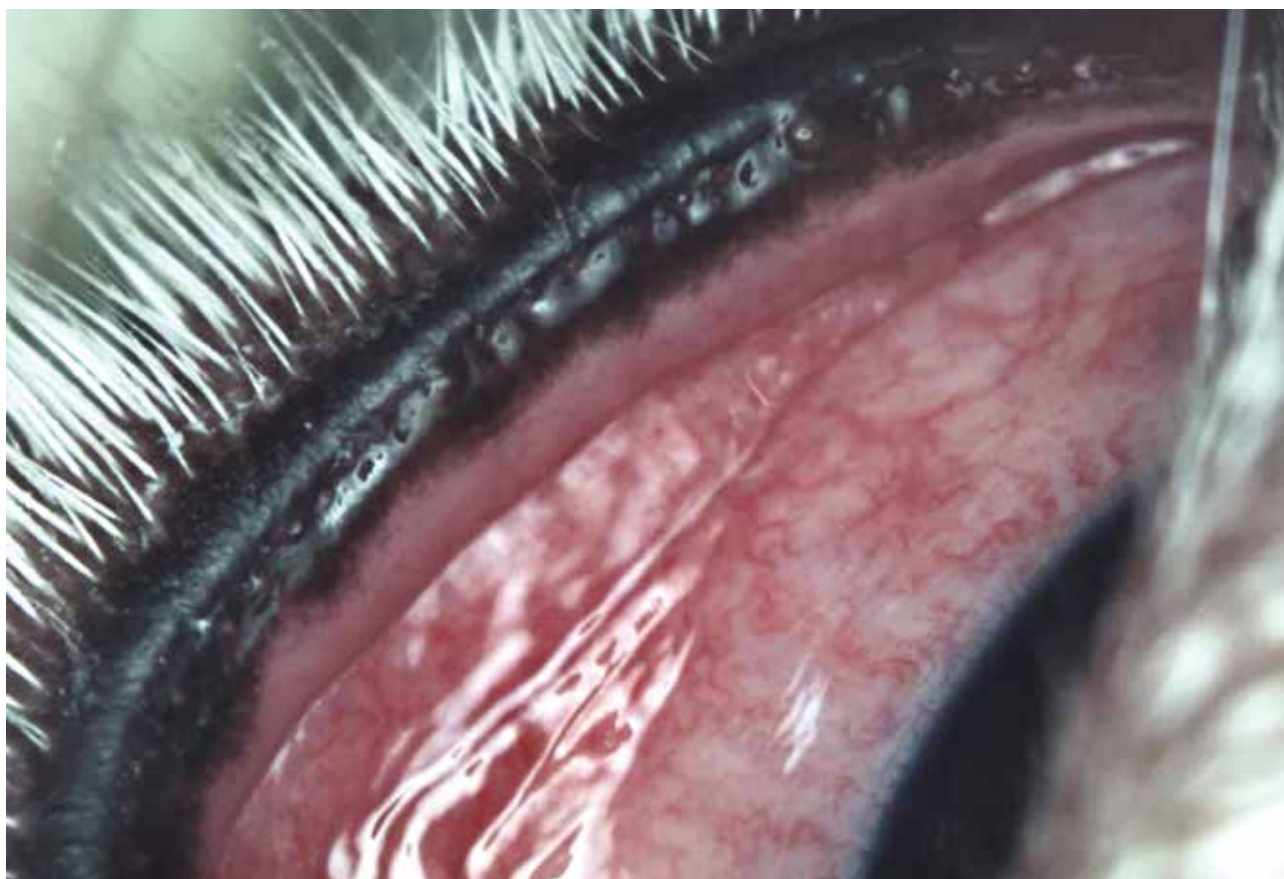Diagnosis: MGD with extensive scarring and occlusion of most MGs ductal openings, EDE.

Scarring of the eyelid margin involving some MGs ductal openings is visible (OSA-VET shot).



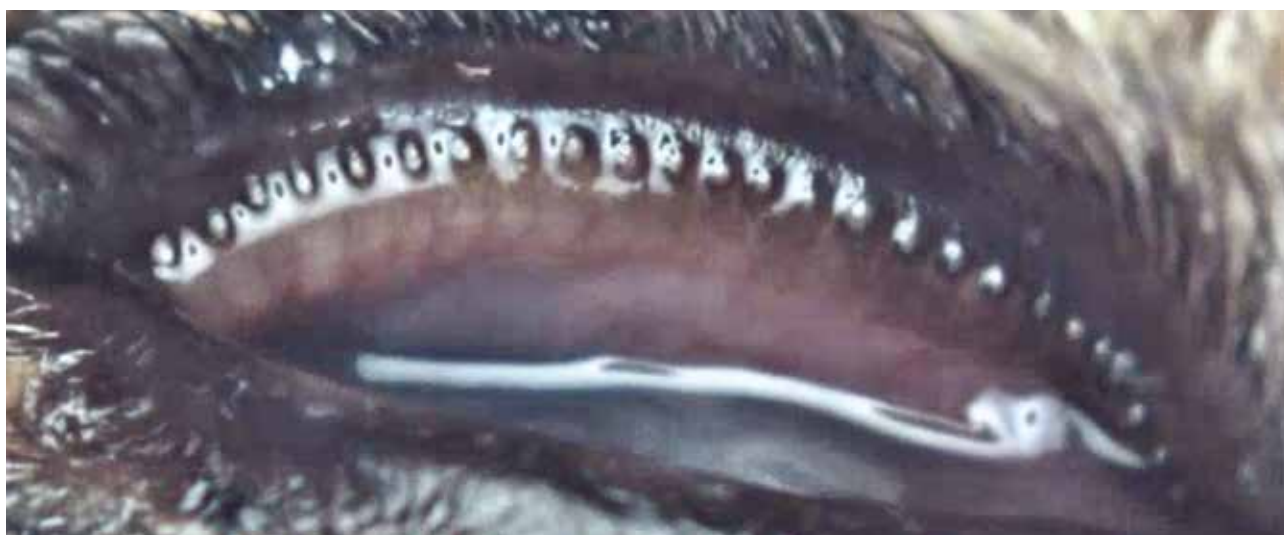Left eye of the previous dog. A mild interferometric oily reflection is present over the eyelid margin.

A little amount of lipid secretion is visible only in the centre (OSA-VET shot).



English Bulldog female, 3 years old. Main clinical signs at presentation: red, wet eyes with mucopurulent discharge. Diagnosis: blepharo-conjunctivitis and keratitis.

The MGs ductal openings are sunken along the so-called grey line. A mild lipidic secretion is visible in some areas due to the interferometric reflection (OSA-VET shot).

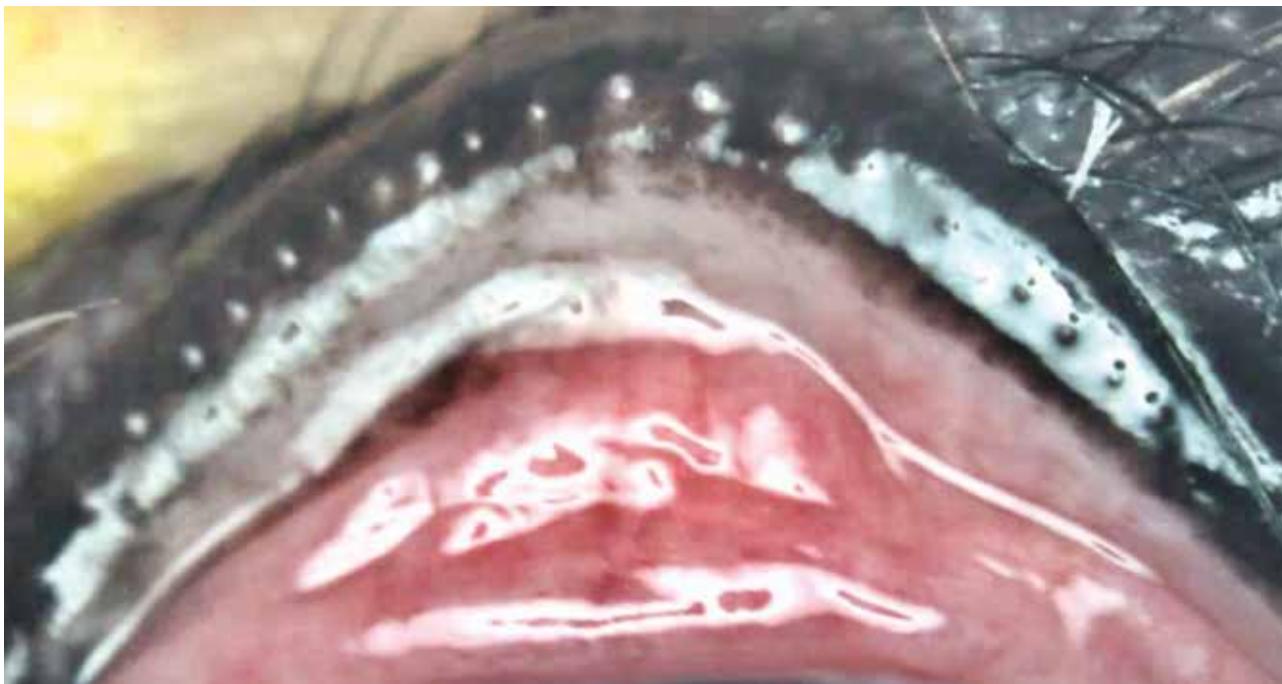

DSH male, 1 year old. Main clinical signs at presentation: extensive involvement of the ocular surface with kerato-conjunctivitis, symblepharon and pseudo-pterigium.

Diagnosis: herpes-virus infection.

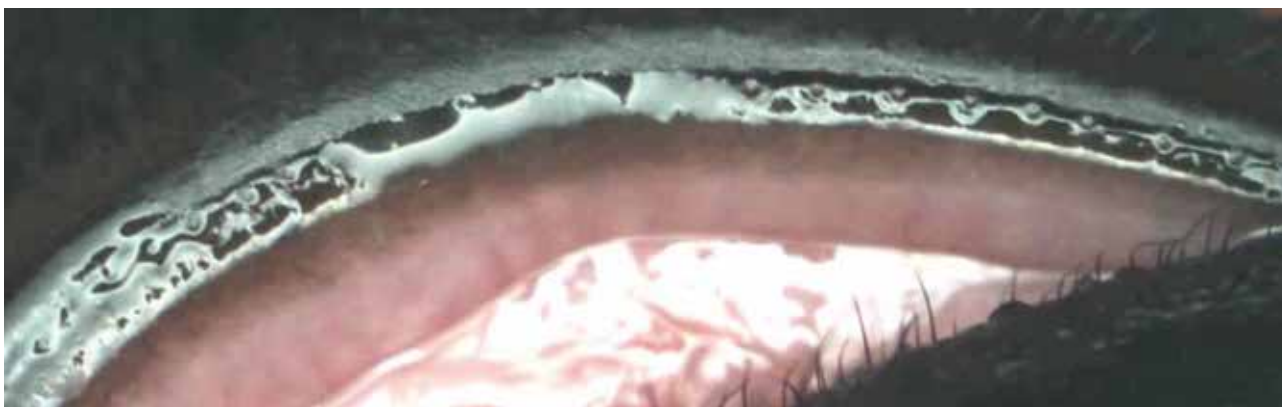
The MGs ductal openings and the lipidic secretion are visible along the eyelid margin (OSA-VET shot).

LIPIDS ON THE EYELID MARGIN



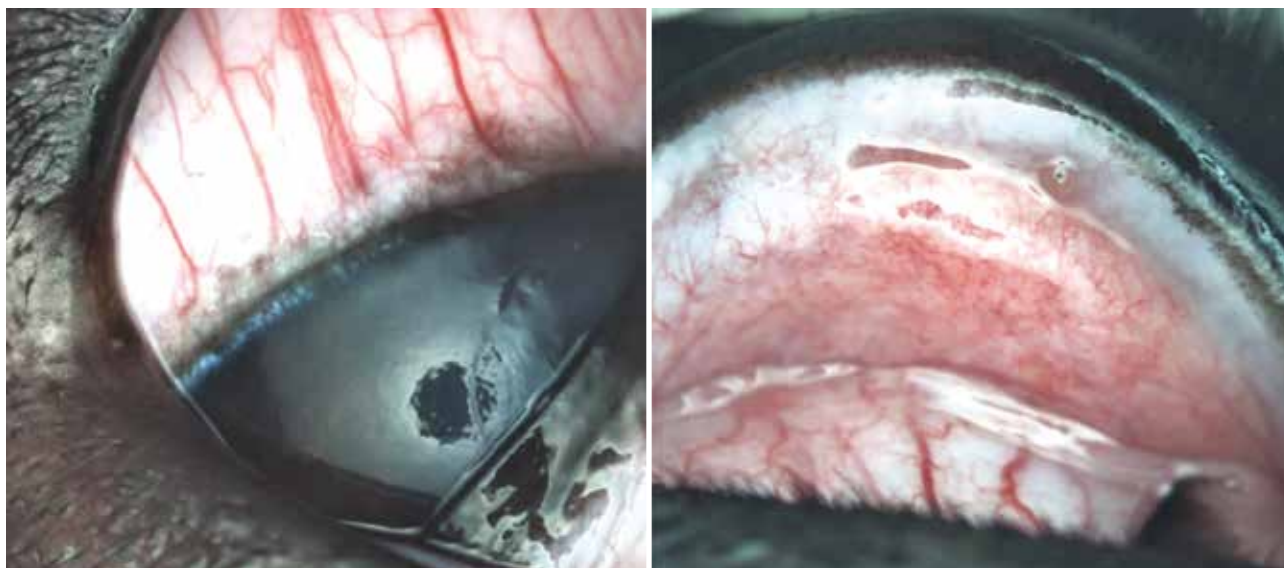Shih Tzu female, 6 years old, left eye. Main clinical signs at presentation: red, wet eyes with increased aqueous production and epiphora OU. Diagnosis: outcome of blepharo-conjunctivitis, keratitis, MGD with extensive MGs ductal occlusion, EDE.

Most ductal openings are plugged with dense secretion. A normal distribution of lipids is evident only over the temporal third of the eyelid margin (OSA-VET shot).



Cavalier King Charles Spaniel male, 9 months old. Main clinical signs at presentation: red eye. Diagnosis: conjunctivitis. The lipid secretion is clearly visible on the eyelid margin (OSA-VET shot).

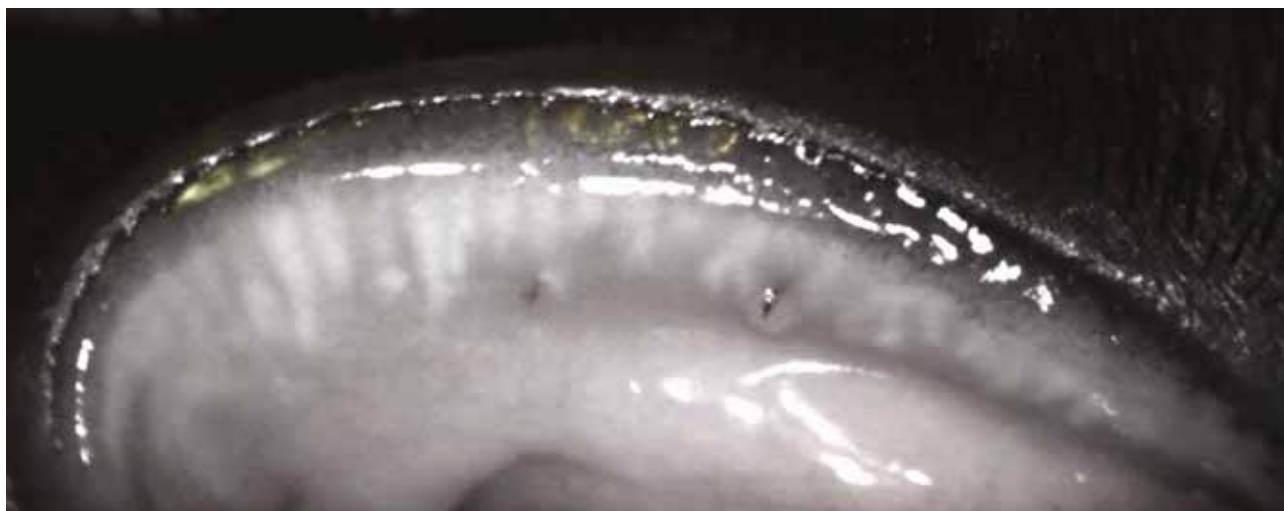ECTOPIC CILIA AND MGS CYSTS WITH MULTIPLE HAIRS



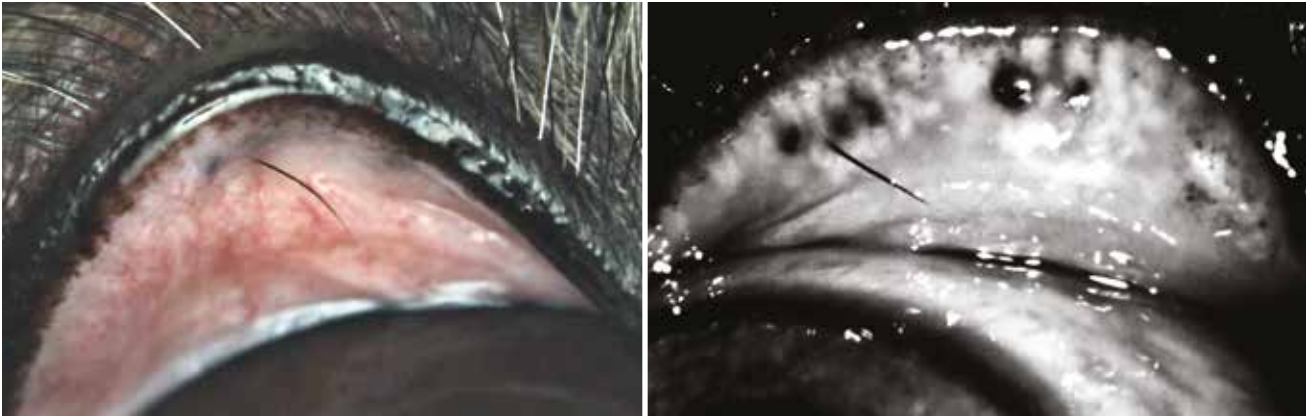
French Bulldog female, 9 months old.

Main clinical signs at presentation: red and wet right eye with blepharospasm and pain.

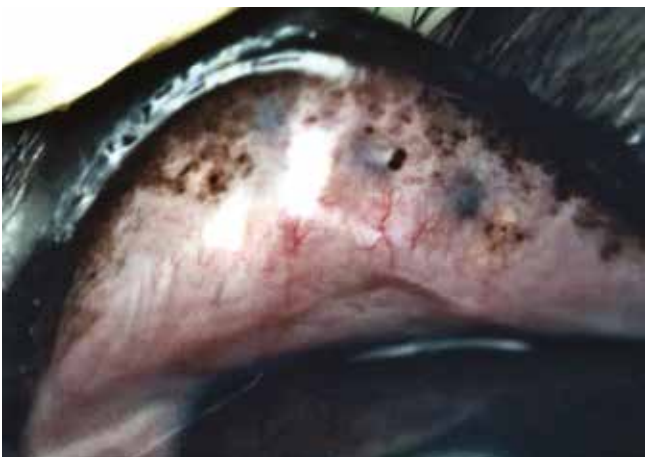Diagnosis: corneal ulcer in the centro-dorsal quadrant at the level of an upper eyelid ectopic cilium.



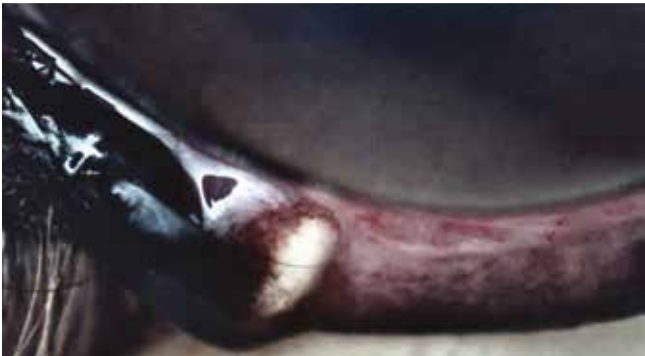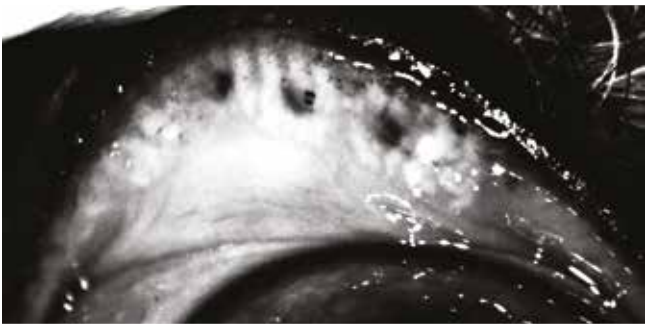
OSA-VET non-contact infrared meibography better shows the presence of the ectopic cilium and allows to notice another ectopic cilium hidden under the conjunctiva.



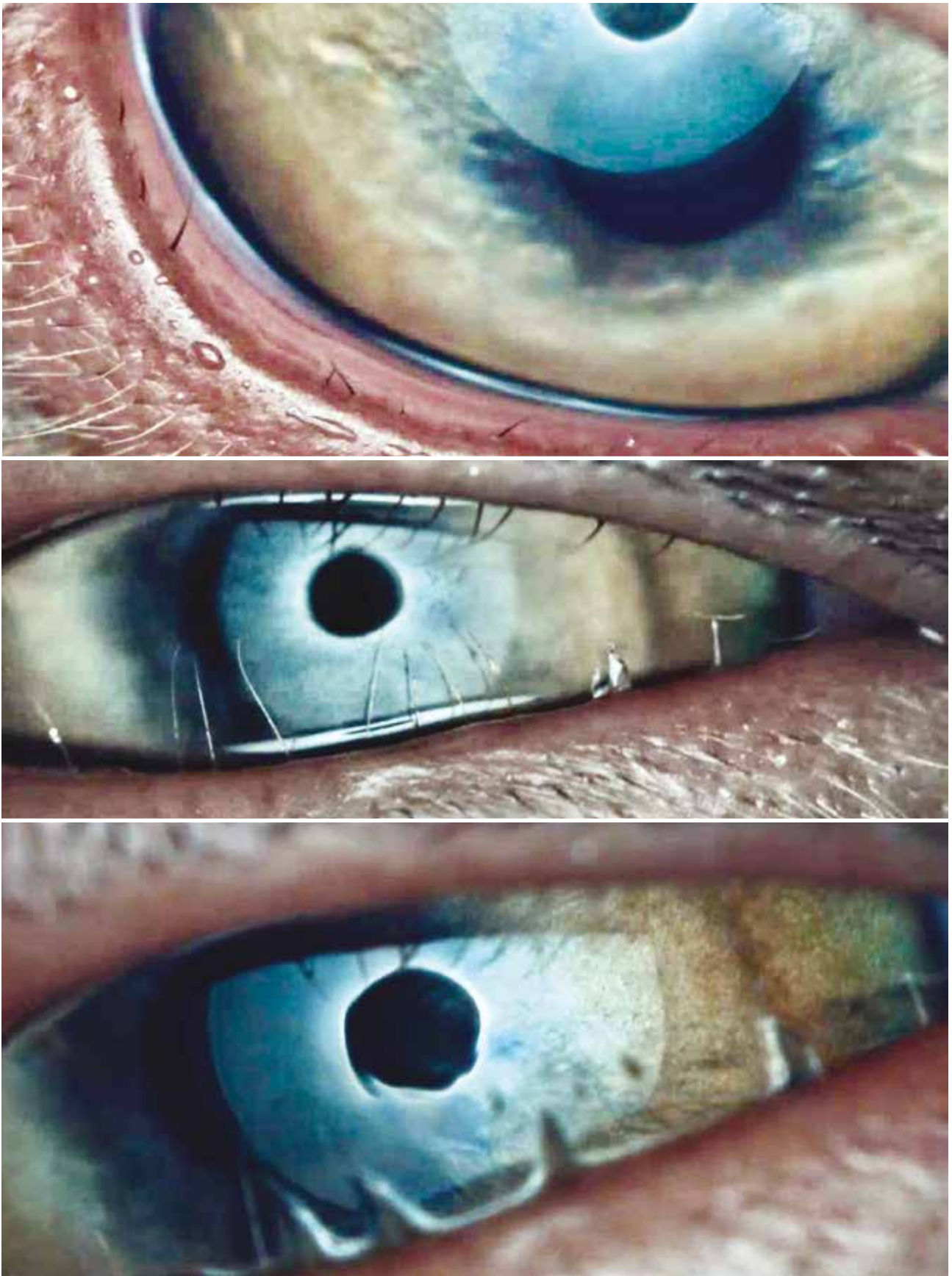
Shih Tzu male, 10 years old, right eye. Main clinical signs at presentation: red, wet, opaque eyes OU. Diagnosis: ectopic cilia, MGs cysts with multiple hairs, MGD, keratitis and corneal ulcers outcome. Multiple hairs are shown as black spots under the conjunctiva. An ectopic cilium is evident, extruded from the MGs cystic dilatation. The infrared image better highlights the details of MGs involvement (OSA-VET shot and meibography).



Left eye of the previous dog. MGs cysts with multiple hairs, lower eyelid chalazion. The infrared image better highlights the details of MGs involvement (OSA-VET shot and meibography).

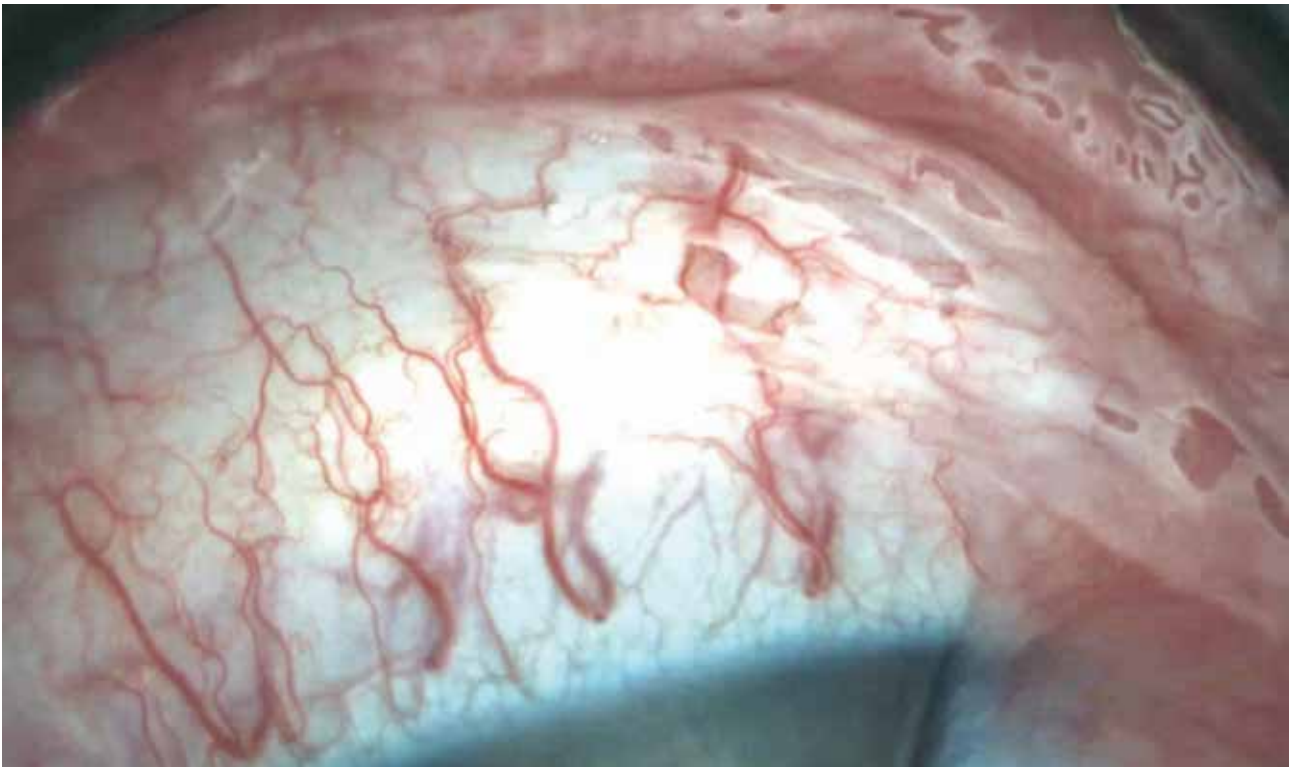

DISTICHIASIS



Pitbull, male, 5 months old. Distichiasis OU, OSA-VET shots from video-interferometry. Tear meniscus is spread along the distichiae at the lower eyelid margin.

CONJUNCTIVAL/EPISCLERAL VESSELS



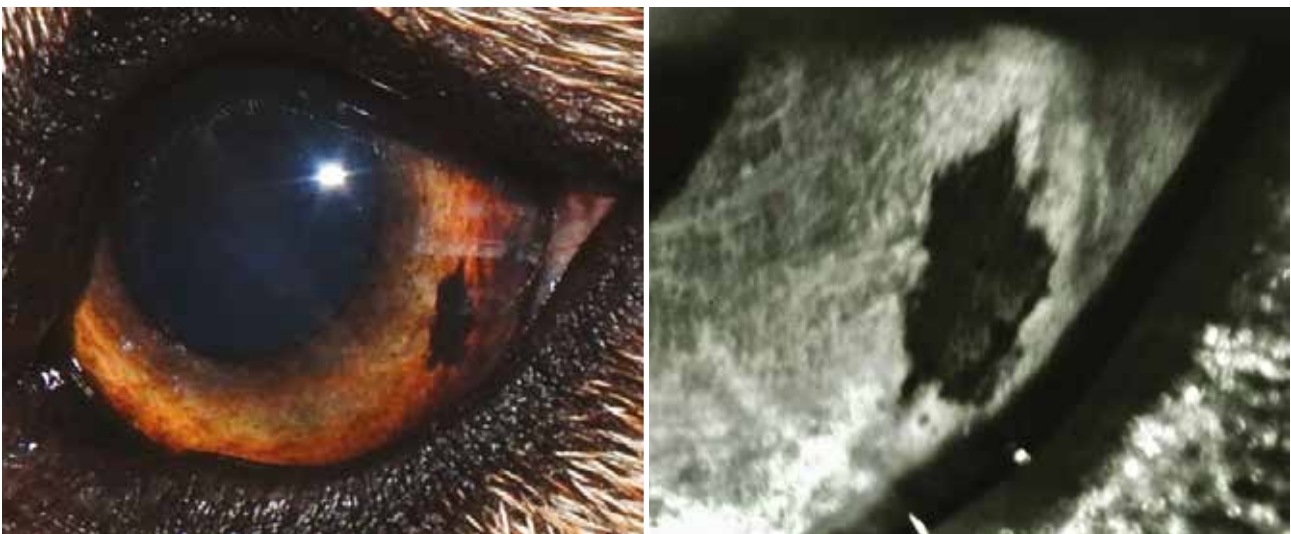Old English Sheepdog female, 8 years old. Main clinical signs at presentation: red, wet eyes OU.

Diagnosis: blepharo-conjunctivitis, MGD.

Conjunctival and episcleral vascularization highlighted with interferometry.

A thin lipidic film is visible (OSA-VET shot).

IRIS PIGMENTED SPOTS



Crossbred female, 16 months old. Main clinical signs at presentation: pigmented spot in the temporal quadrant of the iris. The infrared light used to perform meibography enhances the contrasts to better evaluate the follow up (OSA-VET shot).



www.sbmsistemi.com

Strada Torino, 43 - 10043 Orbassano (Torino) Italy
Tel. +39.011.19923378 - info@sbmsistemi.com