

A review of meibography for a refractive surgeon

Krishna Poojita Vunnava^{1,2}, Naren Shetty¹, Kamal B Kapur²

Refractive surgery has evolved from being a therapeutic correction of high refractive errors to a cosmetic correction. The expectations associated with such a surgery are enormous and one has to anticipate all possible complications and side-effects that come with the procedure and prepare accordingly. The most common amongst these is post-refractive surgery dry eye of which Meibomian gland dysfunction is a commonly associated cause. We present an understanding of various diagnostic imaging modalities that can be used for evaluating meibomian glands which can also serve as a visual aid for patient understanding. We also describe various common conditions which can silently cause changes in the gland architecture and function which are to be considered and evaluated for.

Key words: Dry eye disease, meibography, meibomian gland dysfunction

Access this article online

Website:

www.ijo.in

DOI:

10.4103/ijo.IJO_2465_20

Quick Response Code:



Meibomian gland dysfunction (MGD) is defined as a chronic, diffuse abnormality of the meibomian glands, commonly characterized by terminal duct obstruction and/or qualitative/quantitative changes in the glandular secretion.^[1] Studies done across Asia have reported a prevalence ranging from 46.2-69.3% in population having age > 40 years.^[2,3] In hospital-based studies done in India the prevalence was found to be 31.1% in eastern India and 48.4% in central India.^[4,5] Lin *et al.* observed that 61.7% of those with dry eye had signs of MGD.^[6] Most of the population-based prevalence studies have considered aging population with average age more than 40 years. Den *et al.* reported that the lid margin and Meibomian gland anatomical changes were lesser in those younger than 50 years than those who were more than 50.^[7] Sullivan *et al.* found that the composition of lipids expressed from the meibomian orifices were significantly different in the older and the younger age groups.^[8]

Arita *et al.* postulated that there is a compensatory increase in tear fluid production with a significant difference in Schirmer's test value in MGD group as compared to the non-Sjögren syndrome group.^[9] However laser refractive surgery has been known to induce dryness by various mechanisms.^[10,11] The most widely acknowledged mechanism is the reduction in corneal sensitivity which leads to impaired aqueous layer production through the cornea-lacrimal gland feedback loop system and impaired blinking and reduced meibum expression through the cornea-eye lid reflex loop.^[12-14] Hence it is pertinent to evaluate a patient undergoing refractive surgery (myopic/hyperopic/presbyopic) for various causes of dry eye.

MGD can be evaluated by observing the eyelid changes on slit lamp and by imaging techniques like meibography.^[15-17] We

describe various modalities of imaging of Meibomian glands and their relevance in refractive surgery practice.

Optical Coherence Tomography for Meibography

Optical coherence tomography (OCT) has found profound use in retinal imaging and the development of higher wavelength high-speed Fourier domain OCT systems has resulted in a significant improvement in the evaluation of anterior segment.^[18] Bizheva *et al.* were the earliest to use the OCT system for imaging the meibomian glands. While the Infrared meibography gives the enface view in 2 dimensions, OCT images have been used to generate 3D models for volumetric analysis of the meibomian glands.^[19,20] Various authors have used laser lights of different wavelengths ranging from 1060 nm to 1310 nm to image the glands.^[20-22] Yoo *et al.* used swept-source OCT system with a resolution 8.6 μm to correlate the conclusions drawn from infrared system, clinical features and OCT meibography.^[23] The major drawback of OCT-based meibography is the ability to measure a very small area for a given scan, 4.3 × 4.3 mm by Yoo *et al.* unlike infrared meibography. To overcome this drawback, Liang *et al.* used slit lamp-based OCT system of 1310 nm wavelength laser to perform 4 scans at various cross sections to observe the changes in the length, width, orifice diameter and number of orifices seen of the meibomian glands and the thickness of the conjunctiva.^[21] They also observed that the changes in the meibomian gland architecture in the proximal end of the glands were more associated with clinical signs and symptoms of MGD as against those with more changes away from the

¹Department of Cataract and Refractive Services, Narayana Nethralaya, Bangalore, Karnataka, ²Department of Cataract and Refractive Services, Sharp Sight Eye Center, New Delhi, India

Correspondence to: Dr. Krishna Poojita Vunnava, #503, Madhuban Apartments, Hosur Road, Opposite Adugodi Police Station, Bangalore - 560 030, Karnataka, India. E-mail: vkpoojita@gmail.com

Received: 30-Jul-2020

Revision: 08-Sep-2020

Accepted: 01-Oct-2020

Published: 23-Nov-2020

This is an open access journal, and articles are distributed under the terms of the Creative Commons Attribution-NonCommercial-ShareAlike 4.0 License, which allows others to remix, tweak, and build upon the work non-commercially, as long as appropriate credit is given and the new creations are licensed under the identical terms.

For reprints contact: WKHLRPMedknow_reprints@wolterskluwer.com

Cite this article as: Vunnava KP, Shetty N, Kapur KB. A review of meibography for a refractive surgeon. Indian J Ophthalmol 2020;68:2663-9.

orifice.^[21,24] Knop *et al.* in their description of the meibomian glands, mentioned the lack of evidence to distinguish between actual glandular loss and absence of visualization on infrared meibography due to the indiscernible difference in the optical properties of the glands and the tarsus.^[25] It was seen on OCT studies that the thickness of the palpebral conjunctiva increases significantly in MGD.^[21] The increased scattering and reduced transmission in such cases can also lead false positive gland drop outs seen on infrared meibography. Yoo *et al.* performed OCT at the plane where drop out was noticed on infrared imaging.^[23] They have seen that there is presence of atrophic glands and patent duct in many instances if not all. Hence infrared meibography can be used as a screening tool and OCT meibography can be done to plan the management in those cases where severe drop outs are visible on infrared image.

Confocal Microscopy for Meibography

Confocal microscopy as a method of in-vivo study of cornea and ocular surface has gained tremendous importance [Fig. 1].^[26,27] The machine has evolved from tandem scanning to slit-scanning white light-emitting device to the use of diode laser for acquiring much higher quality of images for evaluating the histological changes.^[28,29] The use of confocal microscopy in dry eye and ocular surface disorders including meibomian gland dysfunction is known and Kobayashi *et al.* were the first to describe the features in healthy volunteers.^[30] Currently, Heidelberg Retina Tomograph II, Rostock Cornea Module (HRT II RCM) (Heidelberg Engineering GmbH, Dossenheim, Germany) has been used on the everted lid after the application of topical anesthesia with the gel used as a coupling agent. The immersion lens is covered with a cap and the focal plane is set into the subconjunctival tissue and a diode laser of 679 nm wavelength is used to image a field of 400 × 400 μm. The evaluation of the entire lid can be a time consuming and tedious process and use of confocal microscopy is recommended to evaluate localized changes. Matsumoto *et al.* evaluated the acinar diameter, acinar density per square millimeter to evaluate the meibomian gland morphology.^[31] The mean acinar density (47.6 ± 26.6/sq. mm) was lower in MGD as compared to the controls (101.3 ± 33.8/sq. mm). The acinar diameter also significantly correlated with the expressibility of the meibum. Higher drop-out ratio was associated with enlarged acinar diameter. They also observed severe peri-glandular fibrosis and atrophy in eyes with poor meibomian expressibility. A French group classified MGD using confocal microscopy based on meibum reflectivity, intraepithelial glandular inflammation, fibrosis.^[32] Randon *et al.* considered the most widespread pattern that is seen on the confocal imaging of the lids to classify into absence of MGD, Obstructive stage, fibrosis stage and found significant correlation of these staging with infrared meibography, meibum expression score, tear osmolarity and Oxford scoring of ocular surface.^[33]

Infrared Meibography

Meibography is a non-invasive *in vivo* examination of the meibomian glands. It uses infrared transmitting filter and a charge-coupled device video camera to capture the image. The Meibomian glands are anatomically arranged in a longitudinally parallel fashion extending across the length and width of the tarsal plate.^[25] The glands have a distal blind end and the proximal end opening anterior to mucocutaneous junction. They appear as hyper-luminescent white bands with the space between them appearing dark. The advantage of this imaging is that it is easy to perform and an entire gross evaluation of the lid can be done at once. Various platforms have used this technology either individually or as a stand-alone infrared device or incorporated into another imaging device.^[34-36] The

image serves as a good tool for documentation and monitoring of the glands with a more visual and lucid reporting making it much easier to explain to the patient [Figs. 2-5]. In addition to subjective interpretation of the image, various objective and analytical grading systems have been developed for infrared meibography.

Objective Grading Systems

There is no single standardized grading or staging system for the diagnosis of MGD on infrared meibography. Normal morphology of the glands is hyper-luminescent structures with the glands linearly traversing through the length and width of the tarsal plate.^[37] Obstructive type of MGD progresses with dilation of the acini and ducts followed by thinning and atrophy.^[25,38] Many studies have been done to objectively analyze the changes and grade the condition [Table 1].

Arita *et al.* proposed classification of eyelids from grade 0 to 3 based on the loss of meibomian glands in each lid.^[39] The sum of the scores obtained for upper and lower lid is the total score of each eye.

Pult *et al.* suggested a 5-step grading system to take into consideration finer increments in detecting meibomian gland loss.^[40] They compared the Meiboscore with their 5-scale system and found a better intra and inter-observer agreement using the 5-scale system. Using Image J software, they also determined the MG loss value by marking the area of presence of glands as a fraction of total area of the lid. They also calculated the bent angle of the worst affected gland as a surrogate marker for tortuosity of the glands seen in obstructive MGD^[41]

Gestalt grading scale using the number of partial meibomian glands present in each lid has also been described.^[42] However as the glands reduce in length and are partial, we feel, this metric would correlate with the amount of dropouts seen which can be measured using the aforementioned classification systems

Meibograde scoring criteria: Call *et al.* considered gland distortion, gland shortening and drop out to scoring the disease severity.^[43]

The Dry Eye Assessment and Management (DREAM) study evaluated and described various morphological features of the meibomian glands using infrared meibography. These include distortion, tortuosity, hooking, overlapping, tadpoling, thickening, thinning, dropouts, ghost glands, fluffy glands.^[44] They found that there was poor agreement between reader in identifying thin and thick glands on observation. Hence an automated assessment and quantification would probably add uniformity.

We did a pilot study in our institute on 50 eyes with and without MGD by imaging the meibomian glands using a hand-held prototype infrared camera with a resolution of 5 Mega Pixel (MP). The device has automatic and manual mode of image acquisition. We used the polygon tool in the image J software to mark a region of interest over the lid which encompasses the total area of the lid that is included in the computation in addition to marking each gland individually. The end-points of each connected component (which belongs to each individual gland) were used to measure the Euclidean distance and various other metrics. Though the process is time-consuming and elaborate we were able to compute various parameters of each glands like the length, width, tortuosity for a finer understanding and study of the morphological changes. We found that the mean number of glands and number of tortuous glands were promising parameters to differentiate in addition to dropouts.

Table 1: Objective grading system using infrared meibography

Arita *et al.*

- Grade 0: No loss of meibomian glands
- Grade 1: area loss was less than one third of the total meibomian gland area
- Grade 2: area loss was between one third and two thirds
- Grade 3: area loss was more than two thirds

Pult *et al.*

- Grade 0: 0% loss of glands
- Grade 1: $\leq 25\%$
- Grade 2: 26-50%
- Grade 3: 51-75%
- Grade 4: $>75\%$

Call *et al.*

- Gland distortion is scored 0-3 based on percentage of width of eyelid demonstrating: 1. Abnormal gland-to-tarsus ratio and/or 2. Tortuous glands and/or 3. Discordant patterning of glands
- Gland shortening is scored 0 through 3 based on percentage of width of eyelid demonstrating glands not extending from the eyelid margin to the opposite edge of the tarsal plate
- Drop out scored 0 through 3 based on the percentage of surface area of eyelid demonstrating the zones of meibomian gland dropout.
- Scores are summed from 0-9 for each lid

Gestalt grading

- Grade 1 (no partial glands)
- Grade 2 (less than 25% of the image contains partial meibomian glands)
- Grade 3 (between 25% and 75% of the image contains partial meibomian glands),
- Grade 4 (more than 75% of the image contains partial meibomian glands)

Objective analysis (In house)

- Number of glands
- Tortuosity of the glands
- Length of the glands
- Width of the glands
- Drop-out ratio

Quintana *et al.* have validated an automated algorithm for objective analysis. The image obtained underwent various modifications like high-frequency noise removal, eroding, binarizing followed by edge detection and active contouring to calculate various parameters.^[45] Another study which performed similar pre and postprocessing of the infrared images using MATLAB software found a sensitivity of 99.3% and specificity of 97.5% in identifying the glands.^[46] Incorporation of such a software into daily practice can change the diagnostic modality that infrared meibography is today.

Relevance of Meibomian Imaging in Refractive Practice

Refractive surgery today has evolved many folds and the popularity has risen due to the precision in outcomes, faster visual rehabilitation, and increased safety.^[47] However, one of the most common causes of sub-optimal patient satisfaction and in turn lower rating of the surgical procedure in the patients perception is postoperative dry eye which can persist for up to 6 months or more in 40-60% of the patients.^[48] Small Incision Lenticule Extraction (SMILE) surgery as well has conflicting reports on the severity and development of the post-operative dry eye.^[49-51] Hence, it is imperative to evaluate for one of the most common causes of dry eye by using any of the imaging techniques described earlier prior to a laser refractive surgery. Various other

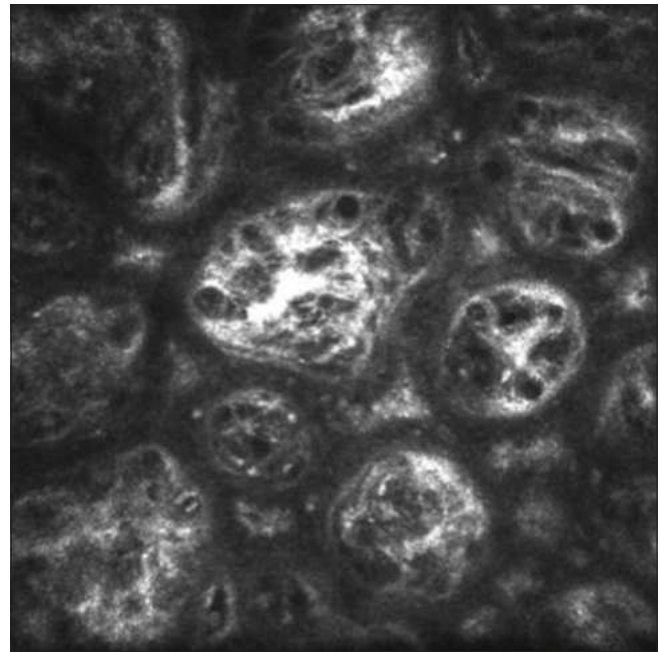


Figure 1: Image from *In vivo* laser confocal microscopy of the meibomian glands (42 μm using Heidelberg Retina Tomograph II-Rostock Cornea Module; Heidelberg Engineering GmbH, Dossenheim, Germany) showing glandular fibrosis

causes can also predispose a patient to develop MGD and these can also be detected using meibomian gland imaging.

Phlyctenular Keratoconjunctivitis

It is a non-infectious inflammatory condition of the cornea due to delayed type of hypersensitivity reaction to an antigen. Most commonly observed antigens are Mycobacterium tuberculosis, Staphylococcal antigen, Propionibacterium acnes in addition to Candida and Chlamydia species.^[52-54] Suzuki *et al.* noted in their study that all eyes with phlyctenular keratitis showed a drop out meiboscore of 2.9 ± 0.3 as against 0.4 ± 0.6 in normal eyes.^[52] They also found that the images were of a lower contrast due to possible conjunctival inflammation and edema. Meibomitis secondary to obstructive MGD could trigger marginal keratitis or phlyctenular keratitis or meibomitis due to the presence of bacteria and their toxins. There could also be secondary meibomian gland inflammation due to the conjunctival inflammation induced by Phlyctenular keratoconjunctivitis.

Conjunctivitis

Distortion of meibomian glands has been reported in 8% of healthy asymptomatic individuals.^[55] However, distortion to a greater extent has been noted with allergic, atopic and vernal conjunctivitis.^[56-58] Follicular conjunctival inflammation developing secondary to bacterial colonization and subsequently leading to MGD has been observed.^[59] Although there has been no study done on the pathophysiology of these changes, some have proposed that the constant eye rubbing associated with allergic conjunctivitis causes mechanical stress on the tarsal plate leading to the distortion.^[57] It has also been shown that chronic inflammation and even inactive form of trachoma of the conjunctiva can be associated with destruction of the glands and inflammatory changes and atrophy of the acini with reduction in lipid layer however we do not know if the inflammatory mediators and chlamydia in the conjunctiva, penetrate the tarsal plate.^[60,61]

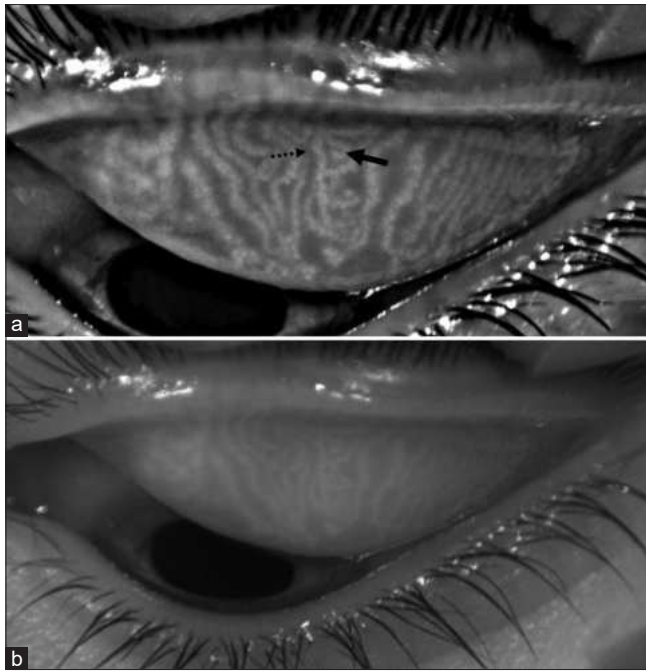


Figure 2: Contrast enhanced (a) and regular (b) image of upper lid taken on Oculus Keratograph® 4 (Oculus Optikgerate GmbH, Germany). Bold arrow denoting increased tortuosity of the glands, dotted arrow showing the thinning noted in some glands

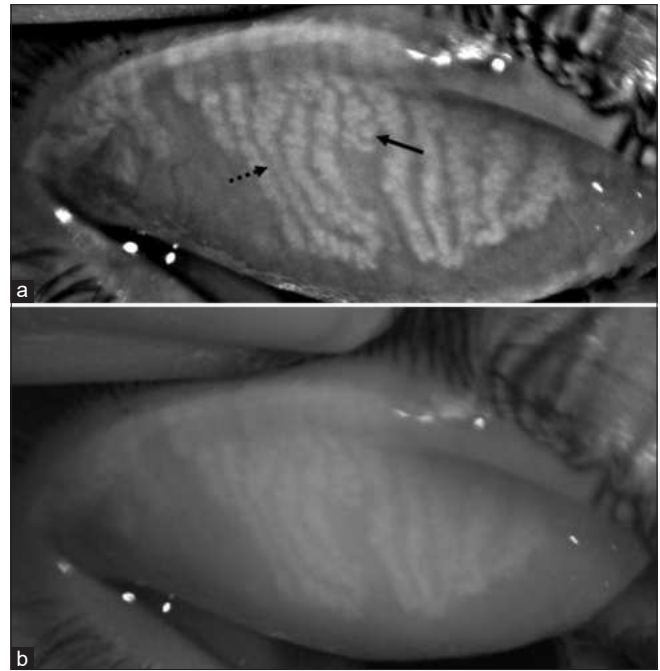


Figure 3: Contrast enhanced (a) and regular (b) image of upper lid taken on Oculus Keratograph® 4 (Oculus Optikgerate GmbH, Germany) Bold arrow showing a dilated gland noted by increased width at that cross section. Dotted arrow denoting thinning

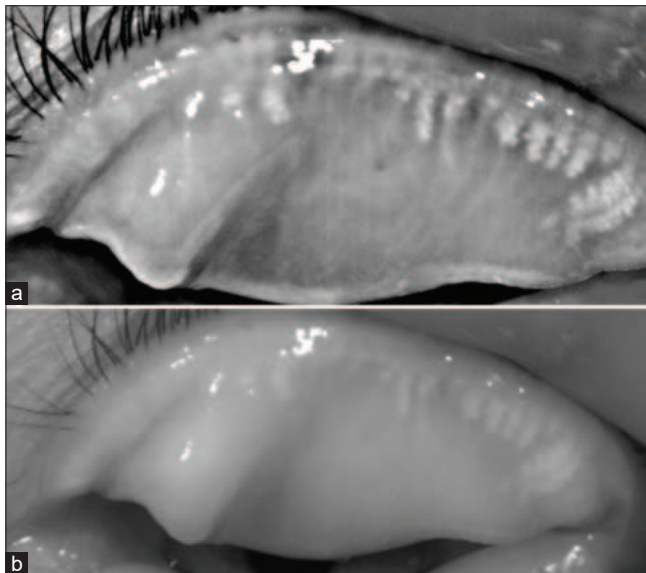


Figure 4: Contrast enhanced (a) and regular (b) image of upper lid taken on Oculus Keratograph® 4 (Oculus Optikgerate GmbH, Germany) Showing huge drop outs. Such a picture is commonly seen in long term contact lens users

Contact Lens Use

It is a common observation amongst refractive surgeons that most of the extensive contact lens users, after getting a refractive surgery, require some form of prolonged management for the symptoms of dry eye. Contact lens use has been known to be associated with dry eye disease.^[62] Mechanical irritation induced inflammation and associated giant papillary conjunctivitis have been established as the possible causes of MGD in the past.^[63] Increased blockage of meibomian orifices

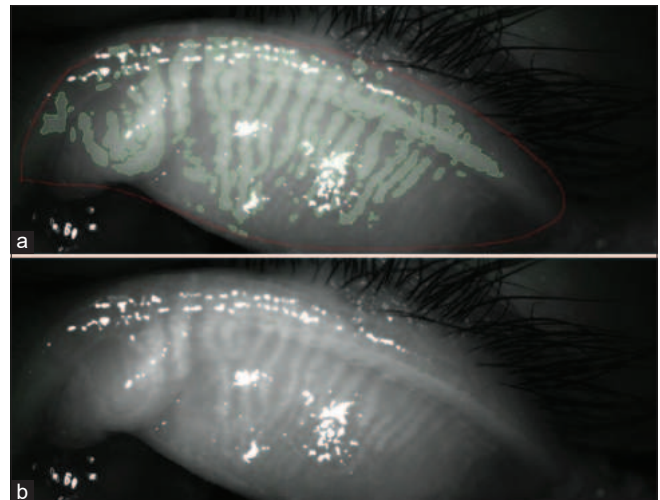


Figure 5: Image of a report generated from SBM Sistemi Idras Dry Eye Analyzer (Torino, Italy). It shows an automated gland recognition and segmentation done to calculate the drop out percentage for a more objective assessment. Note that the software can miss detecting the glands if the positioning is incorrect while taking an image

has been noted in contact lens wearers leading to obstructive MGD however there have been conflicting observations as well.^[64,65] The proposed explanation is the aggregation of desquamated epithelial cells at the orifices.^[64,66] Arita *et al.* in their study on 121 eyes with long term (≥ 3 years) use of Rigid Gas Permeable (RGP) and hydrogel contact lens, noted shortened clusters of meibomian glands.^[67] This shortening was less than half of that seen in controls and progressed from the distal end of the glands. They concluded that contact lens use accelerates age-related changes in the meibomian glands and was directly proportional to the duration of use. Studies

on confocal microscopy of the meibomian glands of contact lens users showed significantly decreased basal epithelial cell density, lower acinar unity diameters, higher glandular orifice diameter.^[68] The non-obvious variety of MGD which has a lid margin that appears normal on slit lamp, is known to get precipitated with prolonged use of contact lens and the patient may become symptomatic after a refractive surgery.^[64,69,70]

Drug Induced Ocular Surface Changes

Topical Anti Glaucoma Medications (AGM) have been shown to induce ocular surface changes.^[71,72] Some studies have shown that the majority of patients using prostaglandin analogs for glaucoma showed features of obstructive MGD with blocked orifices and gland drop outs while some others have seen no significant difference between groups.^[73,74] However, they found that the meiboscore was higher in those on AGMs than the controls. With the mechanism of action unknown, we are not yet sure if there are any structural changes induced in the meibomian glands by AGMs and their preservatives. Use of isotretinoin for severe acne has gained popularity. There is also the presence of various proportions of retinoic acid in many anti-aging skin creams available over-the-counter. Retinoic acid gets converted to all-trans retinoic acid and acts on the sebaceous glands of the skin to reduce the lipid production and induce atrophy of the glands.^[75-77] They thus have a similar extended effect on the meibomian glands which are the sebaceous glands located in the tarsal plate. Androgen deficiency and use of anti-androgen medications have been associated with altered neutral lipid profile in secretions, metaplasia and keratinization of duct orifices and MGD. Estrogen treatment has been shown to reduce lipid synthesis and contribute to MGD.^[25]

Sleep Apnea

Sleep apnea is a disorder characterized by decreased oxygen saturation with recurrent apnea-hypopnea episodes.^[78] It is also associated with floppy eyelid syndrome and ocular surface changes.^[79,80] Karaca *et al.* observed that morphological changes like thinning, distortion and dilatation of the glands are seen in severe obstructive sleep apnea syndrome.^[81] The prone position during sleep and nocturnal eversion leading to mechanical rubbing of the lids, loss of elastin fibers in the stroma of the tarsal plate may all contribute towards these changes.^[81,82]

Management

In its review of literature in the report of tear film and Ocular surface (TFOS) Dry eye workshop (DEWS II) the group noted that there are no large studies comparing the lab based objective analytical methods to subjective morphological changes in the lid and those noted on meibography at the same time point. There is also no conclusive consensus on the timeline of appearance of symptoms in the progression of MGD.^[83] Nonobvious form of MGD has been shown to be symptomatically normal with higher structural changes and higher dropouts. This has been attributed to a probable compensatory increase in tear production or increased secretion from existing Meibomian glands or the location of loss of glands.^[84] Hence lack of investigation and documentation prior to a surgery due to the absence of symptoms could prove perilous. DREAM study noted that the presence of a large number of ghost glands was associated with thickened secretions and plugging was correlating with dropouts. Various medical and procedural modalities of management of MGD are available. Use of warm compresses and lid massages at home have been followed traditionally. Vector thermal pulsation

therapy, Intensive pulsed light therapy, thermal stimulation are various newer modalities. Delving into the details of which is beyond the scope of this article.

Starr *et al.* have described an algorithmic approach for the treatment of ocular surface disorders encompassing MGD and others prior to a cataract-refractive surgery.^[85] They recommend that if the impact of the disorder is severe enough to induce variability in topography, biometry or aberrometry then it is prudent to postpone the procedure till the ocular surface is stable. Staged management given by DEWS II is a step-wise slow ramp approach to treatment.^[86] Since a refractive surgery can add to a pre-existing dry eye, one can step up to procedural or more intensive management prior to going ahead with surgery and shift to preservative free topical medications in the post-op care.

Conclusion

1. The practice of refractive surgery is a highly demanding and the occurrence of dry eye after the surgery is one of the common causes for patient dissatisfaction
2. The methods of evaluating MGD are either objective or subjective. Objective methods include the biochemical analysis of the expressed Meibum, evaporimetry and interferometry. Subjective methods are more widely used and include slit-lamp examination and meibography
3. Meibography is a simple tool for studying the meibomian glands and can come in handy for recognizing any preexisting MGD. With the advent of automated in-vivo analytical tools and metrics this easy-to-use system can be made more objective
4. Non-obvious MGD has been shown to be associated with significant MG loss and structural changes. Presence of shortened glands, dropouts, ghosting, tortuosity indicate an ongoing process of MGD which can present with exaggerated dry eye symptoms postrefractive surgery even if the patient is asymptomatic on presentation
5. In presence of these findings, it would be wiser to explain the need for need for immediate pre-surgical intensive procedural or medical treatment and longer follow-ups for managing the condition
6. Various common ocular surface conditions as mentioned in the text above, cause structural and functional changes to the meibomian glands
7. Use of contact lens is very common in patients undergoing refractive surgery. If the morphological changes in the glands are not evaluated and documented prior to surgery, the patient acceptance of the condition aftermath can be questionable
8. History of use of various medications (systemic and local) which impact the ocular surface should be taken and impact on the structures should be noted
9. History of hormonal/dermatologic/systemic ailments which are known to affect the meibomian gland function need to be elicited prior to any surgical procedure especial corneal refractive procedure
10. MGD and other ocular surface disorders which impact the vision (fluctuations) and surgical imaging warrant a more aggressive treatment and adequate patient counselling
11. Use of face masks due to the pandemic of COVID-19 virus has been postulated to be associated with ocular surface irritation and dryness caused due to the expired air from the upper edge of the face-mask. Since the existence of a face

mask will be a norm for a long time to come, one should keep this aspect in mind while evaluating these patients.^{187]}

Financial support and sponsorship

Nil.

Conflicts of interest

There are no conflicts of interest.

References

- Nelson JD, Shimazaki J, Benitez-del-Castillo JM, Craig JP, McCulley JP, Den S, *et al*. The international workshop on meibomian gland dysfunction: Report of the definition and classification subcommittee. *Invest Ophthalmol Vis Sci* 2011;52:1930-7.
- Lekhanont K, Rojanaporn D, Chuck RS, Vongthongsri A. Prevalence of dry eye in Bangkok, Thailand. *Cornea* 2006;25:1162-7.
- Jie Y, Xu L, Wu YY, Jonas JB. Prevalence of dry eye among adult Chinese in the Beijing Eye Study. *Eye (Lond)* 2009;23:688-93.
- Basak SK, Pal PP, Basak S, Bandyopadhyay A, Choudhury S, Sar S. Prevalence of dry eye diseases in hospital-based population in West Bengal, Eastern India. *J Indian Med Assoc* 2012;110:789-94.
- Chatterjee S, Agrawal D, Sharma A. Meibomian gland dysfunction in a hospital-based population in central India. *Cornea* 2020;39:634-9.
- Lin PY, Tsai SY, Cheng CY, Liu JH, Chou P, Hsu WM. Prevalence of dry eye among an elderly Chinese population in Taiwan: The Shihpai Eye Study. *Ophthalmology* 2003;110:1096-101.
- Den S, Shimizu K, Ikeda T, Tsubota K, Shimmura S, Shimazaki J. Association between meibomian gland changes and aging, sex, or tear function. *Cornea* 2006;25:651-5.
- Sullivan BD, Evans JE, Dana MR, Sullivan DA. Influence of aging on the polar and neutral lipid profiles in human meibomian gland secretions. *Arch Ophthalmol* 2006;124:1286-92.
- Arita R, Morishige N, Koh S, Shirakawa R, Kawashima M, Sakimoto T, *et al*. Increased tear fluid production as a compensatory response to meibomian gland loss: A multicenter cross-sectional study. *Ophthalmology* 2015;122:925-33.
- Toda I. Dry eye after LASIK. *Invest Ophthalmol Vis Sci* 2018;59:DES109-15.
- Cohen E, Spierer O. Dry Eye Post-laser-assisted *in situ* keratomileusis: Major review and latest updates. *J Ophthalmol* 2018;2018:4903831.
- Di Pascuale MA, Liu TS, Trattler W, Tseng SC. Lipid tear deficiency in persistent dry eye after laser *in situ* keratomileusis and treatment results of new eye-warming device. *J Cataract Refract Surg* 2005;31:1741-9.
- Battat L, Macri A, Dursun D, Pflugfelder SC. Effects of laser *in situ* keratomileusis on tear production, clearance, and the ocular surface. *Ophthalmology* 2001;108:1230-5.
- Lee BH, McLaren JW, Erie JC, Hodge DO, Bourne WM. Reinnervation in the cornea after LASIK. *Invest Ophthalmol Vis Sci* 2002;43:3660-4.
- Pult H, Nichols JJ. A review of meibography. *Optom Vis Sci* 2012;89:E760-9.
- Wise RJ, Sobel RK, Allen RC. Meibography: A review of techniques and technologies. *Saudi J Ophthalmol* 2012;26:349-56.
- Arita R, Itoh K, Maeda S, Maeda K, Furuta A, Fukuoka S, *et al*. Proposed diagnostic criteria for obstructive meibomian gland dysfunction. *Ophthalmology* 2009;116:2058-63.e1.
- Huang D, Swanson EA, Lin CP, Schuman JS, Stinson WG, Chang W, *et al*. Optical coherence tomography. *Science* 1991;254:1178-81.
- Hwang HS, Shin JG, Lee BH, Eom TJ, Joo CK. *In Vivo* 3D meibography of the human eyelid using real time imaging fourier-domain OCT. *PLoS One* 2013;8:e67143.
- Bizheva K, Lee P, Sorbara L, Hutchings N, Simpson T. *In vivo* volumetric imaging of the human upper eyelid with ultrahigh-resolution optical coherence tomography. *J Biomed Optics* 2010;15:040508.
- Liang Q, Pan Z, Zhou M, Zhang Y, Wang N, Li B, *et al*. Evaluation of optical coherence tomography meibography in patients with obstructive meibomian gland dysfunction. *Cornea* 2015;34:1193-9.
- Hwang HS, Park CW, Joo CK. Novel noncontact meibography with anterior segment optical coherence tomography: Hosik meibography. *Cornea* 2013;32:40-3.
- Yoo YS, Na KS, Byun YS, Shin JG, Lee BH, Yoon G, *et al*. Examination of gland dropout detected on infrared meibography by using optical coherence tomography meibography. *Ocul Surf* 2017;15:130-8.e1.
- Tomlinson A, Bron AJ, Korb DR, Amano S, Paugh JR, Pearce EI, *et al*. The international workshop on meibomian gland dysfunction: Report of the diagnosis subcommittee. *Invest Ophthalmol Vis Sci* 2011;52:2006-49.
- Knop E, Knop N, Millar T, Obata H, Sullivan DA. The international workshop on meibomian gland dysfunction: Report of the subcommittee on anatomy, physiology, and pathophysiology of the meibomian gland. *Invest Ophthalmol Vis Sci* 2011;52:1938-78.
- Messmer EM, Mackert MJ, Zapp DM, Kampik A. *In vivo* confocal microscopy of normal conjunctiva and conjunctivitis. *Cornea* 2006;25:781-8.
- Zhivov A, Stachs O, Kraak R, Stave J, Guthoff RF. *In vivo* confocal microscopy of the ocular surface. *Ocul Surf* 2006;4:81-93.
- Petran M, Hadravsky M. Tandem scanning microscope--a new tool for three-dimensional microanatomy. *Prog Clin Biol Res* 1989;295:551-8.
- Masters BR, Thae AA. *In vivo* human corneal confocal microscopy of identical fields of subepithelial nerve plexus, basal epithelial, and wing cells at different times. *Microsc Res Tech* 1994;29:350-6.
- Kobayashi A, Yoshita T, Sugiyama K. *In vivo* findings of the bulbar/palpebral conjunctiva and presumed meibomian glands by laser scanning confocal microscopy. *Cornea* 2005;24:985-8.
- Matsumoto Y, Ibrahim OMA. Application of *In vivo* confocal microscopy in dry eye disease. *Invest Ophthalmol Vis Sci* 2018;59:DES41-47.
- Randon M, Aragno V, Abbas R, Liang H, Labbe A, Baudouin C. *In vivo* confocal microscopy classification in the diagnosis of meibomian gland dysfunction. *Eye (Lond)* 2019;33:754-60.
- Randon M, Liang H, Abbas R, Mische S, Denoyer A, Baudouin C, *et al*. [A new classification for meibomian gland diseases with *in vivo* confocal microscopy]. *J Fr Ophthalmol* 2016;39:239-47.
- Abdelfattah NS, Dastiridou A, Sadda SR, Lee OL. Noninvasive imaging of tear film dynamics in eyes with ocular surface disease. *Cornea* 2015;34(Suppl 10):S48-52.
- Shehzad D, Gorcuyeva S, Dag T, Bozkurt B. Novel application software for the semi-automated analysis of infrared meibography images. *Cornea* 2019;38:1456-64.
- Arita R. Validity of noninvasive meibography systems: Noncontact meibography equipped with a slit-lamp and a mobile pen-shaped meibograph. *Cornea* 2013;32(Suppl 1):S65-70.
- Jester JV, Rife L, Nii D, Luttrull JK, Wilson L, Smith RE. *In vivo* biomicroscopy and photography of meibomian glands in a rabbit model of meibomian gland dysfunction. *Invest Ophthalmol Vis Sci* 1982;22:660-7.
- Bron AJ, de Paiva CS, Chauhan SK, Bonini S, Gabison EE, Jain S, *et al*. TFOS DEWS II pathophysiology report. *Ocul Surf* 2017;15:438-510.
- Arita R, Itoh K, Inoue K, Amano S. Noncontact infrared meibography to document age-related changes of the meibomian glands in a normal population. *Ophthalmology* 2008;115:911-5.
- Pult H, Riede-Pult B. Comparison of subjective grading and objective assessment in meibography. *Cont Lens Anterior Eye* 2013;36:22-7.
- Pult H, Riede-Pult BH, Nichols JJ. Relation between upper and lower lids' meibomian gland morphology, tear film, and dry eye. *Optom Vis Sci* 2012;89:E310-5.
- Nichols JJ, Berntsen DA, Mitchell GL, Nichols KK. An assessment of grading scales for meibography images. *Cornea* 2005;24:382-8.
- Call CB, Wise RJ, Hansen MR, Carter KD, Allen RC. *In vivo* examination of meibomian gland morphology in patients with facial nerve palsy using infrared meibography. *Ophthalmic Plast Reconstr Surg* 2012;28:396-400.
- Daniel E, Maguire MG, Pistilli M, Bunya VY, Massaro-Giordano GM,

- Smith E, *et al.* Grading and baseline characteristics of meibomian glands in meibography images and their clinical associations in the Dry Eye Assessment and Management (DREAM) study. *Ocul Surf* 2019;17:491-501.
45. Llorens-Quintana C, Rico-Del-Viejo L, Syga P, Madrid-Costa D, Iskander DR. A novel automated approach for infrared-based assessment of meibomian gland morphology. *Transl Vis Sci Technol* 2019;8:17.
46. Koprowski R, Wilczynski S, Olczyk P, Nowinska A, Weglarz B, Wylegala E. A quantitative method for assessing the quality of meibomian glands. *Comput Biol Med* 2016;75:130-8.
47. Sandoval HP, Donnenfeld ED, Kohlen T, Lindstrom RL, Potvin R, Tremblay DM, *et al.* Modern laser *in situ* keratomileusis outcomes. *J Cataract Refract Surg* 2016;42:1224-34.
48. De Paiva CS, Chen Z, Koch DD, Hamill MB, Manuel FK, Hassan SS, *et al.* The incidence and risk factors for developing dry eye after myopic LASIK. *Am J Ophthalmol* 2006;141:438-45.
49. Li M, Zhao J, Shen Y, Li T, He L, Xu H, *et al.* Comparison of dry eye and corneal sensitivity between small incision lenticule extraction and femtosecond LASIK for myopia. *PLoS One* 2013;8:e77797.
50. Xu Y and Yang Y. Dry eye after small incision lenticule extraction and LASIK for myopia. *J Refract Surg* 2014;30:186-90.
51. Zhang H, Wang Y. Dry eye evaluation and correlation analysis between tear film stability and corneal surface regularity after small incision lenticule extraction. *Int Ophthalmol* 2018;38:2283-8.
52. Suzuki T, Morishige N, Arita R, Koh S, Sakimoto T, Shirakawa R, *et al.* Morphological changes in the meibomian glands of patients with phlyctenular keratitis: A multicenter cross-sectional study. *BMC Ophthalmol* 2016;16:178.
53. Sorsby A. The aetiology of phlyctenular ophthalmia. *Br J Ophthalmol* 1942;26:189-215.
54. Thygeson P. The etiology and treatment of phlyctenular keratoconjunctivitis. *Am J Ophthalmol* 1951;34:1217-36.
55. Shimazaki J, Goto E, Ono M, Shimmura S, Tsubota K. Meibomian gland dysfunction in patients with Sjogren syndrome. *Ophthalmology* 1998;105:1485-8.
56. Ibrahim OM, Matsumoto Y, Dogru M, Adan ES, Wakamatsu TH, Shimazaki J, *et al.* *In vivo* confocal microscopy evaluation of meibomian gland dysfunction in atopic-keratoconjunctivitis patients. *Ophthalmology* 2012;119:1961-8.
57. Arita R, Itoh K, Maeda S, Maeda K, Furuta A, Tomidokoro A, *et al.* Meibomian gland duct distortion in patients with perennial allergic conjunctivitis. *Cornea* 2010;29:858-60.
58. Wei Q, Le Q, Hong J, Xiang J, Wei A, Xu J. *In vivo* confocal microscopy of meibomian glands and palpebral conjunctiva in vernal keratoconjunctivitis. *Indian J Ophthalmol* 2015;63:327-30.
59. Rynerson JM, Perry HD. DEBS-a unification theory for dry eye and blepharitis. *Clin Ophthalmol* 2016;10:2455-67.
60. al-Rajhi AA, Hidayat A, Nasr A, al-Faran M. The histopathology and the mechanism of entropion in patients with trachoma. *Ophthalmology* 1993;100:1293-6.
61. Guzey M, Ozardali I, Basar E, Aslan G, Satici A, Karadede S. A survey of trachoma: The histopathology and the mechanism of progressive cicatrization of eyelid tissues. *Ophthalmologica* 2000;214:277-84.
62. Nichols JJ, Mitchell GL, Nichols KK, Chalmers R, Begley C. The performance of the contact lens dry eye questionnaire as a screening survey for contact lens-related dry eye. *Cornea* 2002;21:469-75.
63. Mathers WD, Billborough M. Meibomian gland function and giant papillary conjunctivitis. *Am J Ophthalmol* 1992;114:188-92.
64. Henriquez AS, Korb DR. Meibomian glands and contact lens wear. *Br J Ophthalmol* 1981;65:108-11.
65. Ong BL. Relation between contact lens wear and Meibomian gland dysfunction. *Optom Vis Sci* 1996;73:208-10.
66. Korb DR, Henriquez AS. Meibomian gland dysfunction and contact lens intolerance. *J Am Optom Assoc* 1980;51:243-51.
67. Arita R, Itoh K, Inoue K, Kuchiba A, Yamaguchi T, Amano S. Contact lens wear is associated with decrease of meibomian glands. *Ophthalmology* 2009;116:379-84.
68. Villani E, Ceresara G, Beretta S, Magnani F, Viola F, Ratiglia R. *In vivo* confocal microscopy of meibomian glands in contact lens wearers. *Invest Ophthalmol Vis Sci* 2011;52:5215-9.
69. Ong BL, Hodson SA, Wigham T, Miller F, Larke JR. Evidence for keratin proteins in normal and abnormal human meibomian fluids. *Curr Eye Res* 1991;10:1113-9.
70. Blackie CA, Korb DR, Knop E, Bedi R, Knop N, Holland EJ. Nonobvious obstructive meibomian gland dysfunction. *Cornea* 2010;29:1333-45.
71. Herreras JM, Pastor JC, Calonge M, Asensio VM. Ocular surface alteration after long-term treatment with an antiglaucomatous drug. *Ophthalmology* 1992;99:1082-8.
72. Kuppens EV, Stolwijk TR, de Keizer RJ, van Best JA. Basal tear turnover and topical timolol in glaucoma patients and healthy controls by fluorophotometry. *Invest Ophthalmol Vis Sci* 1992;33:3442-8.
73. Mocan MC, Uzunosmanoglu E, Kocabeyoglu S, Karakaya J, Irkec M. The association of chronic topical prostaglandin analog use with meibomian gland dysfunction. *J Glaucoma* 2016;25:770-4.
74. Arita R, Itoh K, Maeda S, Maeda K, Furuta A, Tomidokoro A, *et al.* Comparison of the long-term effects of various topical antiglaucoma medications on meibomian glands. *Cornea* 2012;31:1229-34.
75. Ding J, Kam WR, Dieckow J, Sullivan DA. The influence of 13-cis retinoic acid on human meibomian gland epithelial cells. *Invest Ophthalmol Vis Sci* 2013;54:4341-50.
76. Nelson AM, Gilliland KL, Cong Z, Thiboutot DM. 13-cis Retinoic acid induces apoptosis and cell cycle arrest in human SEB-1 sebocytes. *J Invest Dermatol* 2006;126:2178-89.
77. Zouboulis CC. Isotretinoin revisited: Pluripotent effects on human sebaceous gland cells. *J Invest Dermatol* 2006;126:2154-6.
78. Li Z, Celestin J, Lockey RF. Pediatric sleep apnea syndrome: An update. *J Allergy Clin Immunol Pract* 2016;4:852-61.
79. Hayirci E, Yagci A, Palamar M, Basoglu OK, Veral A. The effect of continuous positive airway pressure treatment for obstructive sleep apnea syndrome on the ocular surface. *Cornea* 2012;31:604-8.
80. Woog JJ. Obstructive sleep apnea and the floppy eyelid syndrome. *Am J Ophthalmol* 1990;110:314-5.
81. Karaca I, Yagci A, Palamar M, Tasbakan MS, Basoglu OK. Ocular surface assessment and morphological alterations in meibomian glands with meibography in obstructive sleep apnea Syndrome. *Ocul Surf* 2019;17:771-6.
82. Schlotzer-Schrehardt U, Stojkovic M, Hofmann-Rummelt C, Cursiefen C, Kruse FE, Holbach LM. The pathogenesis of floppy eyelid syndrome: Involvement of matrix metalloproteinases in elastic fiber degradation. *Ophthalmology* 2005;112:694-704.
83. Schaumberg DA, Nichols JJ, Papas EB, Tong L, Uchino M, Nichols KK. The international workshop on meibomian gland dysfunction: Report of the subcommittee on the epidemiology of, and associated risk factors for, MGD. *Invest Ophthalmol Vis Sci* 2011;52:1994-2005.
84. Xiao J, Adil MY, Chen X, Utheim OA, Raeder S, Tonseth KA, *et al.* Functional and morphological evaluation of meibomian glands in the assessment of meibomian gland dysfunction subtype and severity. *Am J Ophthalmol* 2020;209:160-7.
85. Starr CE, Gupta PK, Farid M, Beckman KA, Chan CC, Yeu E, *et al.* An algorithm for the preoperative diagnosis and treatment of ocular surface disorders. *J Cataract Refract Surg* 2019;45:669-84.
86. Craig JP, Nelson JD, Azar DT, Belmonte C, Bron AJ, Chauhan SK, *et al.* TFOS DEWS II report executive summary. *Ocul Surf* 2017;15:802-12.
87. Moshirfar M, West WB, Jr., Marx DP. Face mask-associated ocular irritation and dryness. *Ophthalmol Ther* 2020;9:397-400.